

An HIV-1 Infected Patient with Neurofibromatosis Type 1: A Case Report.

Type of Article: Case Report

¹Samson Ejiji Isa, ²Akindele Silas, ¹Comfort Daniyam, ¹Mike Iroezindu, ³Ajuma Agaba, ¹Oche Agbaji

¹Department of Medicine, ²Department of Pathology and ³Department of Family Medicine
Jos University Teaching Hospital, Jos, Nigeria

ABSTRACT

Background: Although HIV-1 infection predisposes an individual to well defined neoplasia, neurofibromas have not been reported as some of the typical ones. The association between HIV-1 infection and neurofibromatosis type 1, a genetic disorder, should be of interest because HIV infection could alter the natural biology of its cutaneous manifestations. However, reports on simultaneous occurrence of these conditions in an individual are rare.

Method: The case records of a 30 year old HIV 1 positive female receiving care at the Jos University teaching hospital centre and a review of the relevant literature was utilised.

Result: We present a 30 year old HIV positive woman with florid cutaneous lesions of familial neurofibromatosis type 1 who had adequate response to antiretroviral therapy

Conclusion: HIV infection and treatment did not seem to affect the clinico- pathological features of the neurofibromatosis lesions.

Key Words: Neurofibromatosis type 1, HIV Infection, cutaneous lesions, HAART

Correspondence: Dr S Ejiji Isa.

INTRODUCTION

Neurofibromatosis type 1 (NF 1) or Von Recklinghausen's disease is a neurocutaneous disorder that mainly affects the skin and peripheral nervous system and causes characteristic bony dysplasia. It has a birth incidence of one in 2500 to 3000 and a prevalence of one in 4000 to 5000 in the UK.¹ Although NF 1 is not uncommon in sub-Saharan Africa,^{2,3} literature on NF 1 co-existing with HIV infection are rare.

The gene for NF1 is cloned on chromosome 17q11.2 and encodes a protein called neurofibromin which has a role in tumour suppression. Neurofibromin reduces cell proliferation by accelerating the inactivation of a cellular proto-oncogene, p21 ras, which is important in promoting tumour formation.⁴ Inactivation of the gene through mutation or allelic loss leads to loss of function and subsequent development of many different types of tumours seen in the disease. NF 1 is largely a benign

condition but can be complicated by plexiform neurofibroma, pseudoarthrosis, epilepsy, spinal neurofibromas, aqueductal stenosis, visceral neurofibromas and haematological malignancies.⁵

Many HIV-associated tumours affect sites that are in contact with the outside environment, including the skin. The increased density of immune cells and coincident elevated concentration of HIV-1 at these sites could lead to local compromised immune defences and the subsequent development of neoplasms.^{6,7} Although it is unclear if HIV-1 acts directly as an oncogenic agent, it may contribute to the development of neoplasms through several mechanisms. Predisposition to infection by oncogenic viruses, impaired immune surveillance, dysregulation of cytokine pathways and growth factor production, chronic B cell stimulation, and imbalance between cellular proliferation and differentiation may all contribute to the development of HIV/AIDS-associated neoplasia.^{6,8,9}

Hence, it is plausible that increased risk for neoplasia, altered appearance of lesions and natural course of diseases can be more profound in individuals with concurrent HIV-1 infection and NF 1. We report this case to draw attention to rarely reported occurrence of HIV infection in a patient with NF 1, and whether HIV-1 infection can influence the course of NF 1 lesions.

CASE REPORT

Our patient is a 30-year old female trader who was first seen in the HIV outpatient clinic of the Jos University Teaching Hospital (JUTH), Jos, Nigeria about a year ago and was diagnosed as having WHO stage 1 HIV-1 disease. She also presented with a history of multiple skin growths all over the body since childhood. The growths had increased in size and number but have remained virtually the same in the last couple of years. There were no associated symptoms in all the other body systems. She is the fifth of seven siblings. Her mother, who died of obstetric complications, her younger sister and her 13 year old child, had similar skin lesions. She is a single mother who does not smoke cigarettes or drink alcohol.

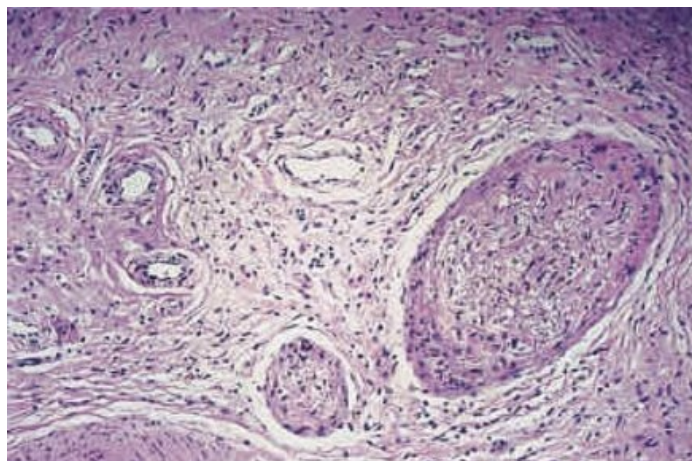
Physical examination revealed a young woman with extensive soft sessile and pedunculated nodules mostly on the trunk, numerous cafe-au-lait spots and axillary freckling (Figure 1). The largest nodule measured 8cm by 4cm while over 10 cafe-au-lait spots were more than 1.5cm in diameter each. The rest of the examination was unremarkable. Her baseline CD4+ cell count and HIV-1 viral load were 126 cells/ μ l and 12,494 copies/ml

respectively. Histopathological section of one nodule showed bundle of masses with spindle-shaped cells and waxy cytoplasm revealing a cellular and loose area consistent with a neurofibroma (Figure 2). A diagnosis of NF 1 based on the National Institute of Health Consensus Development Conference (NIHCDC) criteria¹⁰ with AIDS was made and she commenced Nevirapine based Highly Active Antiretroviral Therapy (HAART). She was offered genetic counselling, scheduled for regular clinical review for her HIV disease and surveillance of the nodules, and any conditions that may be associated with neurofibromatosis. She became virologically suppressed at 12 weeks of HAART while her CD4+ cell count rose to 291 cells/µl at one year of HAART. She did not develop any opportunistic disease and there has not been any appreciable change in the neurocutaneous features or development of any condition related to NF 1 within the one year follow-up period.

(Figure 1). Clinical Picture of Neurofibromatosis type 1: A

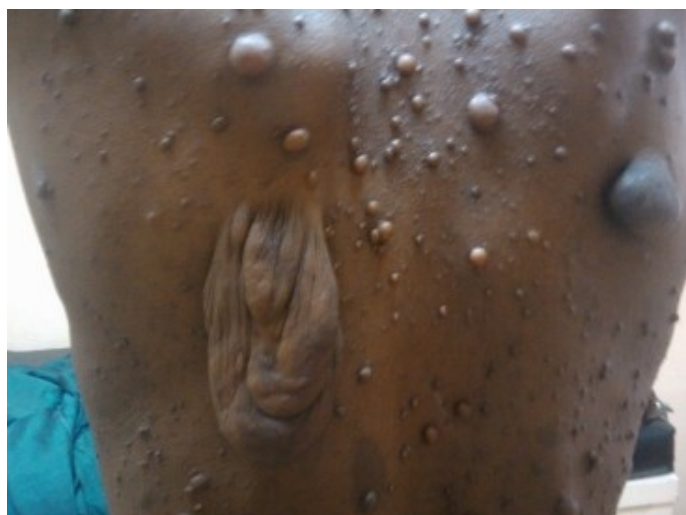

Figure 2: Histology Section of Neurofibromatosis type 1: A



DISCUSSION

We report the case of a 30 year old woman with NF 1 and immunological AIDS who presented to our HIV clinic with florid neurofibromas mostly on the trunk, cafe-au-lait spots and axillary freckling. Her NF 1 disease remained stable and she had adequate response to HAART for the HIV disease.

Similar to our findings, Nyandaiti et al³ reported a mean age of 28 years and the trunk as the commonest neurofibroma site

in 16 (34%) of patients who presented at the surgery department. However, contrasting our findings, Odebo et al¹¹ in a study of 98 patients reported the lower limbs as the most frequently affected site and none of the patients had skin freckling. Due to high awareness and prevalence of florid skin diseases in HIV infection,¹² the HIV clinician can expect to be consulted for diseases referable to other specialties.

Although the diagnosis of NF 1 was easy in our patient, skin lesions in AIDS tend to display unusual clinical and biologic behaviour. Furthermore, among other lesions, Kaposi's sarcoma, the commonest cutaneous tumour in HIV/AIDS may resemble plexiform or small sparsely distributed neurofibromas.^{13,14} Therefore, diagnostic challenge may arise with possible grave consequence if missed.

While the natural course of NF 1 over time is poorly understood, neurofibromas and cafe-au-lait spots generally increase in size and numbers from childhood through adolescence levelling off in adulthood.¹⁵ That our patient presented in adulthood when the cutaneous manifestations of NF 1 reportedly level off may explain the apparent lack of change in the lesions despite her HIV induced immune suppression. In addition, we are unable to say for how long our patient has had immunological AIDS; whether immune reconstitution due to HAART staved off any possible change in the lesions; whether the one year period under review is too short for any noticeable change to occur or that indeed, her HIV infection did not influence the natural course of the NF 1 lesions.

CONCLUSION

The profound HIV induced immune suppression did not seem to impact NF 1 in our patient. However, large studies in which patients are followed over an extended period of time are needed to better explore possible interactions between HIV infection and NF 1.

REFERENCES

1. Huson SM, Compston DAS, Clark P, et al. A genetic study of von Recklinghausen neurofibromatosis in south east Wales: prevalence, fitness, mutation rate, and effect of parental transmission on severity. *J Med Genet* 1989; 26: 704-11
2. Atadzhanov M. Hereditary neurological diseases at University Teaching Hospital, Lusaka. [www.mjz.co.zm/hereditary neurological diseases](http://www.mjz.co.zm/hereditary_neurological_diseases). Downloaded on the 6th December, 2011.
3. Nyandaiti YW, Tahir C, Nggada HA, Ndahi AA. Clinico-pathologic presentation and management of neurofibromatosis type 1 disease among north-eastern Nigerians: A six year review. *Nmj*. 2009; 50: 80-83.
4. Xu GF, O'Connell P, Viskochil D, et al. The neurofibromatosis type 1 gene encodes a protein related to GAP. *Cell* 1990; 62: 599-608.
5. SA Rasmussen, JM Friedman. NF1 Gene and Neurofibromatosis 1. *AjE*. 2000; 151: 33-39.
6. Newcomb-Fernandez J. Cancer in the HIV-infected population. *Res Initiat Treat Action*. 2003; 9: 5-13.
7. Demopoulos BP, Vamvakas E, Ehrlich JE and Demopoulos R. Non-Acquired Immunodeficiency Syndrome-defining malignancies in patients infected

- with Human Immunodeficiency Virus. *Arch Path Lab Med.* 2003; 127: 589-592.
8. Spano JP, Atlan D, Breau JL, Farge D. AIDS and non-AIDS-related malignancies: a new vexing challenge in HIV-positive patients. Part I: Kaposi's sarcoma, and Hodgkin's lymphoma. *Eur J Int Med* 13: 170-179, 2002.
 9. Mbulaiteye SM, Biggar RJ, Goedert JJ, Engels EA. Immune deficiency and risk for malignancy among persons with AIDS. *J Acquir Immune Defic Syndr* 32: 527-533, 2003.
 10. National Institutes of Health Consensus Development Conference Statement: neuro? bromatosis. *Arch Neurol* 1988; 45: 575-78.
 11. Odebode TO, Afolayan AO, Adigun AI, Daramola OO. Clinicopathological study of Neurofibromatosis type 1: an experience in Nigeria. *Int J Derm.* 2005; 44: 116-120.
 12. Sivayathorn A, Sriha B, Leesanguankul W. Prevalence of skin diseases in patients with HIV in Bangkok, Thailand. *Ann Acad Med Singapore.* 1995; 24: 528-533.
 13. Leppard B. *An Atlas of African Dermatology.* Oxon. Radcliffe Medical Press Ltd. 2002: 268-270.
 14. Waugh M. Skin diseases- clinical indicator of immune status in HIV infection. *Int J Dermatol* 2007;44:705-706.
 15. McGaughran JM, Harris DI, Donnai D, et al. A clinical