



## INTERLOCKING NAILING OF LOWER LIMB FRACTURES AT THE UNIVERSITY OF PORT HARCOURT TEACHING HOSPITAL (UPTH), RIVERS STATE

\*F Orupabo, SI Harcourt, PD Eyimina

Orthopedic Department, University of Port Harcourt Teaching Hospital, Rivers State, Nigeria.

\*Corresponding Author: Furo Orupabo; Email: orupsd1st@yahoo.com

### ABSTRACT

**Background:** The interlocking intramedullary nail has become the standard treatment for most long-bone diaphyseal and selected metaphyseal fractures. The Surgical Implant Generation Network (SIGN) intramedullary nail is a set designed for use in treating patients in resource poor regions who need, but cannot afford an intramedullary interlocking system.

**Aim:** To assess the demographics, pattern of injuries and surgical outcome of patients with lower limb fractures treated with the SIGN interlocking nails at the University of Port Harcourt Teaching Hospital.

**Methods:** All patients who had intramedullary nailing of lower limb long bone fractures between March 2013 and March 2016 using the SIGN nails were included in this study. Details on demographics, bone fractured and surgical technique were collected using the SIGN database proforma.

**Results:** Fifty one surgeries were performed on forty eight (48) patients, fourteen females and thirty four males. Male to female ratio was 2.4: 1 and ages ranged between 18 and 90 years, the mean age being  $38.7 \pm 1.6$  years. Thirty seven (72.5%) patients had femoral fractures while fourteen (27.5%) patients had tibial fractures, three (5.9%) of these patients had floating knees. A total of forty nine (96.1%) fractures showed clinical and radiologic evidence of fracture healing at six months. Total complication rate was 10.5%, and included two (4.2%) cases of surgical site infection, one (2.1%) case of post-operative bleeding and one (2.1%) case each of missed distal interlock and implant failure.

**Conclusion:** The advantages of interlocking intramedullary nail fixation of long bone diaphyseal fractures have been well documented. Despite the disadvantages of opening the fracture site and disrupting the fracture hematoma, the SIGN system, with open reduction of the fracture is quite adequate in treating these fractures.

**Keywords:** SIGN, Intramedullary nail, fractures, UPTH





## **INTRODUCTION**

The Surgical Implant Generation Network (SIGN) intramedullary nail and interlocking screw set is a set designed for use in treating patients who need, but cannot afford an intramedullary interlocking system.<sup>1</sup> The system has been distributed to numerous centers in low and middle income countries around the world<sup>2</sup>, of which the University of Port Harcourt Teaching Hospital (UPTH) is one. The SIGN database implemented in 2003 was set up to record all SIGN surgeries performed, including pre- and post- operative radiographs.

The interlocking intramedullary nail is commonly used for long-bone fracture fixation and has become the standard treatment for most long-bone diaphyseal and selected metaphyseal fractures.<sup>3-7</sup> Fracture reduction is usually done closed with the aid of an image intensifier which is not readily available in most centres in developing countries.<sup>8,9</sup> The SIGN nail is designed to be used without an image intensifier. However, open reduction of the fracture needs to be done.

Although the SIGN nail has been available for decades, it is relatively novel in Nigeria, and is likely to have a learning curve before most surgeons become comfortable with the use of the external interlocking jig. Hence, the study aiming to assess the demographics, pattern of injuries and surgical outcome of patients with lower limb fractures treated with the SIGN interlocking nails at UPTH.

## **METHODOLOGY**

This study was carried out in the orthopaedic unit of the University of Port Harcourt Teaching Hospital which is a 500 bed tertiary institution owned and managed by the Federal Government of Nigeria, and employed a cross sectional design involving all patients who had intramedullary nailing of lower limb long bone fractures between March 2013 and March 2016 using the SIGN nails. Details on demographics, bone fractured and surgical technique were collected using the SIGN database pro-forma. Data were analyzed using the Statistical Package for Social Sciences (SPSS) version 20. Data were presented as tables and charts. Frequencies and proportions were used to summarize data.



## **RESULTS**

Fifty one surgeries were performed on forty eight (48) patients, fourteen females and thirty four males. Male to female ratio was 2.4: 1 (Fig. 1). The ages ranged between 18 and 90 years, with the majority, (15 patients) being within the 31 to 40 age group (Fig. 2) and the mean age  $38.7 \pm 1.6$  years. Thirty seven (72.5%) patients had femoral fractures, fourteen (27.5%) patients had tibial fractures while three (5.9%) of these patients had floating knees.

The frequency of involvement of the left and right limbs was almost equal and majority of fractures were closed (92.2%) (Table 1). Open reduction was performed for all fractures. Distribution of nail sizes and the number of each size used is shown in Table 2; all nails were locked proximally and distally with at least one interlocking screw.

A total of forty nine (96.1%) fractures showed clinical and radiologic evidence of fracture healing at 6 months; these included all patients with tibial fractures and thirty five patients with femoral fractures

There were two cases (4.2%) of infection, both in open fractures; one superficial infection in a tibial fracture, managed with antibiotics and wound dressing and one deep infection in a femoral fracture which required removal of the implant and application of an external fixator. One (2.1%) patient had post-operative bleeding severe enough to necessitate intervention. The distal interlock screw hole was missed completely in one (2.1%) patient with a femoral fracture. The patient was taken back to theatre and the screw placed adequately. There was one (2.1%) case of implant failure. Total complication rate was 10.5%. (Table 3)

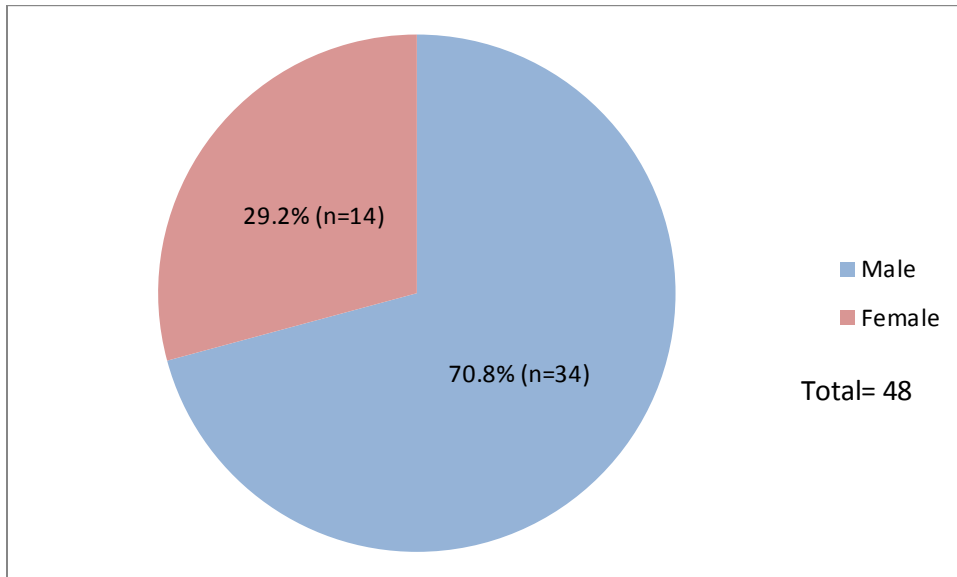


Figure 1: Gender distribution of patients

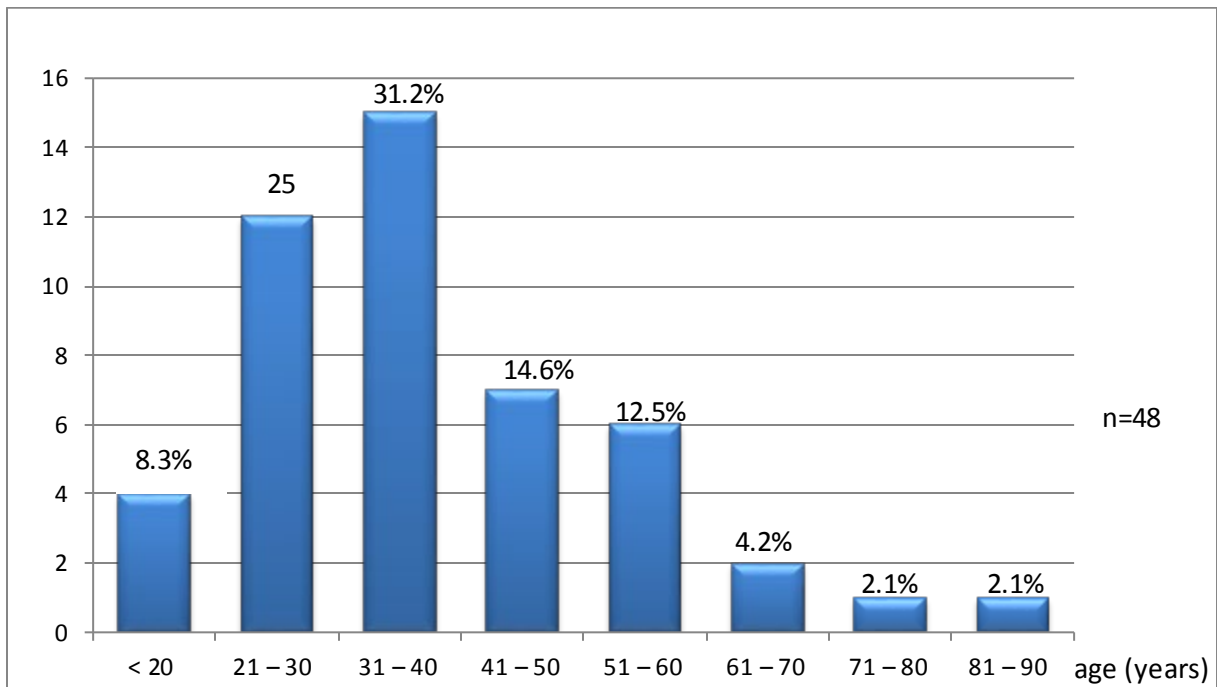


Figure 2: Age distribution

**Table 1: Features of fracture among patients**

Features of fracture	N	%
<b>Type of fracture*</b>		
Closed	47	92.2
Type 1+	3	5.9
Type 3+	1	2.0
<b>Site of fracture*</b>		
Femur	37	72.5
Tibia	14	27.5
<b>Side of fracture*</b>		
Left	26	51.0
Right	25	49.0

\*Three (3) patients had double fractures

+ Using the Gustillo and Anderson classification of open fractures

Table 2: distribution of nail sizes

Nail diameter (mm)	Nail length (mm)						
	280	300	320	340	360	380	400
8	1	2	2	2	2	2	0
9	0	1	3	3	8	2	2
10	2	2	1	4	2	6	4

Table 3: Complications

	N	%
Missed distal interlock	1	2.1
Broken nail	1	2.1
Post op bleeding	1	2.1
Infection	2	4.2
Total	5	10.5

## DISCUSSION

Interlocking nailing can be used to fix almost any lower limb diaphyseal fracture. It reduces surgical exposure and periosteal stripping, acts as a load-sharing internal splint, and offers greater rotational stability while counteracting axial and bending forces.<sup>8</sup> This study examined the demographics of patients who had interlocking nailing of lower limb fractures due to trauma, either acutely, or following mal-unions and non-unions as well as outcome and complications. The standard for lower limb long bone shaft fractures is early surgery (preferably within 48hours), closed reduction and nailing. However in resource poor countries, where imaging is not available, open reduction may be performed. This was done for all patients.

Majority of patients were male, with the modal age group being the 21 to 40 year age bracket, which is consistent with most other national and international trauma statistics.<sup>5,14</sup> Femoral fractures were commoner, probably due to the fact that various other options are available for adequate management of tibial fractures, including non-operative management and the use of external fixation.<sup>10,11</sup>

Both proximal and distal interlocking are necessary to provide rotational stability, the interlocking screw may be placed in the static or dynamic holes, hence a minimum of two interlocking screws (one proximal, one distal) were inserted for each nail. All the surgeons expressed varying degrees



of difficulty in achieving distal interlock, especially for the femur, and in one case it was missed completely, necessitating a return to theatre.

Fracture union rate was 96.1% at six months, which is comparable to that of the literature available for both open and closed reduction.<sup>15,16</sup>

Documented complications of intramedullary interlocking nail can be categorized into intraoperative, early postoperative, and late postoperative, including but not limited to fracture propagation, inadequate/poor fixation, neurovascular injury, superficial and deep wound infection, compartment syndrome, deep vein thrombosis, delayed union, non-union and implant failure, open reduction is said to increase complication rate.<sup>12,13</sup> Some studies have however shown comparable complication rates between open and closed reduction.<sup>15-17</sup> Our complication rate was 10.5%, which is similar to those in these studies.

Although the SIGN nail is provided free of charge, several patients still had challenges in providing drugs and paying for pre- and post-operative radiographs and other hospital fees. A lot of potential patients signed against medical advice and left the hospital to patronize traditional bone setters.

## **CONCLUSION**

Intramedullary interlocking nailing has become the standard for fixing lower limb diaphyseal fractures. The SIGN system is advantageous in low and middle income countries as the implants and instrumentation are provided free of charge and the external jig makes distal locking possible without the use of an image intensifier. This study shows acceptable rate of fracture healing and low complication rate despite the disadvantages of opening the fracture site and disrupting the fracture hematoma. Although some surgeons experience some difficulty in achieving distal locking, the SIGN system, with open reduction of the fracture is quite adequate in treating these fractures.

## **REFERENCES**

1. Lewis G. Zirkle Jr. Technique Manual of SIGN IM Nail & Interlocking Screw System Insertion & Extraction Guide,[website] [www.sign-post.org](http://www.sign-post.org); 2008.11.15
2. Ranjeet N, Sapkota K, Onta P, Thapa P, Thapa UJ, Gupta MK. SIGN Nail Experience in Manipal Teaching Hospital. American Journal of Public Health Research 3.5A, 2015; 3, 115-118.
3. Feibel RJ, Zirkle Jr. Use of interlocking intramedullary tibial nails in developing countries. Tech Orthop 2009; 24: 233-46.



4. Lawrence Akinyoola, Olaniran Orekha, Afolabi Odunsi Open intramedullary nailing of neglected femoral shaft fractures: Indications and outcome. *Acta Orthop. Belg.*, 2011; 77: 73-77.
5. Manoj Kumar Chakraborty, Pabin Thapa, Brijesh Sathian; Surgical Implant Generation Network (SIGN) Solid Intramedullary Interlocking Nail in the Lower Extremity: An Observational Study from Western Nepal, *Journal of Clinical and Diagnostic Research*. 2011; 5(8): 1614-1617.
6. Bong MR, Kummer FJ, Koval KJ, Egol KA. Intramedullary nailing of the lower extremity: Biomechanics and biology. *J Am Acad Orthop Surg* 2007; 15(2): 97-106.
7. L. N. Gakuu, Comprehensive global evolution of intramedullary nailing of diaphyseal fractures, *East African Orthopaedic Journal* 2009; 3: 36-39.
8. Ikpeme Ikpeme, Ngim Ngim, Anthony Udosen, Obiora Onuba, Okokon Enembe, Segun Bello, External jig-aided intramedullary interlocking nailing of diaphyseal fractures: experience from a tropical developing centre, *International Orthopaedics (SICOT)*, 2011; 35:107-111.
9. Ikem IC, Ogunlusi JD, Ine HR, Achieving interlocking nails without using an image intensifier. *Int Orthop*. 2007; 31(4): 487-90.
10. Toivanen JA. The management of closed tibial shaft fractures. *Current Orthopaedics* 2003;17:167-75.
11. Dahiru IL, Amaefule KE, Lawal YZ, Ogirima MO, Maitama MI, Ejagwulu F, et al. Locked intramedullary nailing for tibial and femoral shaft fractures: Challenges and prospects in a Tertiary Health Care Facility in a resource constraint setting. *Arch Int Surg* 2016; 6:96-9.
12. Koval, Kenneth J.; Clapper, Mark F.; Brumback, Robert J.; Ellison, P. Stribling Jr.; Poka, Attila; Bathon, G. Howard; Burgess, Andrew R, Complications of Reamed Intramedullary Nailing of the Tibia. *Journal of Orthopaedic Trauma*, 1991; 5(2):184-189.
13. FE Ogedegbe, OR Babalola. Outcome of Interlocking Intramedullary Nailing in the Treatment of Diaphyseal Tibial Fractures. *Nigerian Journal of Orthopaedics and Trauma* 2012; Vol 11, No 1
14. Irfanullah Khan, Shahzad Javed, Gauhar Nawaz Khan, Amer Aziz. Outcome of Intramedullary Interlocking SIGN Nail in Tibial Diaphyseal Fracture; *Journal of the College of Physicians and Surgeons Pakistan* 2013, Vol. 23 (3): 203-207.
15. Babalola OM, Ibraheem GH, Ahmed BA, Olawepo A, Agaja SB, Adeniyi A. Open intramedullary nailing for segmental long bone fractures: An effective alternative in a resource-restricted environment. *Niger J Surg* 2016;22:90-5.





16. Telgheder ZL, Albanese MA, Bloom DS, Kurra S, Sullivan MP. A Comparison of Complications and Union Rates in Intramedullary Nailing of Femoral Shaft Fractures Treated With Open Versus Closed Reduction. *Orthopedics*. 2020 Mar 1;43(2):103-107.
17. Syed Imran Ghouri, Abduljabbar Alhammoud, Mohammed Mubarak Alkhayarin, "Does Open Reduction in Intramedullary Nailing of Femur Shaft Fractures Adversely Affect the Outcome? A Retrospective Study", *Advances in Orthopedics*, 2020, Article ID 7583204, 5 pages, 2020. <https://doi.org/10.1155/2020/7583204>