

Ataxia Telangiectasia - A Report of a case in Port Harcourt

Case: Report

Lucy Yaguo-Ide, Tochi Uchenwa, Balafama Alex-Hart, Alice Nte, Chidi Ezeani

Department of Paediatrics and Child Health, University of Port Harcourt Teaching Hospital, Port Harcourt, Nigeria.

ABSTRACT

BACKGROUND

Ataxia telangiectasia is a complex multi-systemic disorder with immunologic, neurologic, endocrinologic, hepatic and cutaneous abnormalities. It is characterized by progressive neurologic impairment, cerebellar ataxia, variable immunodeficiency with increased susceptibility to sino-pulmonary infections, impaired organ maturation, x-ray hypersensitivity, ocular and cutaneous telangiectasia, and a predisposition to malignancy

AIM

To present a case of ataxia telangiectasia in an 8 year old female.

CASE REPORT

An 8 year old female with 5 years history of recurrent cough and fast breathing, 3 years history of poor weight gain. She achieved normal early developmental milestones. She is the second child of adoptive parents and was adopted at 2 weeks of age. Her biological mother was said to have died immediately after delivery. Her adoptive parents were of high socioeconomic class. The detail of child's family history was not known to the adoptive parents. An initial diagnosis of upper respiratory tract infection to rule out pulmonary tuberculosis was made. Subsequently diagnosis was changed to recurrent bronchopneumonia in a child with primary immunodeficiency

secondary to ataxia telangiectasia following recurrent cough and fast breathing, appearance of ocular telangiectasia, onset of ataxia and result of investigations 4 years after initial presentation. She received several antibiotics in the course of the illness and also received anti tuberculous drugs. She also had human immunoglobulin therapy and was immunised with pneumococcal and influenza vaccines with some clinical response but subsequently died.

CONCLUSION

Ataxia telangiectasia is a rare multi-systemic disorder with high morbidity and mortality in children. Delay in diagnosis and pulmonary complications contribute to a higher morbidity and mortality. There needs to be greater awareness of this disorder and its complications because early management with monitoring of lung function may improve outcome.

KEYWORDS

Ataxia telangiectasia, pulmonary complications, children

INTRODUCTION

Ataxia telangiectasia (A-T) was first described by Syllaba and Herner in 1926¹ but described as a specific disorder in 1941 by Louis-Bar in a 9 year old Belgian child with progressive cerebellar ataxia and oculocutaneous telangiectasia.² Border et al³ in 1958 described organ developmental abnormalities, neurologic manifestations and a third major

feature of the disease recurrent sinopulmonary infection with the aid of autopsies. They also recognized the familial incidence proposing an autosomal recessive mode of inheritance for the disease. Thus the term ataxia telangiectasia was introduced.

A-T is a rare autosomal recessive multi system disorder characterized by progressive cerebellar ataxia, oculocutaneous telangiectasia, recurrent sinopulmonary infection, variable humoral and cellular immunodeficiency, high incidence of mainly Blymphoid malignancy and hypersensitivity to ionizing radiation.⁴ Data on the prevalence of A-T in Nigeria is limited. Few cases of A-T have been reported in Nigeria.⁵ The prevalence is about 1: 40,000-100,000 births.^{6,7} It occurs in all races and affects males and females equally.⁸

We report this case of A-T in Port Harcourt to highlight its existence, create more awareness about the disease and its complications in our children.

CASE REPORT

An 8year old female who first presented at the department of Paediatrics University of Port Harcourt Teaching Hospital at 3.5years of age with a complaints of cough and catarrh of 3weeks duration. Cough was non paroxysmal, non distressful and worse at night. There was no history of contact with any case of chronic cough. Catarrh was productive of cream coloured discharge and free flowing. Examination findings at presentation revealed no significant abnormality in the systems. A diagnosis of upper respiratory tract infection to exclude pulmonary tuberculosis was made. She was asked to do Mantoux test, full blood count with erythrocyte sedimentation rate (ESR), chest X-ray and was commenced on syrup co-amoxiclavon outpatient basis.

She was reviewed a week later and results retrieved showed a negative Mantoux test, full blood count showed leucocytosis of $13.9 \times 10^9/L$ with absolute neutrophilia of 74%, lymphocyte

count of 26%, normal platelet count of $227 \times 10^9/L$, PCV of 37% and raised ESR of 14mm/hr. Chest X-ray showed mottled opacities in the hilar and upper zones of both lungs and right lung base. Cardiac silhouette was normal and the thoracic cage was intact. There was no remarkable improvement as cough and catarrh persisted. Systemic examination findings were not remarkable. A diagnosis of? A typical pneumonia was made and she was commenced on syrup erythromycin. She was however lost to follow up thereafter.

She presented again 3.5years later at age 7 years with a 4years history of recurrent productive cough and 3years history of poor weight gain. She was noted to have been treated with anti- tuberculosis drugs category (CAT)I in a private hospital in the past. The treatment was interrupted after about 4months because of apparent poor response. Examination findings on this visit were that she was chronically ill and wasted (weight was 16kg: 72% expected),she had bilateral conjunctival injection and bilateral coarse crepitations on chest examination. Chest X-ray showed diffuse miliary opacities especially in the left lung field. Full blood count showed leucocytosis with WBC count of $16.1 \times 10^9/L$ with neutrophilia (neutrophils -75%, lymphocytes- 23%)and elevated ESR of 24mm/hr. Retroviral screening for HIV I &II was seronegative and culture for acid fast bacilli (AFB)was negative for three consecutive sputum samples. A diagnosis of pulmonary tuberculosis with probably superimposed bacterial bronchopneumonia was made. She was admitted and commenced on intravenous antibiotics and CAT II anti tuberculous drugs. She was subsequently discharged after 3weeks and was on regular follow up.

Subsequent review showed some clinical improvement but repeat Chest X-ray still showed patchy consolidations. Few weeks after completion of the anti-TB drugs for 8months, examination showed that she was dyspnoeic, tachypnoeic with respiratory rate of 37cycle per minute, had reduced breath

sounds with coarse crepitations on the left lower lung zone. Computed tomography (CT) scan of the chest done showed small left hemithorax compared to the right with an inhomogeneous opacity in the left upper lung zone obscuring a part of the left cardiac border with affectation of the pleura on the left. A diagnosis of left lung collapse was made. She was however not reviewed again till after 3 months because of ongoing industrial action in the hospital. Chest MRI done at this time showed progressive lung fibrosis. Additional examination findings noted were ataxia and ocular telangiectatic blood vessels. Further investigations done to elucidate the cause of the illness included Brain MRI which was normal, serum immunoglobulin assay revealed low levels of IgA (8mg/dl), IgG (27mg/dl) and IgM (25mg/dl), ECG and E/U/Cr done were normal. Sputum AFB and Gene Xpert results for tuberculosis to detect drug resistance were not helpful. The diagnosis was then changed to Primary immunodeficiency secondary to ataxia telangiectasia. She was subsequently readmitted 2 months after because of worsening respiratory distress and cough. Systemic examination revealed, wasted child, small for age (weight was 15kg:58% expected), dyspnoeic, pectusexcavatum, tachypnoeic with respiratory rate of 48cpm, dull percussion notes on the mid and lower lung zones, markedly reduced breath sounds bilaterally worse on the left and bilateral crepitation also worse on the left. She had tachycardia with heart rate of 140 bpm, she was conscious, had slow speech, ocular telangiectasia, oculomotor apraxia and no nystagmus was detected. She also had difficulty with writing and using utensils with intention tremors, had variable tone and deep tendon reflexes alternating between normal and reduced, sensation was intact, Romberg sign was equivocal and she had ataxic gait. Other systemic examination findings were normal. Serum alpha fetoprotein (AFP) assay done was markedly elevated (206.7ku/L). Parents were counselled on the child's illness. Management was multi disciplinary by the Pulmonologist, Neurologists, Dieticians, Haematologist,

Physiotherapist and Speech therapist. She was immunised with Pneumococcal and Influenza vaccines, received parenteral antibiotics, antifungal and Intravenous immunoglobulin 10g twice at 4 weekly interval and repeat serum immunoglobulin assay was done after 4 weeks of immunoglobulin therapy. She was on reverse barrier nursing, intranasal oxygen therapy, physiotherapy, nutritional rehabilitation with some clinical response and was subsequently discharged home. She however did not come for follow up and mother later informed us that she died.

Table 1. FBC Results

Date	PCV	WBC	Neut	Lymph	Platelets	ESR
Nov 2009	37%	13.9x10 ⁹ /L	74%	26%	227x10 ⁹ /L	14mm/hr
May 2013	—	16.1x10 ⁹ /L	75%	23%	—	24mm/hr
May 2014	—	8.3x10 ⁹ /L	55.6%	31.3%	—	
Sept 2014	44%	6.3x10 ⁹ /L	55%	28%	202x10 ⁹ /L	16mm/hr

Table 2: Immunoglobulin assay

	Initial Immunoglobulin Assay	Immunoglobulin Assay after IV Human Immunoglobulin
IgG	27mg/dl (598-1379mg/dl)	630mg/dl (598-1379mg/dl)
IgA	8mg/dl (33-258mg/dl)	15mg/dl (33-258mg/dl)
IgM	25mg/dl (56-242mg/dl)	418mg/dl (56-242mg/dl)

Fig 1. Chest Radiograph showing Progressive Fibrosis

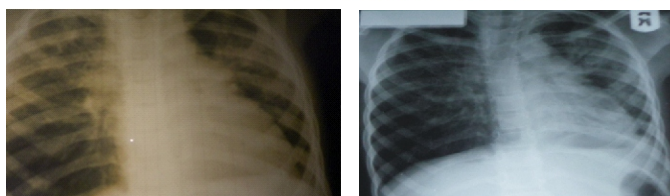
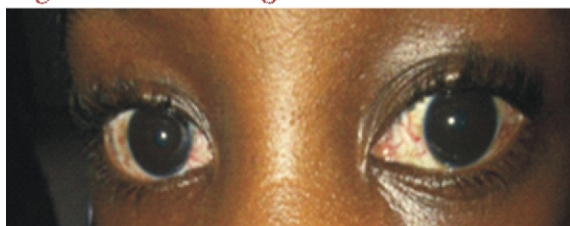

Fig 2. Ocular Telangiectasia



DISCUSSION

A-T is a rare heterogeneous autosomal recessive disorder with multi-systemic involvement.^{4,9} It occurs in all races and has no sex predilection.⁸ Our patient was a female. Mutations in ATM gene located at 11q22-q23 are responsible for this defect and its major features.⁹ The gene product ATM protein is a

DNA-dependent protein kinase localized predominantly to the nucleus and involved in mitogenic signal transduction, meiotic recombination and cell cycle control⁹. Defects in this function will result in increased rate of apoptotic cell death, radiosensitivity, and the premature death of neuronal cells, especially cerebellar Purkinje and granular cells¹⁰. The clinical and immunological presentation of ataxia-telangiectasia may differ even within the same family, as described by Soresina et al.¹¹

Major clinical and pathological features in A-T are progressive neurologic impairment, cerebellar ataxia, variable immunodeficiency with susceptibility to sinopulmonary infections, impaired organ maturation, x-ray hypersensitivity, ocular and cutaneous telangiectasia and a predisposition to malignancy.⁴ Ataxia is usually the 1st diagnostic hallmark having its onset in the 1st year of life. The progression becomes increasingly apparent beyond the age of 5 and child requires a wheel chair by 10-12 years of age.⁹ Mother was not sure of the age at onset of ataxia in our patient but was however noted in our patient at about 7 years of age. Onset of oculocutaneous telangiectasia is typically at 3-6 years, onset in our patient was at 7 years.⁹ Studies have shown variable immunodeficiency in A-T patients and about 50% of patients have recurrent sinopulmonary infection.^{12,13} Pulmonary infections in A-T are usually caused by viruses during the first two years of life, and by common bacterial pathogens in later childhood, such as *Hemophilus influenzae*, *Streptococcus pneumoniae*, *Pseudomonas aeruginosa* and *Staphylococcus aureus*. These common infections are often correlated to the severity of humoral defect.¹⁴ Our patient had immunodeficiency with low levels of immunoglobulins and recurrent sinopulmonary infections. Incidence of malignancy have been found to be 60-300 times higher than in healthy persons, and common tumours have been found to be of the lympho-reticular type.¹⁵ Our patient had no evidence of malignancy and evidence for X

ray hypersensitivity could not be ascertained because genetic studies on exposure to X ray was not done. In a study carried out by Moinet al¹⁶ among Iranian patients to characterize the clinical and immunologic features of 104 patients with A-T, progressive ataxia was reported in 100% of them, 83.8% had ocular telangiectasia and 70.2% had cutaneous telangiectasia. Eye movement disorder was seen in 80.6%, 75% had acute recurrent infections, 53.9% had pneumonia while 64.9% had recurrent upper respiratory infection, 87.1% had choreoathetosis and speech dysarthria was seen in almost all the patients. These features were all seen in our patient except cutaneous telangiectasia which may be masked by our patient's dark skin.

A-T can be classified according to its major clinical and pathological features into type I-IV.¹⁷ Type I is the classic syndrome with all manifestation, Type II lacks some of the typical findings but shows radiosensitivity, Type III has the classic clinical findings but is not radiosensitive and Type IV shows only some clinical features and is not radiosensitive. We could not classify our patient because we could not ascertain if she had radiosensitivity.

The diagnosis of A-T is usually clinical but can be problematic before appearance of ataxia and telangiectasia. A-T diagnostic criteria was formulated by Ataxia-Telangiectasia Clinical Center at the Johns Hopkins Medical Institutions, which is as follows:^{18,19}

Diagnostic criteria 1¹⁸: Ataxia or significant motor incoordination with raised alpha fetoprotein (AFP) (>2x) +3 of the following four characteristic clinical features:

1. In coordination of head and eyes in lateral gaze deflection
2. Ocular telangiectasia
3. Gait ataxia associated with an inappropriately narrow-base
4. Immunoglobulin deficiencies

Patients with less than three of these characteristics were required to have the

diagnosis confirmed by the finding of radiation-induced chromosomal breaks in lymphocytes. Siblings of known patients with AT who are older than 1 year of age and had ataxia only needed to have an elevated AFP.

Diagnostic criteria 2:¹⁹ Presence of characteristic neurologic features (gait ataxia, oculomotor dysfunction, dysarthria, and a movement disorder) and at least one of the following:

1. Oculo-cutaneous telangiectasia
2. Elevated levels of alpha-fetoprotein in serum
3. Spontaneous or X irradiation-induced chromosomal breakage

Our patient fulfilled both of these two diagnostic criteria. The diagnosis in our patient was made by clinical and laboratory findings. Laboratory markers are important for both diagnosis and prognosis. Elevated levels of AFP and carcinoembryonic antigen (CEA) are the most useful readily available markers for confirmation of the diagnosis²⁰. Chromosomal studies to demonstrate spontaneous chromosomal breakage or following irradiation is also useful but requires special techniques and is only available in special centers. Our patient had markedly elevated AFP however CEA was not done and chromosomal studies could not be done. The dysgammaglobulinemia of A-T includes an absent or low level of IgA (including secretory IgA), a normal or low level of IgG, an elevated or normal level of IgM, IgE may also be absent or low. Elevated IgM is evident in only 60% of patients and IgA deficiency is found in about 70% of patients with A-T.²¹ Our patient had low level of IgG, IgM and IgA. Decreased cellular immune responses and peripheral lymphopenia are supportive findings.

There is no specific treatment for A-T. However, gene therapy could be possible in the future and therefore genetic counseling is very important.²² Since the disorder is inherited in an autosomal recessive manner the siblings of an affected individual has a 25% chance of

being affected, 50% chance of being asymptomatic carriers and 25% chance of being unaffected. Heterozygotes (carriers) have an increased risk of developing cancer hence carrier testing for at-risk relatives and prenatal testing for pregnancies at increased risk are possible if the disease causing mutations in the family are known.²³

Treatment is symptomatic and supportive. Management requires a multidisciplinary approach involving the Pulmonologist, Immunologist, Neurologist, Dietician, Physiotherapist and Geneticist. The use of broad spectrum antibiotics in patients with infections is very useful. The development of safe and effective intravenous preparations of immunoglobulin represents a major advance in the treatment of patients with A-T as regular injection of immunoglobulins to prevent infection improves outcome. Immunization of patients against common respiratory pathogens should be routine to reduce respiratory infections. Recurrent sinopulmonary infections often lead to progressive pulmonary fibrosis which was seen in our patient. Mortality from A-T is commonly due to pulmonary disease, 50% die in adolescence from overwhelming bronchopulmonary disease.²⁴ Therefore early diagnosis of A-T and its pulmonary complications may reduce morbidity and mortality in our children.

CONCLUSION

A-T has a wide clinical heterogeneity and is often difficult to diagnose in children. It should be stressed that the course of the disease is variable and difficult to predict. Delay in diagnosis of A-T and its pulmonary complications contributes to morbidity and early mortality. There should be a high index of suspicion for A-T among children with recurrent infections and immunodeficiency to improve outcome.

RECOMMENDATION

Management of patients with A-T should be individualized according to specific needs as these patients need special attention to

improve their quality of life. The immunoglobulins should be made readily available and affordable to improve outcome. There should be more awareness about A-T and its pulmonary complications among Paediatricians to aid early diagnosis and prompt treatment in order to reduce early mortality due to lung disease. Carrier testing for at-risk relatives and prenatal testing for pregnancies at increased risk where facilities are available would be helpful.

REFERENCES

1. Syllaba L, Henner K. Contribution à l'indépendance de l'athetose double idiopathique et congénitale [In French]. *Rev Neurol* 1926;1:541-62.
2. Louis-Bar D. Sur syndrome progressif comprenant des t é l a n g i e c t a s i e s capillariescutanéesetconjunctivalessy métriques, à disposition naevoïde et de troubles cérébelleux [In French]. *Confin Neurol* 1941;4:32-42.
3. Boder E, Sedgwick RP. Ataxia-telangiectasia, a familial syndrome of progressive cerebellar ataxia, oculocutaneous telangiectasia and frequent pulmonary infection. *Pediatrics* 1958;21:526-54.
4. Chun HH, Gatti RA. Ataxia-telangiectasia, an evolving phenotype. *DNA Repair* 2004;3:1187-96.
5. Aiyesiomuju AB, Osuntokun BO, Bademosi O, Adeuja AO. Hereditary neurodegenerative disorders in Nigerian Africans. *Neurology* 1984;34:361-2.
6. Bezerra MCGM, Carvalho BTC. Ataxia telangiectasia: características clinic-laboratoriais. *Ataxia-telangiectasia: a review. Rev. Bras. Allerg. Immunopathology* 2001;24:98-105.
7. Swift M, Morell D, Cromartie E, Chamberlin AR, Skolnick MH, Bishop DT. The incidence and gene frequency of ataxia telangiectasia in the United States. *Am J Hum Genet* 1986;39:573-83.
8. Gatti RA. Ataxia-telangiectasia. *DermatolClin* 1995;13:1-6.
9. Buckley RH. The T, B and NK- cell systems. In: Kleigman RM, Jenson HB, Behrman RE, Stanton BF eds. *Nelson textbook of Paediatrics* 17th ed. Saunders Elsevier, Philadelphia. 699.
10. Crawford TO. Ataxia telangiectasia. *SeminPediatrNeurol* 1998;5:287-94.
11. Soresina A, Meini A, Lougaris V, Cattaneo G, Pellegrino S, Piane M et al. Different clinical and immunological presentation of ataxia-telangiectasia within the same family. *Neuropediatrics* 2008;39:43-5.
12. Woods CG, Taylor AM. Ataxia-telangiectasia in the British Isles: the clinical and laboratory features of 70 affected individuals. *Q J Med* 1992;82:169-79.
13. Staples ER, Mc Dermott EM, Reiman A, Byrd PJ, Ritchie S, Taylor AMR et al. Immunodeficiency in ataxia telangiectasia is correlated strongly with the presence of two null mutations in the ataxia telangiectasia mutated gene. *ClinExpImmunol* 2008;153:214-20.
14. Popa V, Colby TV, Reich SB. Pulmonary interstitial disease in Ig deficiency. *Chest* 2002;122:1594-603.
15. Olsen J, Hahnemann J, Borresen-Dale AL, Brondum-Nielson K, Hammarstrom L, Kleinerman R et al. Cancer in patients with ataxia telangiectasia and in their relatives in the Nordic countries. *J Natl Cancer Inst* 2001;93:121-7.
16. Moin M, Aghamohammadi A, Kouhi A, Tavassoli S, Rezaei N, Ghaffari S-R et al. Ataxia-telangiectasia in Iran : clinical and laboratory features of 104 patients. *PediatrNeurol* 2007;37:21-8.
17. Janniger CK. Ataxia Telangiectasia Clinical Presentation. [internet] 2014 [updated 2014 Oct 8; cited 2014 Nov 17]. Available from : <http://www.emedicine.medscape.com/article/1113394-clinicalpresentation>.
18. Lefton-Greif MA, Crwaford TO, Winkelstein JA, Loughlin GM, Koerner

- CB, Zahurak M et al .Oropharyngeal dysphagia and aspiration in patients with ataxia-telangiectasia. *J Pediatr* 2000;136:225-31.
19. Crawford TO, Mandir AS, Lefton-Greif MA, Goodman SN, Goodman BK, Sengul H et al. Quantitative neurologic assessment of ataxia-telangiectasia. *Neurology* 2000;54:1505-9.
20. Swift M, Morrel D, Massey RB, Chase CL. Incidence of cancer in 161 families affected by ataxia-telangiectasia. *N Eng J Med* 1991;325:1831-6.
21. Azarsiz E, Karaca NE, Gunaydin NC, Gulaz N, Ozturk C, Aksu G et al. Do elevated serum IgM levels have to be included in probable diagnosis criteria of patients with ataxia-telangiectasia? *Int J Immunopathol Pharmacol* 2014;27:421-27.
22. Chaudhary MW, Al-Baradie RS. Ataxia-telangiectasia: future prospects. *The Application of Clinical Genetics* 2014;7 159–167.
23. Gatti R. Ataxia Telangiectasia Gene Reviews [internet] 2010 [updated 2010 March 11; cited 2015 Sept 7] .Available from: <http://www.ncbi.nlm.nih.gov/books/NBK26468>
24. Canny GJ, Roifman C, Weitzman S, Braudo M, Levison H. A pulmonary infiltrate in a child with ataxia-telangiectasia. *Annals of Allergy* 1998;423:466-8.