

Giant Mediastinal Teratoma in the Left Hemithorax A Case Report

Type of Article: **Case Report**

Emmanuel Ossai Ocheli, Christian Emeka Amadi, Uriah Stephen Etawo

Dept of Surgery, University of Port-Harcourt Teaching Hospital, Port-Harcourt, Nigeria.

ABSTRACT

BACKGROUND

Teratomas are rare germ cell tumors and the mediastinum is one of the areas they occur. They are composed of tissues derived from more than one germ cell line. Majority are benign and they present with different clinical manifestations; and, very interesting radiologic features. However, many cases are diagnosed incidentally.

METHOD

We used the case records of the patient managed for a giant mediastinal teratoma in the left hemithorax and reviewed relevant literature.

RESULT

A 33-year-old male was admitted with a two – year history of chest pain; chronic cough with associated occasional hemoptysis; easy fatigability. Clinical signs of unexplained mediastinal shift to the contralateral side, and diminished vesicular breath sounds on the affected side were present. Radiologic studies (CXR & Chest CT); 2D echocardiography were carried out. The CXR and Chest CT showed a large tumor compressing the left lung with calcified deposits seen in different parts of the tumor and pericardial attachment. The ECG showed minor left axis deviation while the echocardiography was suggestive of a posterior mediastinal mass, an ejection fraction of 60% with normal cardiac chamber dimensions. A clinical diagnosis of a teratoma arising from the

mediastinum was made. Through a posterolateral thoracotomy the tumor located in the posterior mediastinum was excised. Histopathology confirmed benign mediastinal teratoma. The patient has been followed up for 2 years without any signs or symptoms of recurrence.

CONCLUSION

Patients with mediastinal teratoma are without symptoms generally but some become symptomatic from pressure effect as the tumor increases in size. This case report highlights the huge size of the tumor, the posterior mediastinal location which is rare, with involvement of the pericardium and the near total atelectasis of the left lung. Surgical excision is the treatment of choice for benign mediastinal teratomas with acceptable surgical risk and optimal long term results.

KEYWORDS

Teratoma; Germ cell tumor; Posterior mediastinum.

*Correspondence: Dr E.O. Ochelli
Email:ocheliossai@yahoo.com*

INTRODUCTION

Teratomas constitute the commonest histologic subtypes of extragonadal germ cell tumors. The usual sites include the sacral region, mediastinum, peritoneum and cranium; and, occasionally in the liver, stomach or within the urogenital tract¹. Mediastinal teratomas (MTs) account for 10-20% of all mediastinal tumors¹. MTs can

typically be cystic or solid or a combination of both, have multiple germ cell layers (with all three seen at times- ectoderm, mesoderm & endoderm) and are composed of tissues alien to the organ or anatomic site in which they occur². They are mainly found in the gonads while the sacrococcygium and the mediastinum are the most common extragonadal sites¹. They grow very slowly being asymptomatic initially and on reaching a critical size may present with non-specific chest discomfort that is often disregarded but a chest radiograph at this stage could point to the diagnosis¹⁻⁴.

CASE PRESENTATION

A 33-year-old male was referred from a peripheral hospital to our institute as a case of progressively worsening chest pain and recurrent cough with occasional hemoptysis of four months duration; history of dyspnea on moderate exertion, easy fatigability. There was no fever, contact with persons with chronic cough, drenching night sweats, weight loss, orthopnea nor paroxysmal nocturnal dyspnea. A healthy-looking man, not in respiratory distress; the only significant clinical signs being tracheal deviation to the right side and markedly reduced breath sounds on the left hemithorax. There were no testicular or abdominal masses. He had received various drugs for the cough and chest pain from different clinics without significant relief. A chest radiograph revealed a large abnormal shadow in the left hemithorax with a near total atelectasis of the left lung and mediastinal shift to the opposite side (Fig. 1a & 1b). The chest CT showed a large mass filling most of the left hemithorax and compressing the left lung with calcified deposits in different parts of the tumor and attached to the pericardium. The ECG showed only minor left axis deviation. The echocardiography collaborated the attachment of the mass to the posterior part of the pericardium and an ejection fraction of 60% and essentially normal cardiac chamber dimensions. A clinical diagnosis of mature teratoma which probably originated in the posterior mediastinum was suspected.

At surgery, through a 5th left posterolateral thoracotomy, a well encapsulated mass in the left hemithorax; surrounded by and attached to the left lung; to the posteromedial part of the pericardium and to the posterior chest wall, was dissected out en block. Due to difficulty in the dissection of the tumor, proximity to the heart and attachment to the pericardium the mass was decompressed by opening into it and carefully removing the contents. This decision was taken due to anesthetist's observations in which preceding attempts at mobilization resulted in rapidly progressive oxygen desaturation and low blood pressure stats. The excised tumor (Fig. 2) was brownish, well circumscribed, had a thick capsule, lobulated, multicystic, filled with mucinous / sebaceous materials, hair, bone-like tissue and teeth. It measured 20 X 12 X 10cm³. Postoperative chest radiograph showed total resolution of the preoperative left lung atelectasis (Fig. 3a & 3b). Patient made an uneventful recovery and was discharged on the 12th post-operative day. Histopathological examination confirmed benign mature mediastinal teratoma. He has been followed up for 2 years without any signs or symptoms of recurrence.

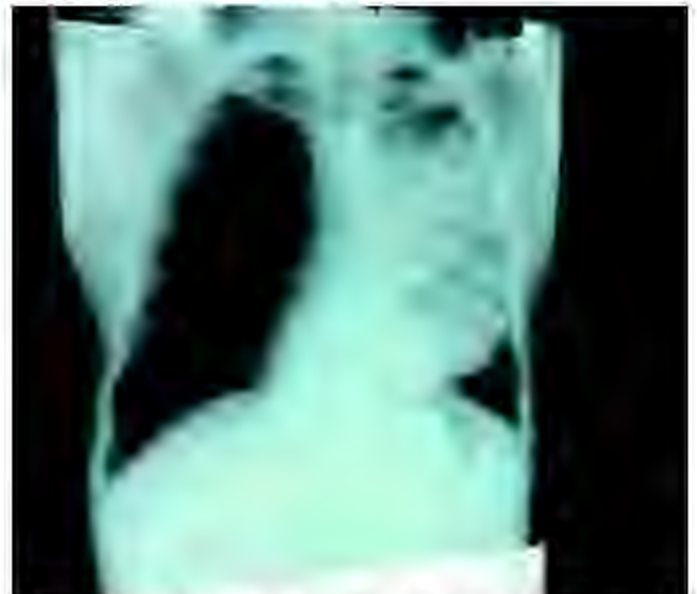


Fig. 1a: Chest Radiograph PA View before surgery showing the mass in the left hemithorax and left lung atelectasis

Fig.2a; The mass seen after exposing the left hemithorax during surgery

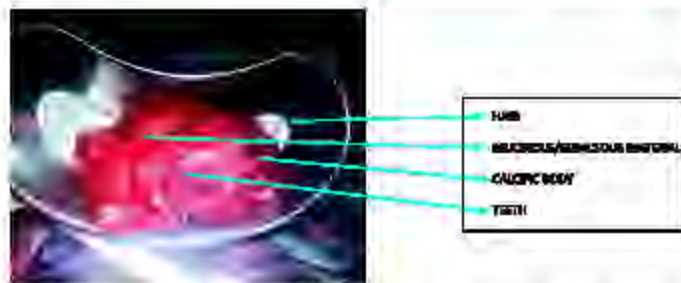
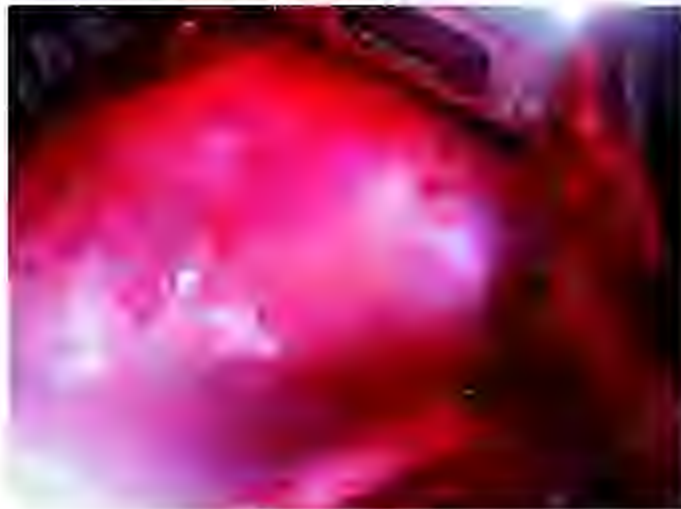

Fig.2a; The mass seen after exposing the left hemithorax during surgery

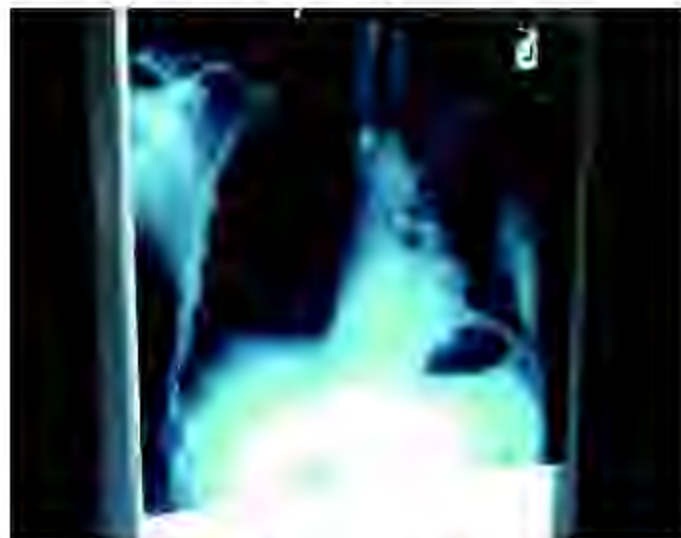

Fig.3a; Chest radiograph PA View immediate postoperatively

DISCUSSION

Mediastinal Teratoma (MT) was first described by J. A. Gordon in 1828 and since then, a variety of atypical presentations have been reported^{1,2}. Diagnosis is made usually following complications; though, many are

incidental findings (with nearly one half of patients, 36-62% in various series having no signs or symptoms at the time of initial diagnosis).¹⁻³ Teratomas are non-homogeneous pathological entities clinically, radiologically or histologically and are commonly diagnosed between the second and fourth decades of life^{3,4}. This case was diagnosed in the fourth decade of the patient's life which is within the age bracket already noted. Though, MTs are said to have equal incidence in both sexes some authors have reported a slight female preponderance with a ratio of 1.27-2.05: 1.00 female : male⁵.

The most common complication of MTs is compression of adjacent structures due to tumor enlargement, which could be in the form of compression of the trachea, bronchi, heart and/or great vessels; and, may present with atelectasis, dyspnea on mild exertion, chest pain, recurrent chest infections, superior vena cava syndrome, atrial fibrillation, pleural effusion etc⁷. Hemoptysis or expectoration of hair (trichoptysis) or sebum can rarely be seen when there is communication between the tumor and the tracheobronchial tree with trichoptysis being the most specific symptom⁶. The patient under discussion, though with giant MT, atelectasis, chest pain, cough with occasional hemoptysis and dyspnea on mild exertion were the only manifestations. One would have expected a more ill patient. Rather, he looked considerably healthy. MT being a slowly growing tumor, adaptation to one lung ventilation over time could be an explanation.

In the diagnostic assessment of MTs, the density of all included tissues are accurately estimated by CT, such as soft tissue (in virtually all cases), fluid (88%), fat (76%), calcification (53%) and teeth and these imaging findings are considered as specific while MRI is excellent in detecting the anatomic relations of MT to the mediastinal and hilar structures such as airways and blood vessels.⁸ When teratoma is suspected, abnormal level of either or both Serum α -fetoprotein and β -HCG is said to be diagnostic,

though, they could be normal. 1Histopathological examination reveals MTs as being spherical or lobulated, with a well-defined capsule, and contain a variety of materials, lipid-rich fluid, cheese-like substances, tooth, hair, and cartilage in benign teratomas which comprises at least two of the three primordial layers; ectoderm, mesoderm and endoderm². In this case, chest radiograph and CT gave a lead to the diagnosis. However, MRI could not be done because of cost.

Treatment of choice for MTs is surgical excision and the preferred surgical access to the tumor depends on the size, location, and extent of the tumor, though, median sternotomy is usually preferred since most MTs are located in the anterior mediastinum, posterolateral or anteroposterior thoracotomy could be used^{2,3}. The use of video assisted thoracoscopic surgery in teratoma resection is quite promising^{6,11}. Surgical outcome is influenced by choice of procedure, patient's age, presence of co-morbidity, tumour characteristics and surgeon's experience.

In this case, left posterolateral access was used, as the tumor was completely located in the left hemithorax, attached to the left lung and left posteromedial part of the pericardium. The tumor was completely excised. Two years after the surgery, patient has remained well without any signs or symptoms of recurrence.

CONCLUSION

Giant posterior mediastinal teratomas are relatively rare compared to the anterior mediastinum. Note that, even when they occur, they could have a relatively mild clinical presentation as in the index patient. Our experience, in line with other reports, shows that in benign mature teratomas, complete surgical excision alone is the treatment of choice with acceptable operative risk and optimal long term result¹⁰.

REFERENCES

1. Christos A, Nikolaos B, Athanassios K, Dimitrios K. Giant mediastinal teratoma presenting with paroxysmal atrial fibrillation. *Interact Cardio VascThorac Surg.* 2011, 12 (2): 308-310.
2. Charalambos Z, Dimitra R, Grigorios S, Konstantinos V, Konstantinos S, Mihalis A, et al. Teratoma occupying the left hemithorax. *World Journal of Surgical Oncology* 2005, 3:76.
3. Oldham KT, Colombani PM, Foglia RP. *Surgery of Infants and Children: Scientific Principles and Practice.* Lippincott – Raven 1997. Philadelphia. New York..
4. Nichols CR. Mediastinal germ cell tumors: clinical features and biologic correlates. *Chest* 1991, 99 (2): 472-479.
5. Zisis C, Rontogianni D, Stratakos G, Voutetakis K, Skevis K, Argiriou M, Bellenis I: Teratoma occupying the left hemithorax. *World J SurgOncol* 2005, 3:76.
6. Takeda S, Miyoshi S, Ohta M, Minami M, Masaoka A, Matsuda H. Primary germ cell tumors in the mediastinum: a 50-year experience at a single Japanese institution. *Cancer* 2003; 97: 367-376.
7. Parambil JG, Gersh BJ, Knight MZ, Ryu JH. Bronchogenic cyst causing atrial fibrillation by impinging the right inferior pulmonary vein. *Am J Med Sci* 2006, 331: 336-338.
8. Franco S, Fabio D. Giant mediastinal mature teratoma with increased exocrine pancreatic activity presenting in a young woman: a case report. *Journal of Medical Case Reports* 2011, 5:238.
9. Morgan DE, Sanders C, McElvein RB, Nath H, Alexander CB. Intrapulmonary teratoma: a case report and review of the literature. *Journal of Thoracic Imaging* 1992, 7(3): 70–77.
10. Drevelegas A, Palladas P, Scordalaki A: Mediastinal germ cell tumors: a radiologic-pathologic review. *EurRadiol* 2001, 11:1925-1932.
11. Cheng YJ, Huang MF, Tsai KB: Video-assisted thoracoscopic management of an anterior mediastinal teratoma: report of a case. *Surg Today* 2000, 30:1019-1021.