
Management of Unerupted Anterior Teeth: An Audit of Treatment Outcomes***Ifesanya JU, *Temisanren OT, **Aladelusi TO, **Olusanya AA**

*Department of Child Oral Health, College of Medicine, University of Ibadan, Ibadan, Nigeria

**Department of Oral and Maxillofacial Surgery, College of Medicine, University of Ibadan,
Ibadan, Nigeria**Correspondence:** Ifesanya JU**E-mail:** joyifesanya@yahoo.co.uk

Abstract

Introduction: Anterior teeth are valuable for aesthetics, speech and mastication. Their absence, impaction, and/or delayed eruption create significant distress often leading to early presentation to the dental office. This study presents an audit of the management of impacted anterior teeth that presented at a tertiary level dental clinic. The periodontal outcomes of the aligned teeth were also reported.

Methods: This is an observational study spanning a nine-year period. Demographic data, clinical presentation, as well as post alignment dental and periodontal status of the impacted teeth were assessed. Data were analysed using the Statistical Package for Social Sciences (SPSS) version 26. Fisher's exact test and paired samples T-test were used for categorical and continuous variables respectively. Significance was set at $P < 0.05$.

Results: Twenty-eight (1.76%) cases presented with failed eruption of 32 anterior teeth were observed during the period under review. Eight patients were treated by extraction, orthodontic treatment, and space closure or prosthetic replacement, with a mean treatment time of 2.83 ± 2.66 years. Thirteen patients completed treatment by orthodontic alignment with mean alignment time of 1.4 ± 1.5 years and treatment time of 3.6 ± 2.5 years. Average loss of root length observed was 1.5mm. There was significant difference in the post-operative root length of aligned teeth compared to their normal antimeres ($p < 0.005$).

Conclusion: Patients with impacted anterior teeth presented later than was beneficial for spontaneous alignment of their teeth. The average 1.5mm loss of root length observed was not detrimental to the anatomical retention or function of the aligned teeth. There is need for more enlightenment with regards to early presentation for dental problems to avoid expensive and time-consuming treatments.

Keywords: central incisors, canines, impaction, management, outcomes

Introduction

The anterior teeth, consisting of the incisors and canine bilaterally, are often referred to as “the social six”. These are the most visible teeth in the oral cavity and are vitally important for speech and aesthetics, as well as mastication.^{1, 2} The absence, impaction, and/or delayed eruption of these teeth create significant aesthetic and psycho-social distress both to the individual as well as their care givers, and thus give rise to early visits to the dental clinics.²⁻⁵

The canines are reported to be the most prevalent impacted teeth in the anterior region, occurring in 2.0-6.0% of the global population,^{4, 6-10} closely followed by the central incisors which are impacted in 0.06-3.00% of global population.^{2, 4, 8, 10-13} A previous Nigerian study reported that 1.7% of their clinic attendants presented with anterior teeth impaction (1.3% central and 0.4% lateral incisors) in a two year review.¹⁴ Impacted central incisors are the earliest to be detected because of their early eruption time.^{6, 8, 15} Impaction of lateral incisors are however rare.³ While canine impaction appears to be more prevalent among females,^{7, 9, 16, 17} central incisor impactions appear to have a higher male prevalence,³ although absence of gender predilection has also been reported.¹³ Unilateral impactions are more prevalent than bilateral^{3, 7, 17} and maxillary impactions more common than mandibular.^{16, 17}

Tooth impaction is caused by supernumerary teeth or odontoma, trauma which causes crown/root dilaceration or displacement of the tooth bud. Impaction may also be caused by soft

or fibrous tissue interference as well as odontogenic tumours and cyst.^{2, 4, 12, 18-20}

The treatment of impacted teeth includes the extraction of obstructing structure for spontaneous realignment, if the condition is detected early. Extraction-replantation or auto-transplantation of the tooth with endodontic treatment, definitive extraction with prosthetic replacement, or surgical exposure for orthodontic alignment are other treatment options.^{2, 5, 6, 21} The last treatment can be achieved using the open or closed flap traction technique,¹⁹ with the latter reported to give clinical outcome similar to that obtained during natural eruption.^{6, 22} The choice of treatment is determined by various factors such as the age and stage of dental development of the patient, the specific tooth, depth of impaction, orientation or lie of the tooth, space availability, patient’s expectation and financial capability, as well as the expertise of the orthodontist.^{6, 19, 23}

Possible negative outcomes of orthodontic treatment of such impacted teeth include root shortening, increased crevicular depth, abnormal gingival contour, loss of keratinized gingiva and/or clinical attachment, increased clinical crown length, root exposure, and in extreme cases, loss of tooth vitality.^{7, 12, 18, 19, 23} Considering the cost and time implication of orthodontic alignment of impacted teeth, these must be thoroughly discussed with the patient and steps must be taken to avoid them.

This study presents an audit of patients treated for the impaction of anterior teeth and the post

alignment periodontal outcomes as experienced in a tertiary level orthodontic clinic in South-Western Nigeria.

Methods

This is a nine-year retrospective observational study of dental outpatients. Ethical approval for this study was sought and obtained from the Institutional Review Board (UI/EC/16/0177). The case notes of all patients who presented with unerupted anterior teeth between the year 2008 and 2017 were retrieved. Demographic data as well as clinical presentation of the teeth such as type of impacted tooth, side of impaction, arch, and number of impacted teeth were obtained from patients' case notes. The orientations of the teeth were obtained from pre-treatment panoramic radiographs, while root lengths were obtained from post-treatment periapical radiographs using a digital caliper. Gingival sulcus depth was measured using the William's periodontal probe and width of the keratinized gingiva was also assessed using the digital caliper at post-treatment stage for current patients and at the annual post orthodontic recall stage for patients who had previously been discharged.

Delayed eruption of a tooth was diagnosed when the contralateral tooth had erupted 12 months prior despite radiographic evidence of its presence, and/or if the patient was at least a year older than the upper limit of the expected eruption date for that tooth. Patients were evaluated by both the orthodontists and the oral and maxillofacial surgeons at pre-treatment stage. After surgical exposure or extraction of

the impacted tooth, patients were treated according to orthodontic protocol. After orthodontic alignment of the impacted tooth was achieved, its clinical parameters and periodontium were assessed and compared with its antimere on the same arch. If the patient presented with bilateral affectation, globally accepted normal crown and root measurements for the tooth²⁸ were used for comparative analysis.

Data was analysed using the Statistical Package for Social Sciences (SPSS) version 26. Descriptive summary was presented in tables. The Fisher's exact test and paired samples T-test were used for categorical and continuous variables respectively. Significance was set at $P < 0.05$.

Results

A total of 28 (1.76%) cases presenting with failed eruption of thirty-two anterior teeth were found, out of the 1594 patients who presented during the period under review. The age at presentation was skewed to the left (Shapiro-Wilk test $p < 0.0001$) with a median of 12 years (IQR 11-21). Median age for patients who presented with central incisor impaction was 12 years (IQR 11-12 years: Shapiro-Wilk test $p < 0.0001$) while the mean age for those who presented with canine impaction was 18.69 ± 5.95 years (Shapiro-Wilk test $p = 0.18$). Ten (35.7%) patients were males and eighteen (64.3%) were females. Twenty-seven (96.4%) of the patients were skeletal pattern I while one (3.6%) was skeletal pattern III. Four (14.3%) patients presented with bilaterally-impacted

teeth while 24 (85.7%) had unilaterally tooth associated with the impacted teeth are as impactions. The side and arch location, teeth presented in table 1. All bilateral impactions and affected, as well as the type of anomalies mandibular impactions involved the canines.

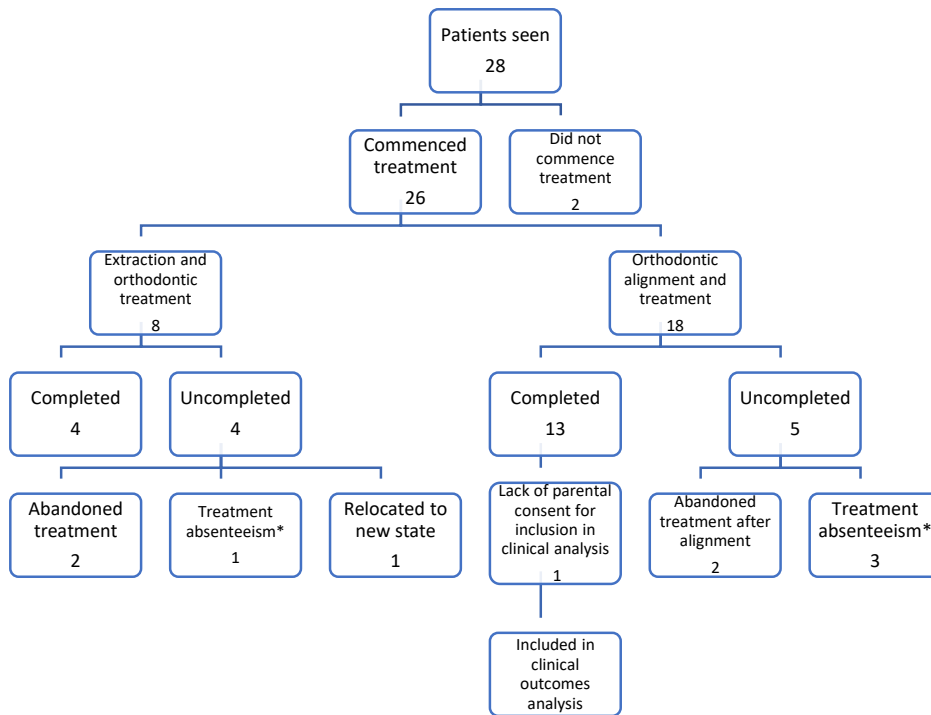
Table 1: Characteristics of impacted anterior teeth

Variable		Frequency by persons(%)	Frequency by tooth(%)
Jaw affected	Maxilla	25(89.3)	29(90.6)
	Mandible	3(10.7)	3(9.4)
	Total	28(100.0)	32(100.0)
Side affected	Left	11(39.3)	15(46.9)
	Right	13(46.4)	17(53.1)
	Both	4(14.3)	
	Total	28(100.0)	32(100.0)
Teeth affected	Central incisor	15(53.6)	15(46.9)
	Canines	13(46.4)	17(53.1)
	Total	28(100.0)	32(100.0)
Orientation	vertical	21(75.0)	21(65.6)
	Horizontal	4(14.3)	6(18.8)
	Diagonal	2(7.1)	4(12.5)
	Inverted	1(3.6)	1(3.1)
	Total	28(100.0)	32(100.0)
Associated anomaly	Retained deciduous alone	7(25.0)	8(25.0)
	Odontoma alone	3(10.7)	3(9.4)
	Combination of odontoma and retained deciduous	4(14.3)	5(15.6)
	Supplemental lateral	1(3.6)	1(3.1)
	Trauma to deciduous	1(3.6)	1(3.1)
	Retained deciduous, odontoma and other anomalies (supplemental and dilaceration)	2(7.1)	4(12.5)
	Mesiodens	2(7.1)	2(6.3)
	No obvious anomaly present	8(28.6)	8(25.0)
	Total	28(100.0)	32(100.0)

Impaction of canines were more prevalent among the females (55.6%), while that of central incisors were higher among the males (70.0%). However, this was not statistically significant (p=0.25). Eighteen (69.2%) patients were treated by orthodontic traction and alignment using the

closed flap technique while eight (30.8%) were treated by extraction of the impacted teeth followed by orthodontic treatment with prosthetic replacement of the extracted tooth or space closure. Figure 1 presents the treatment flow chart for all the patients seen.

Figure 1: Flow chart of patients with unerupted anterior teeth seen at the clinic



*Treatment absentees are still in treatment but default often for appointments

Patients treated by extraction and orthodontic treatment with space closure or prosthetic replacement

Eight patients were in this category. One (12.5%) patient had temporary prosthetic replacement, using the extracted natural tooth as a pontic on a fibre reinforced resin bridge, while seven (87.5%) had extraction followed by space closure. Only four (50%) patients completed treatment. The mean treatment time was 2.83 ± 2.66 years.

Patients treated by orthodontic alignment

Eighteen patients were in this category, 17 (94.4%) of whom had been successfully treated to the alignment stage. Four (23.5%) of these 17 who did not complete or had not completed the full orthodontic treatment for various reasons (see Figure 1) as well as one whose parent did not present for the extra post treatment periapical radiograph were excluded from the clinical outcome assessment.

Clinical outcomes assessment

The mean alignment time was 1.4 ± 1.5 years and for the 13 who completed treatment, the mean treatment time was 3.6 ± 2.5 years. There was no loss of vitality of any tooth. There was no

significant difference in the outcome variables accessed between the orthodontically aligned teeth and their normal counterparts, except the post-operative root length ($p < 0.005$). This is presented in table 2.

Table 2: Comparison of clinical characteristics of orthodontically aligned teeth and their normal antimeres

Variable	Pairings for analysis	N	Mean \pm S.D (mm)	Mean difference \pm S.D	P-value	Confidence interval	
						lower	upper
Crevicular depth	Normal side	13	2.08 \pm 0.67	0.19 \pm 0.31	0.55	-0.49	0.87
	Affected side	13	2.27 \pm 0.86				
Length of keratinized gingiva	Normal side	12	6.12 \pm 1.29	-0.39 \pm 0.77	0.11	-0.88	0.10
	Affected side	12	5.73 \pm 1.49				
Crown length	Normal side	13	9.94 \pm 1.29	0.15 \pm 0.79	0.51	-0.33	0.63
	affected side	13	10.09 \pm 1.01				
Root length	Normal side	13	15.07 \pm 1.44	1.65 \pm 1.69	0.004	0.63	2.68
	Affected side	13	13.42 \pm 2.09				

S-D Standard deviation

N-Number of pairs

Discussion

The prevalence of unerupted anterior teeth in this study is similar to that reported for hospital patients in a previous studies.^{14, 24} The age at first diagnosis for children with impacted anterior teeth in this environment is however significantly higher than the globally reported age. Impacted central incisors are typically first diagnosed at age 7-9years²⁵ while canines are first diagnosed at age 10-12 and best treated before age 20 years.²⁶ This highlights the problems of poor enlightenment as well as low utilisation of dental services in our environment

as most parents and caregivers were not aware that treatment was available for unerupted teeth.

The late presentation may also be responsible for the prolonged treatment time observed in this study, as the teeth were observed to have advanced root development with an attendant loss of eruption potential. Early presentation has been linked with successful spontaneous alignment without the need for orthodontic intervention in many cases, once space within the arch is adequate.^{25, 26} This fact is also buttressed by an earlier study of orthodontic patients treated with fixed appliances in the same

tertiary centre in which a treatment time of 2.02 ± 1.04 years was reported. This is a significantly lower treatment time than for these patients with dental impactions.²⁷

A major limitation associable to lack of dental enlightenment observed in this audit is the abandonment of treatment observed in approximately one in every seven (1:7 or 14.29%) patients treated for dental impaction at the clinic.

Overall, the outcome of treatment was successful and acceptable to all the patients who completed their treatment. Though the clinical crowns of the impacted teeth were longer than on the normal side and the keratinized gingiva was also shorter as previous studies have reported, statistically significant differences were not found.^{7, 12, 18, 19, 23} The statistically significant shortening of root length observed here is a well-documented outcome common to general orthodontic treatment and more so for alignment of impacted teeth.^{7, 12, 18, 19, 23} However, the average 1.5mm loss of apical root structure observed was not detrimental to the anatomical retention or function of the aligned teeth of our patients.

Although the gender prevalence for impacted canines and central incisors in our patient population is similar to the globally reported trend,^{3, 7, 9, 16} it was not a significant finding in this study. This may be because this population of patients presented an almost equal proportion of canine and central incisors that are impacted with a slightly higher number of central incisors,

compared to a global trend that has always significantly favoured canine prevalence.⁶⁻⁸

While the clinical value of the gender prevalence of impacted anterior teeth here is irrelevant, the overall higher central incisor presentation may underscore the higher aesthetic value placed on the central incisor over canines.

Conclusion

There is a relatively low prevalence of impacted anterior teeth among patients seen at the clinic. Patients presented later than is beneficial for spontaneous alignment of their teeth and treatment abandonment as a problem is highlighted. There is need for more oral health enlightenment with regards to early presentation for dental problems to avoid expensive and time-consuming treatments.

References

1. Huber KL, Suri L, Taneja P. Eruption Disturbances of the Maxillary Incisors: A Literature Review. *J Clin Pediatr Dent.* 2008;32(3):221-230.
2. Tanki JZ, Naqash TA, Gupta A, Singh R, Jamwal A. Impacted maxillary incisors: Causes, Diagnosis and Management. *J Dent Med Sci.* 2013;5(2):41-45.
3. Bartolo A, Camilleri A, Camilleri S. Unerupted incisors—characteristic features and associated anomalies. *Eur J Orthod.* 2010;32:297-301.
4. Potnis A, Panchasara C, Shetty A, Nayak UK. Unveiling the impacted incisor. *Indian J Multidiscip Dent.* 2015;5(1):27-30.

5. Singh H, Kapoor P, Sharma P, Dudeja P, Maurya R, Thakkar S. Interdisciplinary management of an impacted dilacerated maxillary central incisor. *Dental Press J Orthod.* 2018;23(3):37-46.
6. Almandaeey AAQ. Surgical exposure, bonding and orthodontic traction of impacted maxillary anterior teeth: a retrospective study., in *Dentistry.* 2007, University of Hong Kong.: Pokfulam, Hong Kong.
7. Manne R, Gandikota C, Juvvadi SR, Rama HRM, Anche S. Impacted canines: Etiology, diagnosis, and orthodontic management. *J Pharm Bioallied Sci.* 2012;4:s234-238.
8. Ghosh A, Dhar S, Kar S. Orthodontic management of unfavorably impacted maxillary central incisor (sickle incisor). *APOS Trends in Orthodontics.* 2014;4:133-138.
9. Haralur SB, Shahrani S, Al-Alqahtani F, Nusair Y, Alshammari O, Alshenqety O. Incidence of impacted maxillary canine teeth in Saudi Arabian subpopulation at central Saudi Arabian region. *Ann Trop Med Public Health.* 2017;0(3):558–562.
10. Mengal N, Kahooja KK, Ahmed M. Surgical Uncovering and Orthodontic Positioning of Unerupted Maxillary Right Canine and Left Central Incisor. *Journal of the College of Physicians and Surgeons Pakistan.* 2018;28:s133-134.
11. Pavoni C, Mucedero M, Laganà G, Paoloni V, Cozza P. Impacted maxillary incisors: diagnosis and predictive measurements. *Annali di Stomatologia.* 2012;3(3):100-105.
12. Khera AK, Rohilla A, Tandon P, Singh GP. Orthodontic management of impacted central incisor: A clinical challenge. *J Ind Orthod Soc.* 2017;51:46-50. <https://doi.org/10.4103/0301-5742.199249>
13. Kafle D, Shrestha S, Acharya N, Agarwal A. Prevalence of Maxillary Central Incisor Impaction and Supernumerary Teeth among Nepalese Orthodontic Patients. *Orthod J Nepal.* 2015;5(2):14-16.
14. Sanu OO, Temisanren OT. A review of 39 cases of unerupted maxillary incisors. *Nig J Clin Practice.* 2002;6(1):60-64.
15. Thosar NR, Vibhute P. Surgical and orthodontic treatment of an impacted permanent central incisor : A case report. *J Indian Soc Pedod Prev Dent.* 2006;24:100–103.
16. Sharmila R. Incidence of Impacted Canine Using Orthopantomogram. *J Pharm Sci & Res.* 2016;8(8):912-922.
17. Al-Ayed FA, Al-Wehiby SM, Ettesh A. The prevalence of impacted permanent canines in Saudi subpopulation: original research. *J Am Sci.* 2019;15(1):29–33.
18. Avinash K, Aieshya F. Impacted maxillary central incisor and over-retained deciduous central incisor: Combined surgical and orthodontic

- treatment - A case report. *J. Int Oral Health*. 2011;3(3):25-30.
19. Subbiah Kannan PK, Palanisamy SK, Kumar TS. A case of impacted maxillary central incisor and its management. *J Pharm Bioallied Sci*. 2012;4:s174-176.
20. Kumar R, Thomas AM. Orthodontic Alignment of an Impacted Maxillary Incisor : A Case Report. *Int J Sci Study*. 2015;2(10):136-138.
21. Fujita Y, Takahashil T, Maki K. Orthodontic treatment for an unerupted and severely rotated maxillary central incisor. A case report. *Eur J. Paed Dent*. 2008;9(1):43-47.
22. Vermette ME, Kokich VG, Kennedy DB. Uncovering labially impacted teeth: apically positioned flap and closed eruption techniques. *The Angle Orthodontist*. 1995;65(1):23-34.
23. Kalaskar RR, Kalaskar AR. Multidisciplinary management of impacted central incisors due to supernumerary teeth and an associated dentigerous cyst. *Contemp Clin Dent*. 2011;2(1):53-58.
24. Tan C, Ekambaram M, Yiu CKY. Prevalence, characteristic features, and complications associated with the occurrence of unerupted permanent incisors. *PLOS ONE*. 2018;13(6):e0199501.
25. Seehra J, Yaqoob O, Patel S, O'Neill J, Bryant C, Noar J, *et al*. National clinical guidelines for the management of unerupted maxillary incisors in children. *British Dent. J*. 2018;224(10):779-785.
26. Caminiti MF, Sandor GK, Giambattistini C, Tompson B. Outcomes of the surgical exposure, bonding and eruption of 82 impacted maxillary canines. *J Can Dent Assoc*. 1998;64(8):572-4, 576-9.
27. Temisanren OT, Ifesanya JU, Olatunji AB. Compliance to review attendance among orthodontic patients attending a tertiary level health care centre. *Nig Dent J*. 2015;23(1):130-134.
28. Nelson SJ. *The permanent Canines. Wheeler's Dental Anatomy, Physiology and Occlusion*. Elsevier Saunders: St. Louis, Missouri. 2015;123-129.