

## Reduction of manually irreducible TMJ dislocation with Forceps Traction:

### Case report in a 60-year-old woman

\*Ogundipe OK, \*Ugwu EI, \*Ajayi OS, \*Ojo OO

\*Department of Oral and Maxillofacial Surgery, Obafemi Awolowo University Teaching Hospitals  
Complex, Ile-Ife, Nigeria

**Correspondence:** Ugwu EI,

**E-mail:** ethelbdon2004@yahoo.com

#### *Abstract*

*Chronic protracted TMJ dislocation refers to a condition in which the joint is displaced from its articulation and fixated in that position (open locked) without reduction. The Hippocratic Manoeuvre is usually unsuccessful with a high failure rate, making treatment of this condition very challenging. This article reports a case of TMJ dislocation not amenable to traditional closed reduction method but which was successfully treated using direct application of reduction forceps on the angle of the mandible. The technical aspects of the procedure and post-operative management were also highlighted.*

#### **Introduction**

Chronic Temporomandibular Joint (TMJ) dislocation results from an untreated or inadequately treated acute dislocation. Several terminologies such as ‘permanent’, ‘long standing’, ‘prolonged’, ‘protracted’, and ‘persistent’ are used in scientific literature to describe this condition characterised by the displacement of the mandibular condyle out of the glenoid fossa for more than one month. Chronic TMJ dislocation is relatively uncommon, occurring in 7% of the general population and accounts for 3% of all articular body luxations.<sup>1</sup> Chronic protracted TMJ dislocation is a highly distressing condition for a

patient. It is also challenging to treat as it worsens with time due to the continuing spasm of the masticatory muscles and progressive fibrosis, adhesions, and consolidation in and around the dislocated joint.<sup>2</sup>

Closed reduction (conservative) techniques are usually the first line of treatment in which case the surgeon’s hands exert force on the molar teeth (Hippocratic method), the chin (Wrist Pivot Method), and/or ascending ramus (External Approach).<sup>3</sup> However, chronic protracted TMJ dislocation may not be amenable to these methods. Open reduction (surgical) is used when conservative methods have failed, but

it is associated with some complications due to its invasive nature.<sup>2, 4</sup> Although no definite treatment guidelines exist in the literature,<sup>5</sup> avoiding these complications is imperative, hence, less invasive but equally effective treatment methods are preferable. Akinbami<sup>6</sup> concluded that “more complex and invasive method of treatment may not necessarily offer the best option and outcome of treatment, therefore conservative approaches should be exhausted and utilised appropriately before adopting the more invasive surgical techniques.”

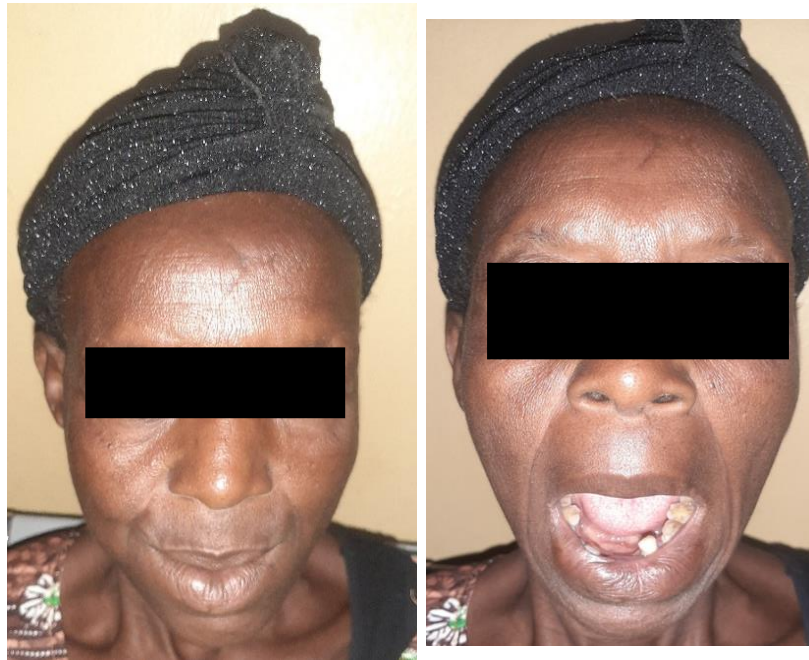This article presents a case of a 60-year-old woman with bilateral anterior chronic protracted TMJ dislocation following excessive yawning

treated with reduction forceps. The technical aspects of the procedure and post-operative management were also highlighted.

### Case presentation

A 60-year-old woman presented in the Oral and Maxillofacial Surgery clinic of Obafemi Awolowo University Teaching Hospitals Complex, Ile-Ife, with a two-month history of an inability to close her mouth following excessive yawning. There was no history of trauma. She is a known epileptic on carbamazepine medication.

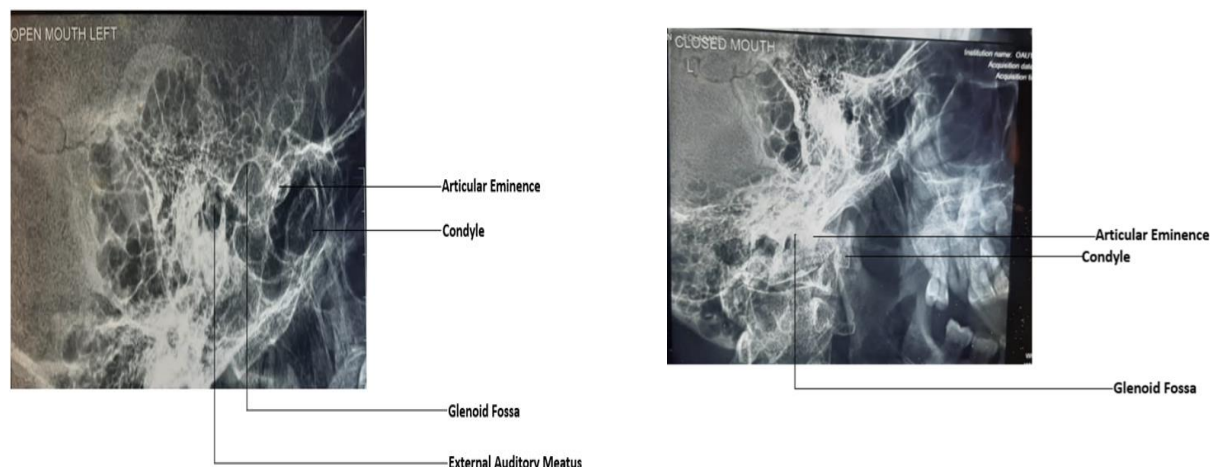
On examination, her mouth was open, and there was significant saliva drooling. Her face appeared unusually longer because she was in a class III skeletal relationship (figure 1).



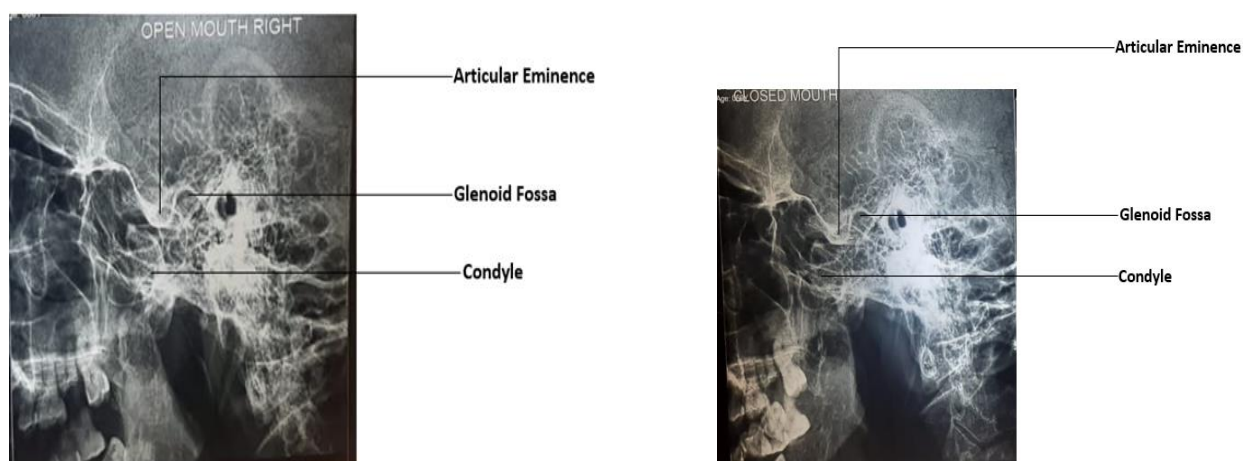
**Figure 1:** Pre-operative photographs (closed and open position) with protruded mandible

Bilaterally, there were depressions around her pre-auricular area associated with mild tenderness on gentle palpation. Trans-cranial

oblique views of the TMJs were taken and depicted bilateral anterior dislocations of the patient’s TMJs (figures 2a & b).



**Figure 2a:** Transcranio-oblique view of Left TMJ (open and closed positions)

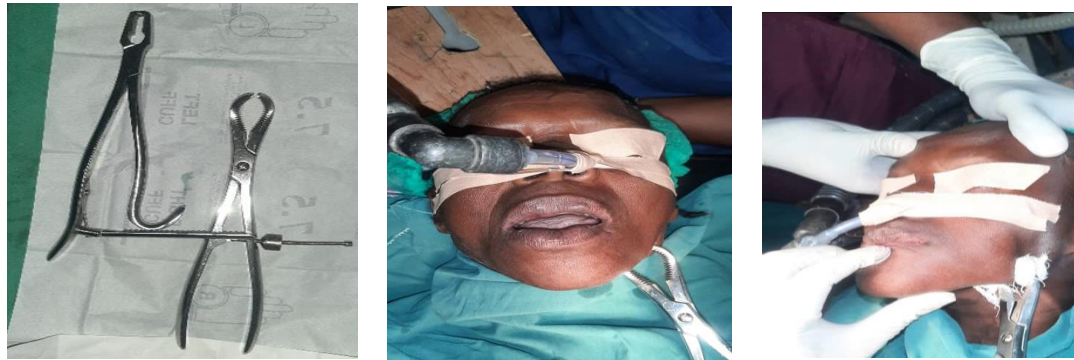


**Figure 2b:** Transcranio-oblique view of Right TMJ (open and closed position)

Several attempts were made in the clinic to manually reduce the dislocated head of condyles using Hippocratic manoeuvre to no avail. The patient was later taken to the theatre, and the reduction was eventually done under general anaesthesia.

She was placed supine on the operating table; GA was administered through nasal-endotracheal intubation. Induction and maintenance were achieved with the following agents, IV propofol, halothane, and IV suxamethonium.

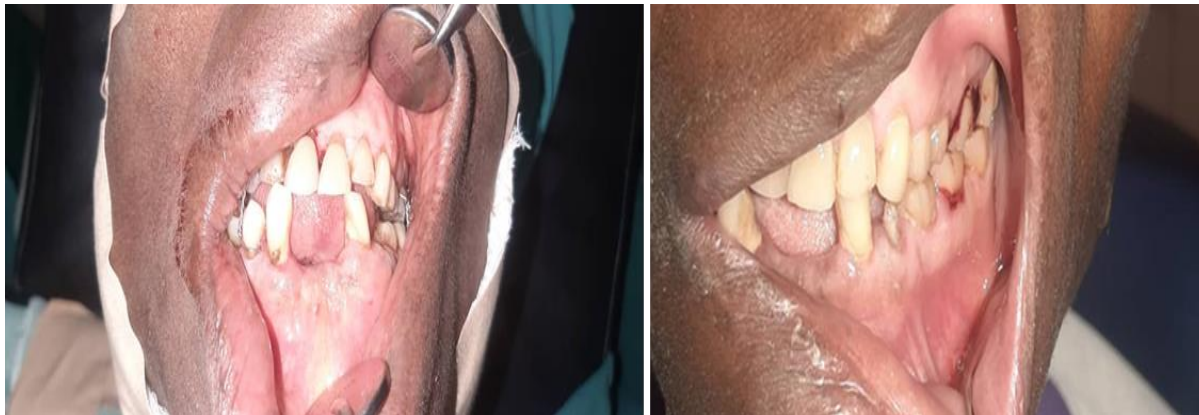Pancuronium, a long-acting muscle relaxant, was administered to achieve muscle paralysis. A period of about five minutes was observed to allow for muscle relaxation to occur. Efforts were made to manually reduce the dislocated condyles which proved abortive. Successful reduction was eventually done using ratcheted mandibular bone-holding forceps (figure 3) on either side of the mandible through a stab incision.



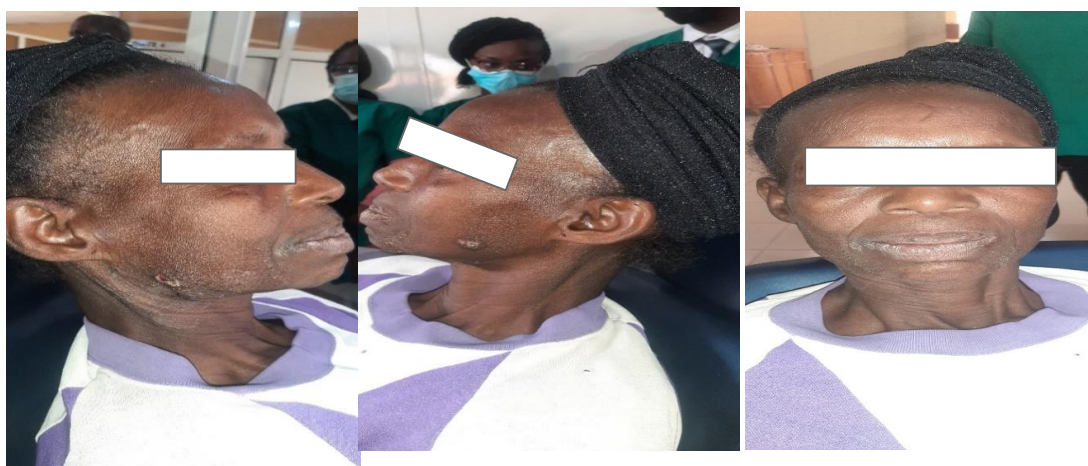**Figure 3:** ratcheted bone-holding forceps and intra-operative photographs

Direct force was applied through the forceps onto the angle of mandible to pull the condyles in a downward and backward direction (figure 3) to reposition the head of the condyles. She was

thereafter placed on inter-maxillary fixation for 2 weeks. She has had several reviews post reduction and the outcome has been satisfactory (figure 4).



**Figure 4:** intra-op reduction with IMF, 4b: post op without IMF



The stab wounds healed satisfactorily and no complication was recorded (figure 5).

**Figure 5:** Postoperative photographs

## Discussion

The present case illustrates a chronic bilateral TMJ dislocation not amenable to manual reduction under local and general anesthesia. The current classification of chronic TMJ dislocation solely based on the duration fails to distinguish the present condition from that of chronic dislocation which can be manually reduced. Notably, five out of 29 cases of chronic TMJ dislocation reported by Ugboko et al<sup>7</sup> were successfully treated with manual reduction under either local or general anesthesia. Chronic TMJ dislocation not amenable to manual reduction under LA and GA poses unique treatment challenges. We, therefore, propose the term ‘manually irreducible’ TMJ dislocation to distinguish this condition from other chronic TMJ dislocations.

Delayed presentation is typical of this condition. However, the reason for late presentation in the present case may result from a lack of access to medical facilities or wrong beliefs about orthodox medical practice.

Neurological illnesses such as epilepsy, Parkinson disease, and the likes have been described as predisposing factors for the development and maintenance of long-term TMJ dislocation.<sup>8, 9</sup> The history of epilepsy and carbamazepine therapy in the current case is a possible predisposing factor. However, the dislocation was caused by excessive yawning. A multicentre study in Nigeria reported yawning as the most common cause of dislocation among a group of 96 patients.<sup>7</sup>

Spasm of the masticatory muscles (masseter, temporalis and pterygoid muscles), shortening of lateral pterygoid muscles, and the associated soft tissue changes such as fibrosis or scarring<sup>10</sup> have been reported as the likely causes of failure of manual reduction. The formation of a nearthrosis (false joint) anterior to the articular eminence in prolonged TMJ dislocation is an additional factor. The longer the TMJ dislocation remains untreated, the more complex procedures may be needed to reduce it.<sup>2</sup> The aetiology of the dislocation (traumatic or atraumatic) is another important prognostic factor, with traumatic dislocation being more difficult to reduce due to hemarthrosis and fibrosis.<sup>11</sup> The current case report involves significant anterior dislocation relative to the articular eminence which may also account for the difficulty with reduction. Arguably, the curvature of the articular eminence and its distance to the dislocated condyles are additional prognostic factors.

We considered other closed reduction techniques, such as acrylic block and elastic traction.<sup>12</sup> However, we decided against them considering the state of the patient’s dentition, the duration of the procedure, and the likely failure rate. The protruded mandible which the patient presented with is another reason why acrylic block was not used.

The first line of treatment for manually irreducible TMJ dislocation is indirect traction on different sites of the mandible.<sup>2</sup> Elastic indirect traction through inter-maxillary fixation screws or dentures and semi-rigid indirect

traction through transosseous wires at the angle region of the mandible or the sigmoid notch have been used with poor results.<sup>11</sup>

Rigid forceps traction through the angle of the mandible with ratcheted mandibular reduction forceps is simple and less invasive, avoiding the usual complications of open surgical procedures. The technique is also useful in setting back the protruded mandible and correct occlusion. In the present case, general anaesthesia with endotracheal intubation in the day case theatre was preferred because of additional muscle relaxation afforded.

The technique affords a direct application of force via the angle of the mandible in a downward and backward direction, offering a mechanical advantage. Other techniques<sup>11, 13</sup> in which the force is applied on the mandible through a bone hook placed in the sigmoid notch and traction with wires through holes drilled in the angle of the mandible lack this mechanical advantage because the vector of forces are not rigidly applied to the mandible.

Potential complications with forceps traction may include iatrogenic damage to associated soft and hard tissues. Therefore, great care should be taken that the ratchet is safely locked on the angle of the mandible before the manipulation to avoid slipping during traction which may lacerate the soft tissues. The stab wounds usually heal uneventfully without the need for sutures. Intra operative inter-maxillary fixation IMF is usually required with this technique to restore and maintain centric occlusion.

The difficulty index is related to the curvature and height of the articular eminence and its distance to the dislocated condyle, and should be used for patient selection.

### Conclusion

Closed reduction of manually irreducible TMJ dislocation using ratcheted bone forceps traction is a safe and effective method, avoiding the complications associated with open surgery and unpredictability of acrylic block with elastic traction.

### References

1. Balaji S, Balaji P. Surgical management of chronic temporomandibular joint dislocations. *Indian Journal of Dental Research* 2018;29(4):455.
2. Huang I CC-M, Kao Y-H, Wu C-W Management of long-standing mandibular dislocation. *Int J Oral Maxillofac Surg* 2011;40(8):810–14.
3. Jeyaraj P, Chakranarayan A. A Conservative Surgical Approach in the Management of Longstanding Chronic Protracted Temporomandibular Joint Dislocation: A Case Report and Review of Literature. *J Maxillofac Oral Surg* 2016;15(Suppl 2):361-70.
4. Jeyaraj P. Chronic Recurrent Temporomandibular Joint Dislocation: A Comparison of Various Surgical Treatment Options, and Demonstration of the Versatility and Efficacy of the Dautrey's Procedure. *J Maxillofac Oral Surg* 2018;17(1):95-106.

5. Cuevas Queipo de Llano A, Monje Gil F, Gonzalez García R, Villanueva Alcojol L, Gonzalez Ballester D. Long-Term Dislocation of the Mandible: Is there an Algorithm to Success? Intraoperative Decision and Review of Literature. *J Maxillofac Oral Surg* 2020;19(1):12-16.
6. Akinbami BO. Evaluation of the mechanism and principles of management of temporomandibular joint dislocation. Systematic review of literature and a proposed new classification of temporomandibular joint dislocation. *Head & Face Medicine* 2011;7(1):1-9.
7. Ugboko V I OFO, Ajike S O, Olasoji H O, Adebayo E T. A survey of temporomandibular joint dislocation: aetiology, demographics, risk factors and management in 96 Nigerian cases. . . *Int J Oral Maxillofac Surg*. 2005;6(6):499–502.
8. Kai S KH, Nakayama E: . Clinical symptoms of open lock position of the condyle. Relation to anterior dislocation of the temporomandibular joint. *Oral Surg Oral Med Oral Pathol* 1992;74:143.
9. Marqués-Mateo M, Puche-Torres M, Iglesias-Gimilio ME. Temporomandibular chronic dislocation: The long-standing condition. *Med Oral Patol Oral Cir Bucal* 2016;21(6):e776-e83.
10. Akinbami BO. Evaluation of the mechanism and principles of management of temporomandibular joint dislocation. Systematic review of literature and a proposed new classification of temporomandibular joint dislocation. *Head Face Med* 2011;7:10.
11. Rattan V RS, Sethi A. Midline Mandibulotomy for Reduction of Long-Standing Temporomandibular Joint Dislocation *Craniofacial Trauma Reconstr*. 2013;2:127–32.
12. Pradhan L, Jaisani MR, Sagtani A, Win A. Conservative Management of Chronic TMJ Dislocation: An Old Technique Revived. *J Maxillofac Oral Surg* 2015;14(Suppl 1):267-70.
13. Caminiti MF WS. Review Chronic mandibular dislocation: the role of non-surgical and surgical treatment. *J Can Dent Assoc* , 1998;64(7):484-91.