

Presentation and Management of Dental Fluorosis in a Resource-Limited Facility in North-Central, Nigeria

*Idowu EA, **Ibiyemi O, ***Taiwo OO, ****Afolabi AO

*Faculty of Dental Sciences, University of Jos, Plateau State

**Department of Periodontology & Community Dentistry, University of Ibadan, Nigeria

***Department of Basic Sciences and Research, Intercountry Center for Oral Health for Africa, Jos, Plateau State, Nigeria

****Department of Dental Services, Federal Medical Center, Owo, Ondo State, Nigeria

Correspondence: Taiwo OO

Email: taiwo25@yahoo.co.uk

Abstract

Background: Dental fluorosis is a developmental disturbance characterized by excess fluoride in hard tissues of the teeth. The appearance of teeth affected by dental fluorosis may negatively affect individuals' self-esteem and overall quality of life. Hence, the need for treatment, although there is still debate on the best treatment modalities. The objective of this study was to document the presentation and management of dental fluorosis in a resource limited facility in North-Central Nigeria.

Materials and methods: A cross-sectional hospital-based study conducted among out-patients attending a secondary oral health care facility in Jos, North-Central Nigeria between June 2020 and June 2022. Sociodemographic characteristics were recorded. All patients were examined for presence of dental fluorosis. Dean's Index was used to classify dental fluorosis. Patients with dental fluorosis who consented to the study were treated. Treatment modalities included oral prophylactic treatment, micro-abrasion, and resin infiltration. Data analysis was by the use of Statistical Package for Social Sciences (SPSS) version 23.0. A p -value of < 0.5 was taken as statistically significant.

Results: During the study period, 1201 patients presented with different oral health challenges. Among these, 200 (16.7%) were diagnosed of dental fluorosis. The mean of the patients with dental fluorosis was 14.15 ± 1.91 years. Nearly half, 98 (49.0%), of the patients who presented with dental fluorosis were children, 65 (32.5%) were teenagers, and 37(18.5%) were young adults ($p=0.037$). Among the patients, 123 (61.5%) were females. The moderate type of dental fluorosis 75(37.5%) was the commonest type of dental fluorosis seen. Out of the 200 patients with dental fluorosis, dental caries was

present among 55(37.5%) patients. 185 (92.5%) requested for treatment. 231 intervention procedures were undertaken on different classes of dental fluorosis.

Conclusion: *Dental fluorosis was prevalent among the dental out-patients seen at the study center during the study period. More patients presented with moderate class of dental fluorosis. Presentation was more among children and teenagers below 20 years. More females presented and requested for intervention than males. Resin infiltration was found to be cost effective at this facility.*

Keywords: *Dental fluorosis, management, presentation, Nigeria*

Introduction

Dental fluorosis is a developmental disturbance characterized by excess fluoride in hard tissues of the teeth.¹ It is a common presentation in many oral health care facilities in Nigeria, among all age groups and sexes.^{1,2} Tooth affected by dental fluorosis may present with mottling of enamel, unpleasant appearance, esthetic embarrassment, and may negatively affect individual self-esteem and overall quality of life.^{1,2,3} Other clinical features of dental fluorosis apart from enamel mottling include: white striation, brown discoloration, pitting of enamel, and in severe cases, corroded appearance of teeth.^{1,2,4} While fluoride is needed for healthy teeth development, remineralisation, and dental caries prevention, excess fluoride can become toxic to the body and lead to dental and skeletal fluorosis.^{3,5} Bone and teeth are therefore major markers for fluoride in the body apart from saliva, milk, nails and urine.^{5,6} The pathogenesis of dental fluorosis is due to disturbances in the activities of a specialized cell called ameloblast during enamel formation and mineralization of

organic matrix in tooth development.^{3,7} To prevent dental fluorosis, 0.05 to 0.07mg F/Kg body weight/day intake is recommended.⁴

While prevalence of dental fluorosis varies from country to country, there is still debate on the best treatment modalities. Dental fluorosis has been mostly reported among people in less developed than developed countries,³ due to relative scarcity of treated water consumed by the public in the former. Surface water contains less fluoride concentration (<1.5mg/L) than underground water.^{5,8} Underground water from boreholes and wells, without chemical analysis and treatments, is a major source of drinking water in many communities in Nigeria. Fluoride concentration in drinking water within 0.5-1mg/l benefits the body, but a concentration higher than 1.5 mg/L constitute a risk of dental and skeletal fluorosis.^{5,9} Although the leading cause of fluorosis is a higher concentration of fluoride in drinking water,⁹⁻¹² fluorosis has also been reported in areas where fluoride concentration in drinking water is lower or even within the safety level.⁵ Fluorosis in this situation was

ascribed to high environmental temperature that induced a higher water consumption rate or fluoride from other sources. Other documented sources of fluoride include vegetables, milk, beverages, salt, food, tea, tobacco, and tooth paste.^{1,4,5,11,12} According to United States Environmental Protection Agency, a concentration of 0.7-1.2mg/l fluoride in drinking water is adequate for protection against dental caries and cannot lead to fluorosis.⁵ It has equally been recommended that 0.9-1 part per million of fluoride in public water is adequate.^{3,9}

Dental fluorosis affects all ages; however, higher prevalence has been reported among 15-year-olds and below.^{3,5} Nevertheless, the relationship between dental fluorosis and sex, environmental condition and dental caries is inconclusive.^{3,5} Among teenagers, a prevalence of 72% was reported in India,⁵ 91.9% in Mexico,^{5,13} 91% in Ethiopia,^{5,14} 11.3%¹⁵ and 11.4%¹⁶ in Nigeria. A Nigerian study also reported 47% as proportion of patients attending a tertiary hospital in northeastern part of the country who presented with dental fluorosis.² Fluoride levels are low in most parts of Nigeria, being 0.3 ppm or less in 62% of the LGAs. However, fluoride concentrations were generally higher in the north-central geopolitical zone from all drinking water sources, than the other zones in the country.¹⁷ Nonetheless, the magnitude of dental fluorosis and its management among patients is yet to be fully documented in North-Central Nigeria, hence this study. The objective of this study was to document the presentation and

management of dental fluorosis in a resource limited facility in North-Central Nigeria.

Materials and Methods

This cross-sectional hospital-based study was conducted among out-patients attending a secondary oral health care facility (Our Lady of Apostle Hospital) in Jos, North-Central Nigeria. Our Lady of Apostle Hospital was established in 1943 by the Catholic Mission. It was to serve Plateau and neighboring states. The fluoride level (ppm) of the different water sources in this zone are 0.70 ± 0.62 for water works, 0.41 ± 0.31 for rivers and streams, 0.96 ± 0.81 for shallow wells, 0.67 ± 1.28 for deep wells, 0.68 ± 0.75 for boreholes, and 0.44 ± 0.24 for ponds.¹⁷ The hospital attends to all religious faiths. The Dental clinic component was established in 2016. This clinic is run by a maxillo-facial surgeon and a family dentist. There is one dental health technician, no therapist, no technologist and no laboratory facility.

This study took place between June 2020 and June 2022. In 2021, there were about 720 patients seen in the clinic. Most of them (80.4%) were on social health insurance scheme (National Health Insurance Scheme). The others were out of pocket treatment. Ethical approval was obtained from the Institutional Review Board of Our Lady of Apostle Hospital, the study center. Inclusion criteria for the study were presence of dental fluorosis in oral cavity of patients and their willingness to participate in the study. The detail of the study, especially the treatment modality, was thoroughly explained to

them after which those who were interested in participating signed a written, informed consent form. For pediatric patients, their parents or legal guardians signed the consent form.

Information on sociodemographic characteristics such as age and sex as well as the date of first visit, principal complaint, history of presenting complaint, and initial treatment were recorded. All patients were dentally examined for presence of dental fluorosis by a trained and calibrated examiner. Investigations which included pulp vitality, radiographic and mobility tests, were undertaken. Dean's Index was used to classify dental fluorosis,¹⁸ while DMFT index was used to report the presence of dental caries. All patients who had dental fluorosis and signed the written, informed consent form were treated by only one dentist (E.A) while those who had dental caries were referred to the restorative dentist for treatment.

Materials used for treatment of dental fluorosis included: pumice, polishing rubber cups, Microhybrid Composite Resin and its etchant (Henry Schein, Langen, Germany-2020), gauze, Glass Ionomer cement- (Prevestdent PRO Ltd, Jammu India-2020), Prophylaxis Paste (Bestdent, Milan, Italy-2020), composite polishing burs, oral examination set, caries detection probes, and ultrasonic scaler (Woodpecker, Guangxi, China- 2019).

Routine scaling using ultrasonic scaler (Woodpecker made by Guilin woodpecker, Guangxi, China 2019) was carried out as first line of treatment, and prophylaxis paste without

fluoride content was used for polishing the teeth. Patients that were still not satisfied with the appearance of their teeth after scaling and polishing were recalled 72 hours after for micro abrasion and or resin infiltration. Due to high cost of resin infiltration, attention was paid to teeth that were within the esthetic zone i.e., the anterior teeth and premolars. Consequently, the labial and buccal surfaces of lower/upper anterior teeth and first premolars with moderate and severe dental fluorosis were selected for resin infiltration. Applying the resin infiltration, Manufacturer's instructions (Henry Schein INC. USA) were followed and the labial or buccal surfaces of the selected teeth were acid etched with Natural Elegance Etching gel (Henry Schein INC. USA, 2020) containing phosphoric acid for 2 minutes after isolation with rubber dam. The etched surfaces were rinsed with sterile water for 30 seconds and then dried with air jet. Bonding agent (Henry Schein INC. USA 2020) containing Natural Elegance Universal Bond was applied on etched surfaces and was light cured. Appropriate resin shade (A1 or B3) chosen by each patient was applied on etched surfaces and light cured in layers until there was improvement in the appearance. Excess materials were removed from the interdental surfaces and polishing of the restoration was later done after 24-48 hours. After treatments, patients were followed-up for 3, 6, 12 and 18 months after initial treatments. A digital camera was used by the dentist to document the presentation of dental fluorosis on the teeth before and after treatment.

Data obtained were analyzed using Statistical Package for Social Sciences (IBM SPSS) version 23.0 (SPSS Inc., Chicago, 11, USA). The patients' ages were grouped into 0-9 years (children), 10-20 years (preteen ages and teenagers) and above 20years (adults). Frequencies, percentages, means, and standard deviations were generated. Association between categorical variables were undertaken using chi-square test at *p*-value of < 0.5 test of statistically significant.

Results

During the study period, 1201 patients presented with oral health challenges. Among these patients, 255 complained of teeth discoloration, of which 200 (16.7%) were diagnosed of dental fluorosis using Dean's Index. Statistical power analyses using G*Power 3.1.9.7¹⁹ at an α of 0.05, sample size of 200, medium effect size of 0.3 and a degree of freedom of 3 for χ^2 tests gave the

Power of the study ($1 - \beta$) as 0.959. The mean \pm SD age of the patients with dental fluorosis was 14.15 ± 1.91 years. Table 1 shows that the majority, 98 (49.0%), of the patients who presented with dental fluorosis were children, 65(32.5%) were preteen ages and teenagers and 37(18.5%) were young adults ($p=0.037$).

Among the patients, 123 (61.5%) were females while 77 (38.5%) were males ($p=0.003$). The majority, 13 (65.0%), of patients who presented with questionable dental fluorosis were children while the majority, 20 (50.0%), that presented with severe dental fluorosis were young adults. Except in moderate dental fluorosis, females presented more with questionable 12 (60.0%), mild 40 (61.5%, and severe 34(85.0%) dental fluorosis than males with corresponding values of 4 (40.0%), 25 (38.5%) and 6 (15.0%) respectively.

Table 1: Dental fluorosis presentation among patients by age and sex

Biodata	Classes of dental fluorosis					χ^2	<i>p</i> -value
	Questionable	Mild	Moderate	Severe	Total		
	Freq. (%)	Freq. (%)	Freq. (%)	Freq. (%)	Freq. (%)		
	Freq. (%)						
Age(years)							
Children (0-9)	13(65.0)	35(53.8)	40(53.3)	10(25.0)	98(49.0)	13.433	0.037
Preteen ages and	2(10.0)	10(15.4)	15(20.0)	10(25.0)	37(18.5)		

teenagers
(10-19)

Adults (≥20)	5(25.0)	20(30.8)	20(26.7)	20(50.0)	65(32.5)
-----------------	---------	----------	----------	----------	----------

Sex

Male	8(40.0)	25(38.5)	38(50.7)	6(15.0)	77(38.5)	14.037	0.003
Female	12(60.0)	40(61.5)	37(49.3)	34(85.0)	123(61.5)		

Mean ± SD age = 14.15±1.91 years

Freq. = Frequency

Figure 1 shows that the differences in the presentation of various types of dental fluorosis was statistically significant ($p < 0.05$), with most, 75 (37.5%), patients presenting with moderate types while the least, 20 (10.0%), presented with severe types. There was no patient with very mild type of dental fluorosis.

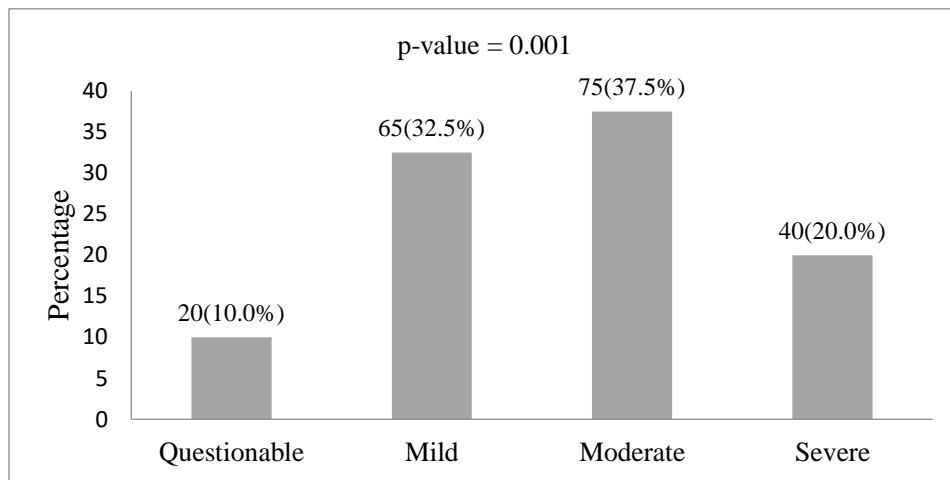


Figure 1: Distribution Dean’s Index of Dental fluorosis among the patients.

Table 2 shows there was no statistically significant relationship between occurrence of dental caries and classes of dental fluorosis among patients ($p = 0.245$). Among the 200 patients with different degree of dental fluorosis, dental caries was present among 55 (37.5%) patients.

Table 2: Relationship between dental caries and different classes of dental fluorosis among patients

	Dental Caries	Dental caries	Total	χ^2	p-value
	Present	Absent			
	Frequency (%)	Frequency (%)	Frequency (%)		
Questionable	8(14.5)	12(8.3)	20(10.0)	4.157	0.245
Mild	20(36.4)	45(31.0)	65(32.5)		
Moderate	15(27.3)	60(41.4)	75(37.5)		
Severe	12(21.8)	28(19.3)	40(20.0)		

Out of the 200 patients with dental fluorosis, 185 requested for treatment and 231 intervention procedures were undertaken on different classes of dental fluorosis. There was a statistically significant relationship between the intervention

procedures and classes of dental fluorosis ($p=0.001$). The different interventions administered to the patients are shown in Table 3.

Table 3: Intervention modalities given to patients with classes of dental fluorosis

	S&P	Micro abrasion	Resin Infiltration	Total	χ^2	p-value
	Freq. (%)	Freq. (%)	Freq. (%)	Freq. (%)		
Questionable	15(8.2)	0(0.0)	0(0.0)	15(6.5)	46.092	0.001
Mild	60(32.4)	2(16.7)	1(2.9)	63(27.3)		
Moderate	70(37.8)	10(83.3)	10(29.4)	90(39.0)		
Severe	40(21.6)	0(0.0)	23(67.7)	63(27.2)		

Freq. = Frequency

Among those who received resin infiltration, 23 (67.7%) presented with severe dental fluorosis

while among those that had micro abrasion, 10 (83.3%) had moderate dental fluorosis.

Figures 2a and 2b show clinical pictures taken before and after treatment of a 29-year-old man who presented with discolorations of 11 and 12 teeth. He was diagnosed with mild fluorosis and

resin infiltration was done on teeth 11 and 12 after scaling and polishing of all the teeth.

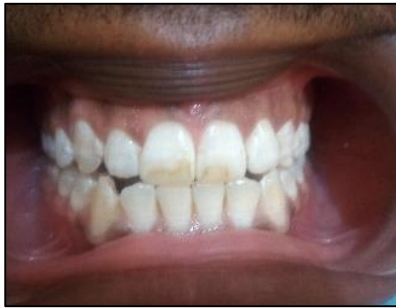

Figure 2a

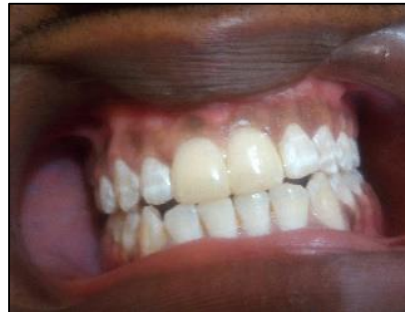

Figure 2b

Figures 3a and 3b show clinical pictures taken before and after treatment of a 36-year-old woman who presented with discolored teeth. The complaint was dissatisfaction in the appearances of her teeth, psychological embarrassment, and loss of confidence while

speaking in the public. Diagnosis of moderate dental fluorosis was made and resin infiltration was undertaken on the upper right and left anteriors and first premolars — 11, 12, 13, 14, 21, 22, 23 and 24 after routine scaling and polishing

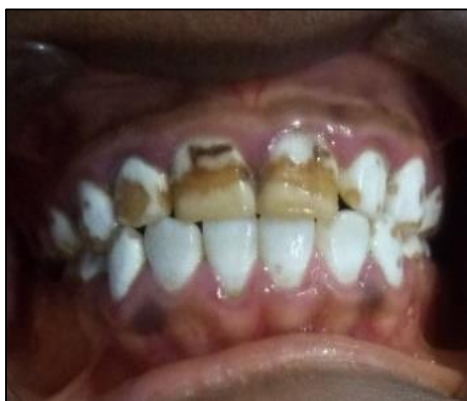

Figure 3a

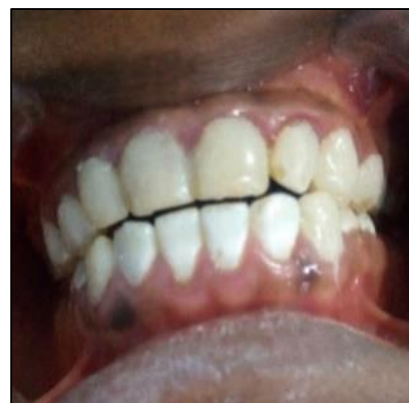

Figure 3b

Figures 4a and 4b show clinical pictures taken before and after intervention procedures (resin infiltration after scaling and polishing) were undertaken on upper and lower anteriors and

first premolars (11,12, 13, 14, 21, 22, 23, 24, 31, 32, 33, 34, 41, 42, 43 and 44) of severely fluorosed teeth of a 22-year-old young lady.

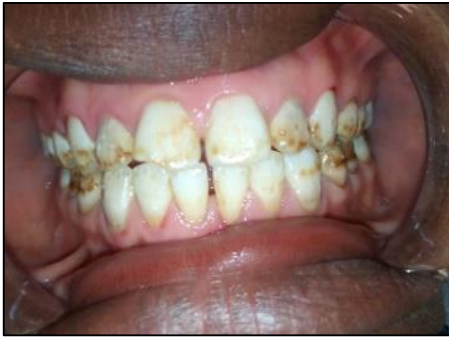

Figure 4a

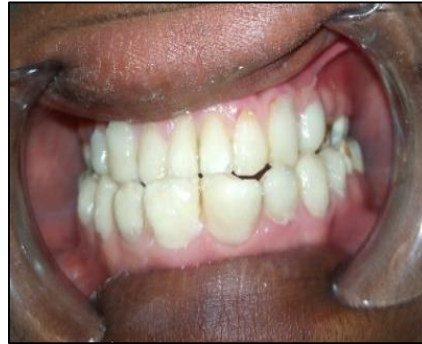

Figure 4b

Figures 5a and 5b show a 17-year-old young man's clinical pictures taken before and after receiving resin infiltration procedures on the

following teeth — 11,12,13,21,22,23,31,32, 33,41,42 and 43, which were severely fluorosed

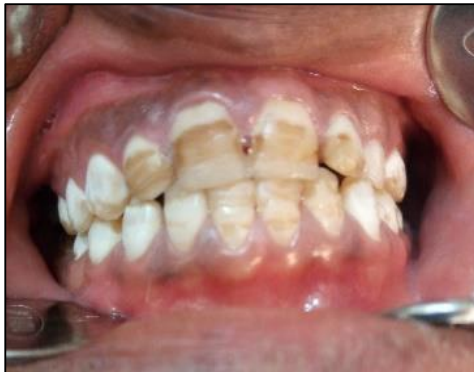

Figure 5a

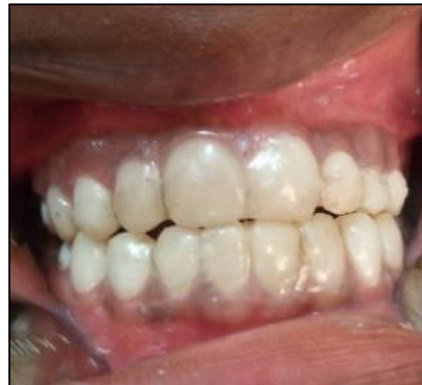

Figure 5b

Figures 6a and 6b show the clinical pictures of a 27-year-old lady who presented with severe dental fluorosis on 11,12, 13, 14, 21, 22, 23, 24, 31, 32, 33, 34, 41, 42, 43 and 44. After scaling and polishing, resin infiltration was done on teeth and glass ionomer cement was applied to

cover the exposed dentine where there was gross loss of enamel structure. The restorations on many of the teeth were found to be intact for 18 months except on teeth 31 and 41 of the 27-year-old lady that were re-treated

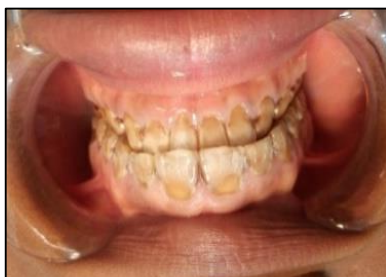

Figure 6a

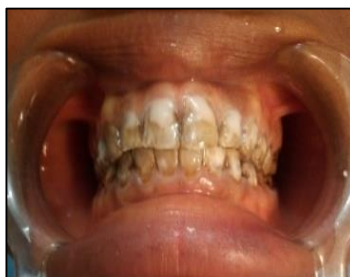

Figure 6b

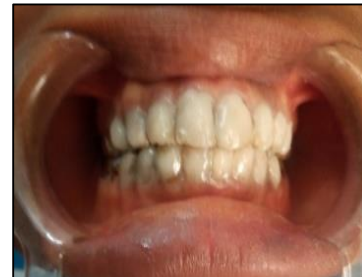

Figure 6c

Discussion

In this present study, the majority of the patients who presented with dental fluorosis were children and adolescents as shown by their mean age of 14.15 years which could be the reason why nearly all studies on dental fluorosis have been conducted with children and adolescents.^{18,20-22} Presentation of dental fluorosis was more among the children and adolescents who were below 20 years compared to adults who were above 20 years. Results from this study on age groups of patients in relationship with dental fluorosis presentation in the clinic conformed to previous reports of dental fluorosis which showed that the condition is more common among children than adults.^{15, 23} The quest for better appearance of teeth among the children and adolescents compared to adults may be the reason why there was a higher proportion of patients who were in the younger age group than those who were in the older age group.

Females presented with more dental fluorosis than males as reported in other previous studies.²⁴⁻²⁷ However, these results were at variance with findings from other studies that reported that dental fluorosis was higher among males than females^{23,28} and no sex preponderance.²⁹ The higher proportion of female patients than male patients presenting with dental fluorosis was also observed in the classes of fluorosis presentation where more females presented all classes of dental Fluorosis, except in the moderate class where males were slightly more. Also, patients with severe dental fluorosis were more among females than males. This is in

agreement with a previous report where there were more patients with severe dental fluorosis compared to any other class of dental fluorosis presented in the clinic.² The unpleasant appearance of teeth in severe dental fluorosis may be the major reason for these findings. More females presenting with severe dental fluorosis in this study may be due to females' consciousness of better aesthetic appearance than males.

The preponderance of female patients presenting with dental fluorosis in this study may be attributed to the fact that more females sought dental care than males as reported previously in other clinically based studies.^{30,31} It may also be as a result of females having more concern and seeking for better appearance of their teeth and that of their children compared to male patients. The prevalence of dental fluorosis was 11.4% and 11.3% among secondary school adolescents in South West and South East Nigeria respectively.^{15,16} This prevalence was lower than 16.7%, the proportion of patients who presented with dental fluorosis in this present study. The observed differences may be due to differences in study design. Results of classification of dental fluorosis using Deans Index among the patients showed that more patients presented with moderate dental fluorosis as compared to other classes of dental fluorosis. This is in agreement with results from a previous study,²³ and contrary to another study where mild fluorosis was reported to be preponderant among school aged children.¹⁵

Assessment of dental caries on teeth affected by dental fluorosis among patients showed no statistically significant relationship in agreement with a previous study where there was no relationship between the severity of dental fluorosis and dental caries,³² but contrary to results from other previous studies where the severity of dental fluorosis was reported to have a significant reduction on caries development.^{33, 34} Although the initiation and progression of dental caries was strongly linked to fluoride content of daily water consumed,^{15,20} the lack of significant relationship between the classes of dental fluorosis and dental caries in this study may be due to multifactorial etiology of dental caries. Other factors such as oral hygiene practices, refined sugar diet, and presence of cariogenic bacteria play important roles.

Among the patients who were seen at the oral health care facility during the study period, a proportion of 200 (16.7%) were diagnosed of dental fluorosis. Out of the patients diagnosed of dental fluorosis, 185 (92.5%) requested for treatment due to unpleasant appearances of their teeth. This proportion was higher than the result from a similar study where 9.3% of patients with dental fluorosis requested for intervention.²

Interventions were carried out among 185 out of 200 patients diagnosed with dental fluorosis and the aim was to improve appearances and enhance the patients' self-esteem. All the intervention procedures and the cost implications were explained to each patient to allow them make an informed choice. While all the patients received scaling and polishing, others however received

multiple treatments among which were scaling and polishing, micro abrasion, and resin infiltration. The treatment modalities of dental fluorosis in this study conformed with previous studies.^{1,34} The majority of patients who had micro abrasion as a treatment modality were in the classes of mild and moderate dental fluorosis. This also conforms to findings from a previous report of treatment options among patients with dental fluorosis.³⁵ Results from this present study shows that only one patient with mild fluorosis had resin infiltration while majority of the patients with severe dental fluorosis received resin infiltration. This was probably due to the degree of the dental fluorosis as it affects appearances of the teeth, cost of treatment, and a better appearance after treatment. The outcome of resin infiltration significantly improved the recipient's appearances and this is in agreement with other previous studies.^{1, 34, 35} The patients were monitored for/between 1-2 years with the majority having their resin restorations intact.

Conclusion

Dental fluorosis causes low self-esteem and negatively affects quality of life among dental patients. It was a reason for dental visit as a significant proportion of the dental out-patients sought for intervention at the study center. Presentation was more among children and teenagers below 20 years. More females presented and requested for intervention than the males. Resin infiltration was found to be cost effective at this facility. More patients presented with moderate class of dental fluorosis, and

dental caries infection was found not to be significantly related to any specific class of dental fluorosis in this study.

References

10. Shahroom NSB, Mani G, Ramakrishnan M. Interventions in management of dental fluorosis, an endemic disease: a systematic review. *J of Family Med Prim Care*. 2019;8(10):3108-3113.
11. Idon, PI, Enabulele J. Prevalence, severity and request for treatment of dental fluorosis among adult in an endemic region of Northern Nigeria. *Eur J Dent* 2018;12(2):184
12. Akuno MH, Nocella G, Milia EP, Gutierrez L. Factors influencing the relationship between fluoride in drinking water and dental fluorosis: a ten-year systematic review and meta-analysis. *J Water Health* 2019;17(6): 845-862. <https://doi.org/10.2166/wh.2019.300>
13. Albanto AJ, Rezende KMP, Salazar MSM, Bucholdz TAF, Celibrerti P, Ciamponi AL. Dental fluorosis: exposure, prevention and management. *Med Oral Otol Oral Cir Bucal*. 2009;14:E103-107.
14. Haritash AK, Aggarwal A, Soni J, Sharma K, Sapra M, Singh B. Assessment of fluoride in groundwater and urine, and prevalence of fluorosis among school children in Haryana, India. *Appl Water Sci* 2018;8:52.
15. World Health Organization (WHO). Basic methods for assessment of renal fluoride excretion in community prevention programmes for oral health. 2014, WHO. Geneva.
16. Aoba T, Fejerskov O. Dental fluorosis: chemistry and biology. *Crit Rev Oral Biol Med*. 2002;13:155-70.
17. Sananda D, Biplab G. Fluoride fact on human health and health problems: a review. *Med Cli Rev* 2016;2(1:2):1-6.
18. World Health Organization (WHO). Guidelines for Drinking Water Quality, 2014, 4th ed. WHO, Geneva.
19. Mohanta A, Mohanty PK. Dental fluorosis—revisited. *Biomed J Sci Technol Res* 2018;2:2243-2247. doi:10.26717/BJSTR.2018.02.000667.
20. Rango T, Kravchenko J, Atlaw B, McCornick PG, Jeuland M, Merola B. et al. Groundwater quality and its health impact: an assessment of dental fluorosis in rural inhabitants of the main Ethiopian Rift. *Environ Int* 2012;43:37-47.
21. O'Mullane DM, Baez RJ, Jones S, Lennon MA, Petersen PE, Rugg-Gunn AJ, et al. Fluoride and oral health. *Community Dent*. 2016;33:69-99.
22. Del Carmen AF, Javier FH, Aline CC. Dental fuorosis, fluoride in urine, and nutritional status in adolescent students living in rural areas of Guanajuato, Mexico. *J Int Soc Prev Community Dent*. 2016;6(6):517-522.

23. Rango T, Vengosh A, Jeuland M, Tekle-Haimanot R, Weinthal E, Kravchenko J, et al. Fluoride exposure from groundwater as reflected by urinary fluoride and children's dental fluorosis in the Main Ethiopian Rift Valley. *Sci Total Environ*. 2014;496:188–19.
24. Okoye LO, Ekkwueme OC, Sote EO, Amaechi BT. Prevalence of dental fluorosis among 12-15-year-old students in Enugu Metropolis, Nigeria. *Indian J Dent Res* 2019;30(3):462-467.
25. Ajayi D, Arigbede A, Dosumu OO, Ufomata D. The prevalence and severity of Dental Fluorosis among secondary school children in Ibadan, Nigeria. *Postgrad Med J* 2012;19(2):102-6.
26. Akpata ES, Danfillo IS, Otoh EC, Mafeni JO. (2009). Geographical mapping of fluoride levels in drinking water sources in Nigeria. *Afri Health Sci*, 9(4), 227–233.
27. Dean HT. The Investigation of physiological effects by the epidemiological method. In: Moulton FR (ed). *Fluorine and dental health*. Washington, DC: American Association for the Advancement of Science, Publication No. 1942;19:23–31.
28. Faul F, Erdfelder E, Buchner A, Lang A.-G. (2009). Statistical power analyses using G*Power 3.1: Tests for correlation and regression analyses. *Behav Res Methods*, 41, 1149-1160
29. Whelton HP, Ketley CE, McSweeney F, O'Mullane DM. A review of fluorosis in the European Union: Prevalence, risk factors and aesthetic issues. *Community Dent Oral Epidemiol* 2004;32(1):9-18.
30. Clark DC, Hann HJ, Williamson MF, Berkowitz J. Aesthetic concern of children and parents in relation to different classifications of the Tooth Surface Index of fluorosis. *Community Dent Oral Epidemiol* 1993;21(6):360-364.
31. Curtis AM, Levy SM, Cavanaugh JE, Warren JJ, Kolker JL, Weber-Gasparoni K. Decline in dental fluorosis severity during adolescence: a cohort study. *J Dent Res*. 2020;99(4):388-394.
- 21 Verma A, Shetty BK, Guddattu V, Chourasia MK, Pundir P. High prevalence of dental fluorosis among adolescents is a growing concern: a school based cross-sectional study from Southern India. *Environ H Prev Med* 2017;22(1):1-7.
- 22 Gopalakrishnan P, Vasanth RS, Sharma PS, Nair KS, Hankappan KR. Prevalence of dental fluorosis and associated risk factors in Alappuzha district Kerala. *Natl Med J India* 1999;12(2):99-103.
- 23 Demirci M, Tuncer S, Yuceokur A. Prevalence of caries on individual tooth surfaces and its distribution by age and sex in university clinic patients. *Eur J Dent* 2010;4:270-277.

- 24 Arvind BA, Isaac A, Murthy NS, Shivaraj NS, Suryanarayana SP, Pruthvish S. Prevalence and severity of dental fluorosis and genu valgum among school children in rural field practice area of a medical college. *Asian Pac J Trop Dis Asian Pac Trop Med Press* 2012;2:465-469.
- 25 Sukhabogi JR, Parthasarathi P, Anjum S, Shekar BRC, Padma CM, Rani AS. Dental fluorosis and dental caries prevalence among 12- and 15-year-old school children in Nalgonda district, Andhra Pradesh, India *Annals of Medical and Health Sciences Research*. 2014;4(SUPPL 3): S245-S252.
- 26 Mane AB, Revathi S, Sarale DG, Paul CN, Hiremath SG. Studies of dental fluorosis among primary school children residing in rural area of Raschar district, Karnataka. *Int J Biol Med Res* 2011;2(3):716-720.
- 27 Singh M, Saini A, Saimbi CS, Bajpai AK. Prevalence of dental diseases in 5- to 14-year-old school children in rural areas of the Barabanki district, Uttar Pradesh, India. *Indian J Dent Res*. 2011;22:396-399.
- 28 Idowu EA, Afolabi AO, Fakuade BO, Akintububo OB, Ibiyemi O. Self-medication profile of Dental Patients Attending a North Eastern Tertiary Hospital in Nigeria. *Ann Ibd. Pg. Med* 2019;17(2):173-180.
- 29 Ogbebor OG, Azodo CC. Reasons for seeking dental healthcare services in a Nigerian missionary hospital. *Sahara medical journal* 2016;19(1):38-43.
- 30 Taghipour N, Amini H, Mosaferi M, Yunesian M, Pourakbar M, Taghipour H. National and sub-national drinking water fluoride concentrations and prevalence of fluorosis and of decayed, missed, and filled teeth in Iran from 1990 to 2015: a systematic review. *Environ. Sci. Pollut. Res* 2016;23:5077-5098.
- 31 Sebastian ST, Soman RR, Sunitha S. Prevalence of dental fluorosis among primary school children in association with different water fluoride levels in Mysore district, Karnataka. *Indian J Dent Res* 2016;27(2):151-154.
- 32 Fan Z, Gao Y, Wang W, Gong H, Guo M, Zhao S, et al. Prevalence of brick tea-type fluorosis in the Tibet autonomous region of China. *J Epid* 2016;26(2):57-63.
- 33 Garg I, Kumar A. Resin Infiltration for esthetic improvement of mild to moderate non-pitted fluorosis stains in 6-12-year-old Children: a randomized 6-month intervention study. *J South Asian Assoc Pediatr Dent* 2021;4(2):96-103.
- 34 Loguercio A, Correia L, Zago C, Tagliari D, Neumann E, Gomes O, et al. Clinical effectiveness of two microabrasion material for the removal of enamel fluorosis stains. *Oper Dent*. 2007;32:531-538.



- 35 Gugnani N, Pandit I, Goyal V, Gugnani S, Sharma J, Dogra S. Esthetic improvement of white spot lesions and non-pitted fluorosis using resin infiltration technique: series of four clinical cases, J Indian Soc Pedod Prev Dent. 2014;32:176.