

Basal Cell Carcinoma of the Upper Lip in a Nigerian: A Case Report

*Olawuyi AB, **Onanuga BA, **Olorunsola KD, ***Effiom OA, ****Arotiba GT, ***Odukoya O
*Department of Oral and Maxillofacial Pathology/Biology, Lagos University Teaching Hospital, Idi-Araba, Lagos.
**Department of Oral and Maxillofacial Surgery, Lagos University Teaching Hospital, Idi-Araba, Lagos.
***Department of Oral and Maxillofacial Pathology/Biology, College of Medicine, University of Lagos, Lagos, Nigeria.
****Department of Oral and Maxillofacial Surgery, College of Medicine, University of Lagos, Lagos, Nigeria.

Correspondence: Olawuyi AB
E-mail: toksolawuyi@yahoo.com

Abstract

A case of a 75 year old community health worker and part time farmer that presented at the Burns and Plastic Unit of the Lagos University Teaching Hospital, Lagos Nigeria was reported. The lesion commenced as a nodular mass on the upper lip which later progressed into an ulcer. The patient was managed by surgical excision and reconstruction.

Keywords: Basal cell, Carcinoma, Upper lip.

Introduction

Basal cell carcinoma (BCC) is a locally invasive malignant epidermal tumour that has the potential to cause extensive deformity and destruction of vital structures but rarely metastasizes^{1,2}. It is the most common skin cancer in humans accounting for about 65.0% of all skin cancers and has a predilection for exposed parts of the body. About 74.0% of all BCC occur in the head and neck^{2,4}.

Case Report

A 75 year old female community health worker and part time farmer presented at the Burns and Plastic Unit of the Lagos University Teaching Hospital, Lagos Nigeria with a 5 year history of painful ulceration on the skin of the upper lip. The lesion initially started as a nodule on the upper lip which that later became an ulcer. There was no history of systemic illness. There was history of chronic sun exposure as a result of the nature of the patient's job. There was no lymphadenopathy. Examination revealed an ulcer that extended from the left side of the philtral column over the ridge to beneath the left nostril. The ulcer was about 2 cm in its greatest diameter. Patient had incisional biopsy done and histopathology examination revealed a diagnosis of infiltrative type of Basal cell carcinoma. No surgery was done but patient had two courses of radiotherapy (first course 55Gy, second course 20Gy) and was placed on topical 5-Fluorouracil.

The lesion did not resolve but gradually increased in

size. She was therefore referred to the Oral and Maxillofacial Surgery Clinic. Examination revealed an ulcer that had eroded the entire thickness of the upper lip, sparing only about 1 cm on the right upper lip and terminated at the lip commissure on the left side, the nasal floor was also affected along with the inferior portions of the nasal alar bilaterally as well as the columella (Fig. 1).

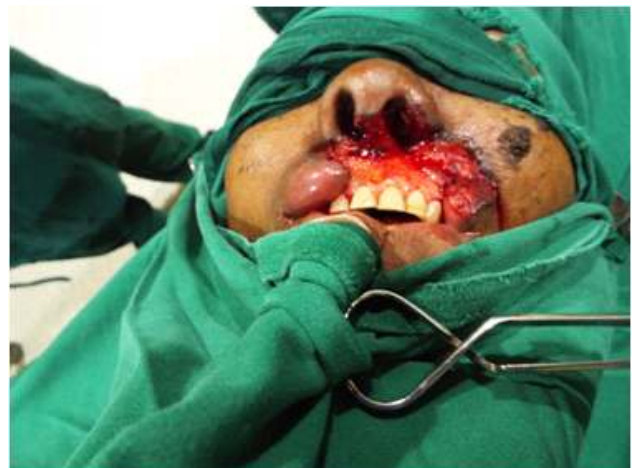

Fig. 1: Erosion of the entire thickness of the upper lip

A repeat biopsy revealed irregular islands and sheets of moderately differentiated epithelial cells which in many areas appear basophilic, infiltrating the connective tissue stroma with palisading of peripheral basal cells (Fig. 2).

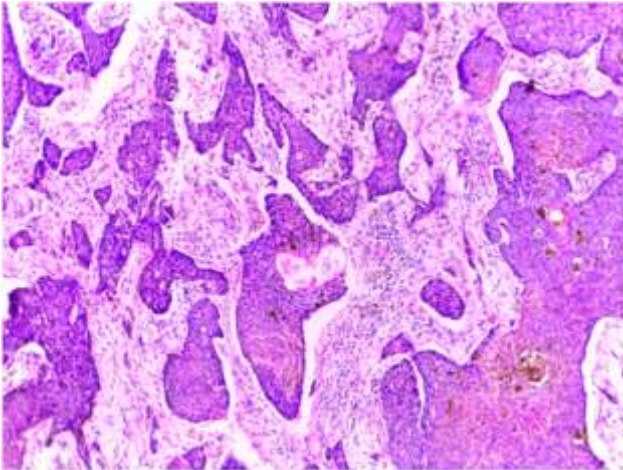


Fig. 2: Irregular islands and sheets of moderately differentiated epithelial cells infiltrating the connective tissue stroma with palisading of peripheral basal cells (H&E X 40)

There was retraction of tumour cells from the stroma and focal areas of necrosis were seen within the tumour cells. Tumour cells had variable chromaticity and pleomorphism. Individual cell keratinization and keratin pearl formation were also seen (Fig. 3).

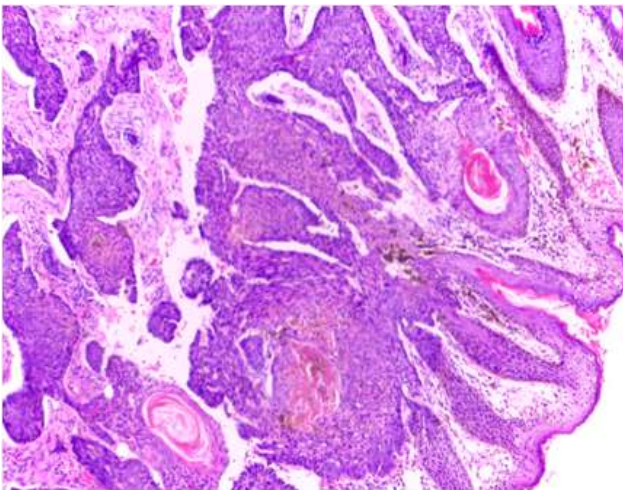


Fig. 3: Keratin pearl formation (H&E X 40)

Chronic inflammatory cells were seen in the connective tissue. A diagnosis of basosquamous variant of BCC was made. Routine investigations were all normal.

Presurgical evaluation was done with computerised Tomographic scan, chest x-ray, haemogram, electrocardiogram, liver function and kidney function tests. Patient was scheduled for surgical excision under General Anaesthesia. Routine scrubbing and

draping was done, then the proposed incision sites were infiltrated with 1:200,000 adrenaline solution. After waiting for a period of 7 minutes to allow the local anaesthetic to take effect, the lesion was excised with a margin of adjacent uninvolved tissues. All the affected tissues, the upper lip, the cheek, nasal mucosa, the columella and alar cartilages bilaterally were all excised leaving adequately clear margins. Gloves were then changed and the reconstruction was commenced by excising a crescentic wedge of tissues along the margin of the right alar, the labial sulcus was also released so as to raise the right crescentic peri-alar flap. The flap was advanced medially and the remaining defect was measured.

A full thickness nasolabial flap was raised on the left side based on the left inferior labial artery; the skin was undermined and mobilized (Fig. 4a). The left nasolabial flap was rotated medially to meet the advanced peri-alar crescentic flap (Fig. 4b); the superior part of the nasolabial flap was used to reconstruct the nasal floor, columella base and the alar bases bilaterally.

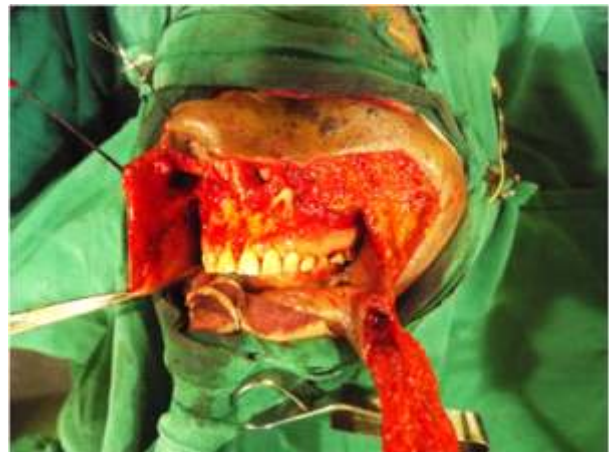

Fig. 4a: A full thickness nasolabial flap based on the inferior labial artery was raised on the left side

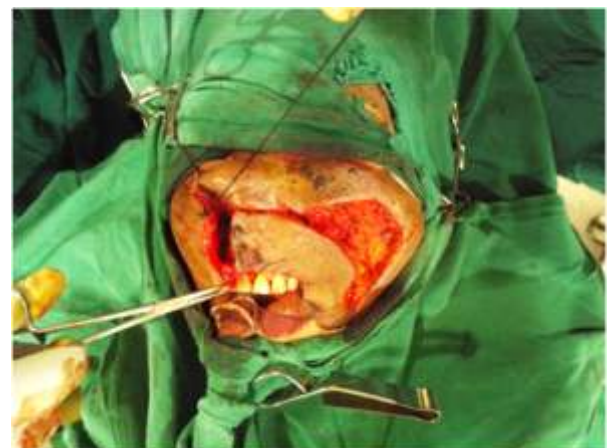

Fig. 4b: The left nasiolabial flap rotated medially.

An oblique superior incision was made towards the zygomatic bone and then undermined. An inferior incision was also made towards the upper cervical region on the left side, undermined to enhance mobilization. The cheek flap raised was advanced medially to cover the secondary defect from the nasolabial flap.

Suturing was done in layers with 3/0 vicryl suture subcutaneously and skin closure done with 4/0 nylon suture. The raw surfaces of the upper labial sulcus and the nasal floor were dressed with sulfratulle gauze. The patient was discharged home 5 days postoperatively and had sutures removed at the one-week post operative review (Fig. 5).



Fig. 5: Upper Lip Reconstruction

Discussion

BCC is a locally invasive malignancy that arises from the basal layer of the epithelium; it is the most common skin cancer and was first described by Jacob in 1827¹⁰. Skin cancers are classified into two major groups: melanomas and non-melanomas. The lesion may arise from anywhere on the skin, but over 80% are seen on the sun-exposed skin of the head and neck².

While it is the most common cancer in Caucasians, it is rarely seen in Black Africans. Its prevalence in blacks is about 1.2% to 4.6%¹¹. BCC is uncommon in blacks because of the photo protection offered by the higher melanin content of their skin and because the dispersion pattern of melanosomes which protects them from the carcinogenic effects of sunlight⁸. BCC is commonly seen in patients from the 5th to the 9th decade of life with the peak incidence in the 6th and 7th decades³. BCC affects men more than women; this may be due to longer hours of sun exposure in males, though incidence of BCC in females appears

to be on the increase because of exposure to sunlight in certain outdoor professions or recreational activities¹². The present report occurred in a 75 year old female with history of chronic sun exposure.

Exposure to ultraviolet radiation which causes cumulative DNA damage is a major risk factor for development of BCC. Other risk factors include exposure to ionizing radiation and photosensitizing drugs, chronic exposure to arsenic and coal tar derivatives and immunosuppression⁵⁻⁸. It has been reported that BCC is four times more likely to occur on the embryonic fusion planes (the regions of mesenchymal migration and fusion of the five primordial facial processes during the 5th to 10th weeks of human development) than in other regions of the midface¹³. The present case occurred in the upper lip; the medial aspect of the upper lip is formed by fusion of the two medial nasal processes with each other and the lateral aspect of the upper lip is formed by fusion of the maxillary process with the lateral nasal process¹⁴.

BCC is also associated with genetic conditions such as Nevroid basal cell carcinoma syndrome, Xeroderma pigmentosum, Gardners syndrome, Albinism, Bazex syndrome, Epidermodysplasia verruciformis and Nevus sebaceous¹⁵. Nevroid basal cell carcinoma syndrome, also known as Gorlin Goltz syndrome is a rare autosomal dominant condition caused by PCTH gene mutations at chromosome 9q22.3-q31 which inhibits the hedgehog signaling pathway. The major clinical manifestations of the syndrome are multiple BCC, multiple jaw cysts, skeletal abnormalities and palmar and plantar keratotic pitting¹².

The term "rodent ulcer" was first used by Jacob Arthur in 1827 to describe BCC¹⁶. The lesion has five main clinical-pathologic subtypes which are nodular-ulcerative, pigmented, superficial, morpheic or morpheiform and fibroepithelioma of pinkus¹⁷. Nodular BCC is the most common type and occurs in the sun exposed parts of the head and neck. It starts initially as a nodule, plaque, papule or cyst-like lump with a rolled edge, central depression or telangiectasia that eventually ulcerates^{15,16}. The pigmented type differs from the nodular-ulcerative variant by the presence of pigmentation, which may vary from blue to tan, brown or black depending on the number and activity of melanocytes within the tumour¹⁵.

The superficial BCC is commonly seen on the extremities and the trunk and presents as an erythematous patch similar to psoriasis or eczema and is seen in HIV patients¹⁵. The morpheiform BCC presents as an enlarging white plaque with potential

for aggressiveness, the infiltrative type is characterized by deep invasion of the dermis and aggressiveness while the fibroepithelioma of pinkus is seen in the lumbar region and resembles a seborrheic keratosis or fibroepithelial polypus^{15,16}. The present case is the nodular-ulcerative subtype: the lesion initially started as a papule before becoming ulcerated.

BCC presents histologically with features consisting of palisaded prominent basal cells, a specialized stroma and clefting or retraction between the epithelium and the stroma. There are six histologic variants of the lesion; solid circumscribed, adenoid, Basosquamous, infiltrative, keratotic and pigmented¹⁵⁻¹⁷. The solid circumscribed appears to be the most common and presents as circumscribed solid masses of tumour cells with palisading of the peripheral layer¹⁷. Tumour cells in adenoid BCC are arranged in formations that resemble tubular gland-like structures. The basosquamous variant usually shows features of both BCC and Squamous cell carcinoma (SCC)¹⁷. Our patient had features of BCC and SCC, there was peripheral palisading of basal cells and tumour cells presented with variable chromaticity and pleomorphism. Individual cell keratinization and keratin pearl formation were seen. Keratotic basal cell carcinoma usually presents as keratinization in the form of horn cysts. The basaloid cells in Infiltrating BCC are arranged in cords with deep infiltration into the dermis while in pigmented BCC, there are peripheral palisading of basal cells, pigment laden macrophages and lymphoplasmacytic infiltrates¹⁵⁻¹⁷.

Treatment options for BCC include curettage and cautery, laser surgery, cryotherapy, wide local excision, micrographic surgery, radiotherapy, photodynamic therapy and the use of imiquimod (immune response modifier). Wide surgical excision is regarded as the gold standard for treatment of BCC. Complete removal of the lesion must be ensured^{1,18}. Facial appearance after surgery is usually acceptable especially when excision and reconstruction are done by experienced surgeons^{1,18}. Recurrence rate of less than 2% after 5 years has been reported in two different series after wide surgical excision^{19,20}. This case was treated by wide surgical excision and upper lip reconstruction was done with a peri-alar crescentic incision on the right and a full thickness nasolabial flap on the left.

Conclusion

Basal Cell Carcinoma is a locally invasive malignant epidermal tumor common in individuals with fair skin

but rarely seen in blacks. The major risk factor for BCC is exposure to ultraviolet radiation. Wide surgical excision, histopathologic analysis of tumour margins and long term follow-up are advised.

References

1. Rezakovic S, Zuzul K, Kostovic K. Basal Cell Carcinoma – Review of Treatment Modalities. *J Dermatolog Clin Res* 2014; 2(5): 1035.
2. Sartore L, Lancerotto L, Salmaso M et al., Facial basal cell carcinoma: analysis of recurrence and follow-up strategies. *Oncol Reports* 2011; 26(6): 1423–1429.
3. Duriye DD, Candemir C, Berrak A et al. Basal Cell Carcinoma of the Head and Neck Region: A Retrospective Analysis of Completely Excised 331 Cases. *J Skin Cancer*. 2014; 4:1-6
4. Wilson A.W, Howsam G, Santhanam V. Surgical management of incompletely excised basal cell carcinomas of the head and neck *Br J Oral Maxillofac Surg*. 2004; 42(4):311–314.
5. Welsch MJ, Troiani BM, Hale L et al. Basal cell carcinoma characteristics as predictors of depth of invasion. *J Am Acad Dermatol* 2012; 67:47–53
6. Gallagher RP, Hill GB, Bajdik CD, et al. Sunlight exposure, pigmentary factors, and risk of nonmelanocytic skin cancer. Part 1. Basal cell carcinoma. *Arch Dermatol* 1995; 131:157–163
7. Trakatelli M, Morton C, Nagore E, et al. Update of the European guidelines for basal cell carcinoma management. *Eur J Dermatol* 2014; 24:312–329
8. Gloster HM Jr, Neal K Skin cancer in skin of color. *J Am Acad Dermatol*. 2006;55: 741-760.
9. Kaae J, Boyd HA, Hansen AV, Wulf HC, Wohlfahrt J, Melbye M. Photosensitizing medication use and risk of skin cancer. *Cancer Epidemiol Biomarkers Prev* 2010; 19:2942–2949
10. Kirkham N. Tumours and cysts of epidermis. In *Lever's histopathology of skin*. 9th ed. Philadelphia: Lippincott Raven; 2005; 805-866.
11. Jahan-Tigh RR, Alston JL, Umphlett M (2010) Basal cell carcinoma with metastasis to the lung in an African American man. *J Am Acad Dermatol*. 2010; 63:87-89.
12. Nakayama M, Tabuchi K, Nakamura Y et al. Basal cell carcinoma of the head and neck. *J Skin Cancer* 2011;2011:496910.



13. Newman JC, Leffell DJ. Correlation of embryonic fusion planes with the anatomical distribution of basal cell carcinoma. *Derm Surg*. 2007 ;33(8):957-964.
14. Nanci A. Embryology of the Head, Face and Oral cavity. In: Nanci A eds *Ten Cate's Oral Histology* 8th ed. St Louis, Missouri: Elsevier 2009. p 26-47
15. Seum C. Basal Cell Carcinoma. *Arch Plast Surg* 2012; 39:166-170
16. Janjua OS, Qureshi SM. Basal cell carcinoma of the head and neck region: An analysis of 171 cases. *J Skin Cancer* 2012; 943-947.
17. Gundalli S, Kolekar R, Kolekar et al. Study of basal cell carcinoma and its histopathological variants. *Dermatol Online*. 2015;6(4):399-403.
18. Baxter JM, Patel AN, Varma S. Facial basal cell carcinoma. *BMJ* 2012;345: e5342
19. Walker P, Hill D. Surgical treatment of basal cell carcinomas using standard postoperative histological assessment. *Australas J Dermatol* 2006; 47:1-12.
20. Griffiths RW, Suvarna SK, Stone J. Do basal cell carcinomas recur after complete conventional surgical excision? *Br J Plast Surg* 2005; 58:795-805.