
Mansoura Veterinary Medical Journal

MYXOSPORIDIOSIS IN OREOCHROMIS NILOTICUS; MOLECULAR IDENTIFICATION AND OXIDATIVE STRESS BIOMARKERS

Nevien K Abdelkhale*, M. A. El-Adl**, M. F. Hamed***, M. A. Al-Araby****

*Department of internal medicine, Infectious diseases and fish diseases and management, faculty of veterinary medicine, Mansoura University

**Department of biochemistry and chemistry of nutrition, faculty of veterinary medicine, Mansoura University

***Department of pathology, faculty of veterinary medicine, Mansoura University

****Department of parasitology, faculty of veterinary medicine, Mansoura University

ABSTRACT

Myxosporidiosis a protozoan parasitic fish disease that causes damages to fish organs and might eventually end with mortalities and deterioration of meat quality of the affected fish. The presence of parasitic infestation is usually accompanied with the production of reactive oxygen and nitrogen species that produces extra damage to host organs and inactivation of antioxidant defense system that increase the intensity of parasitic infestation. Recently, the response of the infested tissue to oxidative stress is varied depending on the type of parasite; therefore the use of oxidative stress markers as indicator for myxobolus infestation is relevant. In the present study, Oreochromis niloticus was investigated for oxidative stress markers (GST, SOD, NO, H₂O₂ and MDA) in liver, muscle, spleen and gills infested with myxobolus spp. Histopathological examination was performed to clarify the cellular damage associated with myxobolus infestation. Results indicated that there was a non-significant change in GST activity in all organs, while SOD activity was significantly decreased in liver and gills after myxobolus infestation. The concentration of nitric oxide, hydrogen peroxide, and lipid peroxidation were significantly increased in (gills and spleen); (liver, spleen and muscle); (liver and muscles), respectively. Intestine and eyes of the affected fish showed a degenerative changes and replacement of the epithelial tissues with myxobolus spores with characteristic eosinophilic granules that has a role in the immunity of host against parasitic infestation. The phylogenetic analysis showed that the identified species of myxobolus in the present study was revealed a close relationship as well as a high identity percentage with, Myxobolus kisutchi and similar tissue tropism which highlighted the use of both molecular identification and oxidative stress markers for diagnosis of myxobolus infestation in dead fish when the parasitological examination alone becomes inadequate for accurate detection of myxobolus infestation.

Key words: Myxosporidiosis, oxidative stress biomarkers, *O. niloticus*

INTRODUCTION

Fish protein is a valuable source of protein that is important for human health distributed in every portion of the world either marine or fresh sources (Kent et al., 2001). *Oreochromis niloticus*, the most popular fish species, is used extensively in aquaculture for

decades to guarantee a perfect source of cheap and high quality protein (Scholz, 1999).

Fish industry worldwide suffered from different diseases problems either environmental or microbial. In Egypt, about 80% of fish diseases are parasitic (Eissa, 2002). The phylum Myxozoa is a primitive multi-cellular micro-parasite affects wide range of living species (more than 1500 species

parasitizing both fresh and marine water fish) causing mass mortalities and even deteriorated the quality of meat due to the lysis of muscle fibers that found disapproval to the consumers (Dudin, 2010; Lom and Dykova, 2006). It could extend to internal organs causing severe mortalities (Abdel-Ghaffar et al., 2008). The similarity of several myxobolus species in morphological characters requires further tools for accurate identification of their presence. From this point, Camus and Griffin, (2010) suggested the use of molecular identification of small ribosomal subunit for identification of myxobolus infestation as a tool for accurate diagnosis.

It was recorded that environmental pollution with the presence of different pathogenic microorganism are capable of performing oxidative stress through causing imbalances of the ratio between oxidants and antioxidant defense system in body which would eventually result in oxidative damages due to the production of reactive oxygen and nitrogen species that leads to enzyme inactivation and the increase of lipid peroxidation and nitrosative stress in the exposed species (Banudevi et al., 2006). However, the oxidative stress markers against different parasitic disease are not yet established. Furthermore, the need to study the host response after parasitic infestation is an important task to determine the required methods to control parasitic diseases and subsequently resolve the cause of mortalities and then increase fish production (Rudneva et al., 2010). From this point, the aim of this study is to establish oxidative stress biomarkers against myxobolus infestation in *Oreochromis niloticus* explaining the cellular damages of this parasite in different organs of the affected fish species for diagnosis of myxobolus infestation with the aid of Molecular biological study using small ribosomal subunit and the basic parasitological techniques..

MATERIAL AND METHODS

2.1 Fish sampling and parasitological examination:

In the present study, fifty fish samples of *Oreochromis niloticus* were randomly collected from fish farm located at Kafr El-Sheikh governorates suffering from signs of off-food, dullness, ocular opacity and stunted growth during autumn season of 2014 with average body weight (35 ± 1.5). The collected fish were transferred to the laboratory of fish diseases and management, Dept. of internal medicine, Infectious and Fish diseases, Faculty of veterinary medicine, Mansoura University for further parasitological identification. A skin and gill scraping, tissue smears were prepared with a drop of a normal saline (wet mount technique) and examined microscopically and the positive smears were air dried, fixed with absolute methanol and stained with 10 % Giemsa stain for detection of the spores according to (Melanin et al., 2010).

2.2 Oxidative stress biomarkers:

Fish were dissected for collection of gills, muscle, liver and spleen for oxidative stress biomarkers determination. A negative control group (apparently healthy fish) was collected for normalization of the studied parameters. The collected tissues were washed thoroughly with normal saline (0.9%) and immediately homogenized in ice-cold sterile phosphate buffer saline (PH, 7.4) with pellet pestles homogenizing device supplied from (Sigma Aldrich, USA). The homogenized samples were centrifuged at 3000rpm for 30 minutes at 4°C, and the collected supernatant was stored at - 80°C for the determination of oxidative stress biomarkers as follow:

2.2.1 Glutathione S transferase (GST) activity determination:

Glutathione -S-transfease was determined according to the method of Habig et al., (1974) where an aliquot of the homogenized sample

was reacted with Dichloronitrobenzene to form mercaptouric acid which was detected by using (Jenway 6305, UK) spectrophotometer at 340 nm.

2.2.2 *Superoxide dismutase (SOD) activity determination:*

The activity of superoxide dismutase was determined using the technique of **Nishikimi et al., (1972)** through the inhibition of phenazinemetosulphate by the tissue content of SOD which would subsequently reducednitrobluetetrazolium dye to violet color that was spectrophotometrically determined at 540 nm using (Jenway 6305, UK).

2.2.3 *Nitric oxide concentration (NO) determination:*

The determination of concentration of nitric oxide was determined through formation of bright red color after the reaction of nitric oxide with sulphanilamide and 1-naphthyl ethylenediamine(**Montgomery and Dymock, 1961**).

2.2.4 *Hydrogen peroxide (H₂O₂) concentration determination:*

Hydrogen peroxide reacted with 3,5-dichloro-2-hydroxybenzensulfonic (DHBS) acid and 4-aminophenazone in the presence of horseradish peroxidase to form Quinoneimine Dye that appeared as red color where its intensity was measured spectrophotometrically at 510 nm according to **Fossati and Prencipe(1982)**.

2.2.5 *Malondialdehyde (MDA) concentration determination:*

Malondialdehydewas measured according to the method of **Yoshioka et al., (1982)**. The aliquot of total homogenate was shaken with 2.5 ml of TCA 20% in 10 ml centrifuge tube. To the mixture, 1 ml of 0.67%TBA was added, shaken and warmed for 30 minutes in boiling water bath followed by

rapid cooling. Then 4 ml of Iso- butanol were added. Then after shaking the mixture, it was centrifuged at 3000 rpm for 10 minutes. The resultant upper layer was taken into a separate tube and the MDA content was determined from its absorbance at 532 nm.

2.3 **Histopathological examination:**

The affected organs were dissected out, washed with normal saline (0.9%) and fixed in 10 % neutral buffered formalin for histopathological examination. The paraffin embedded sections was cut at 5 µm stained with Meyer's hematoxylin and eosin (**Gridley, 1960**) for further investigation with Leica light microscope.

2.4 **Molecular identification of the detected Myxobolus sp.**

All fish samples suffered from corneal opacity were collected for molecular identification. Tissue samples were fixed on ethanol for further DNA extraction procedures. DNA extraction was performed using phenol/chloroform method according to **Sambrooketal., (1989)**. DNA concentration was measured with nano spectrophotometer (Implen, USA) and DNA integrity was checked using gel electrophoresis (Hybaid, UK).The polymerase chain reaction was carried out on a 25 µl reaction using TaKaRamastermix with the following primer pairs MyxoF: GATAACCGTGGGAAATCTAGAG and MyxoR: CGTGTTGAGTCAAATTAAGCC. The PCR protocol was as followed: Initial denaturation (95°C for 5 minutes), that followed by 40 cycles of denaturation step (95 for one minute), annealing step (58 °C for one minute), extension step (72 °C for 2 minutes) with a final extension step (72 °C for 9 minutes). The PCR product was visualized using gel electrophoresis (agarose 1.5% with 20µl ethidium bromide), and then the collected fragment of gel-containing PCR product was purified using (GeneJET Gel Extraction Kit - Thermo Fisher Scientific), and sequenced using

sequencer device (*Applied Biosystems* 3130 Genetic Analyzer) in both directions with MyxoF and MyxoR primers. The phylogenetic analysis of the sequenced *Myxobolus* species of the present study was performed using (mega5.2 software) (Tamura et al., 2011) to determine its position among the previously recorded myxobolus species that listed in table (1). Neighbour joining method was used for constructing phylogenetic analysis where 1000 replicates were used for bootstrap analysis.

Statistical analysis:

The result of oxidative stress markers was statistically analyzed using SPSS software V. 20 using a P-value with a significant level at 0.05. The use of Independent T-test was performed between control and myxobolus infested species to compare means.

RESULTS

4.1 Parasitological results:

The detected myxobolus species was morphologically similar to *Myxobolus niloticus fahmii* 1971. The spores were rounded to drop shape with a blunt posterior end and tapered anterior end. The spore measurement was as follows: $12 \pm 0.5 \mu\text{m}$ (11–13) in length and 6 ± 0.4 (7–8) in width. The equal-sized polar capsules were pear shaped and exceeded half of the spore length, measuring $7 \pm 0.3 \mu\text{m}$ (6–7) in length \times 3 ± 0.4 (3–4) in width. The sporoplasm located near posterior end of the detected spores (Fig. 1).

4.2 Oxidative stress biomarker

There was a non-significant change in GST activity in all the examined organs (Fig. 2), while SOD activity was significantly ($P < 0.05$) decreased in liver and gills after myxobolus infestation (Fig. 3). The concentration of nitric oxide, hydrogen

peroxide, and lipid peroxidation were significantly ($P < 0.05$) increased in (gills and spleen), (liver, spleen and muscle), (liver and muscles) respectively in organs suffering from myxobolus infestation when compared with control group (Fig. 4, 5, 6).

4.3 Histopathological examination

From all the examined organs, the pathological changes were obvious in eye and intestine of the affected fish as shown in plate 1 as follows: Severe pathological lesions were noticed in the eyes, in peri-orbital tissue, multiple spores of myxobolus parasites were noticed. The spores were aggregated in the form of cyst-like lesion containing different developmental stages of the parasite (A). On the periphery of the cyst, developmental stages of myxobolus were noticed, while in the centre, the characteristic spores occupied the whole cyst. The individual spore appeared with two polar bodies and sporoplasm (B).

Necrosis and desquamation of the intestinal epithelium was a common picture. In the lumen, large number of desquamated epithelium was noticed together with different stages of protozoa seems to be the stages of myxobolus parasite species (C). Many eosinophilic granular cells were noticed along the intestinal tissues especially in the submucosa (D).

4.4 Molecular identification and phylogenetic analysis:

In figure 7, the phylogenetic analysis of the current study revealed the presence of three clades of *Myxobolus* species that was classified according to tissue tropism into branchial tropism clade, neurotropism clade and muscular tropism clade. The identified species of myxobolus in the present study was showing a close relationship to the *Myxobolus kisutchi* have a neurotropism.

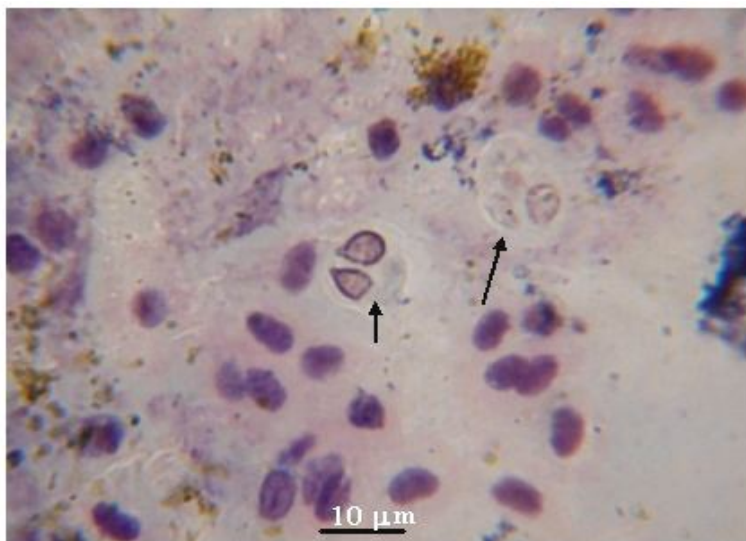


Fig 1: Myxosporidae spores taken from the gill filaments of *Oreochromis niloticus* stained with Giemsa stain (arrows) (100X)

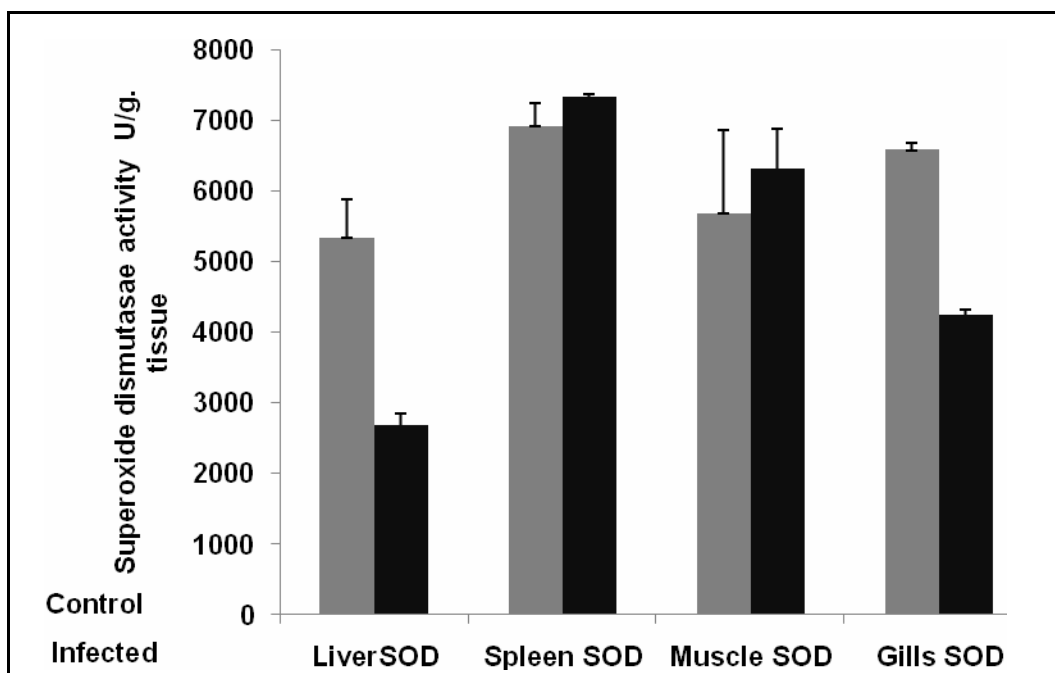


Fig. 2: Glutathione S transferase activity (U/g) in liver, spleen, muscle and gills of *O. niloticus*. The values in this graph is plotted as mean ± standard error of mean ($P < 0.05$).

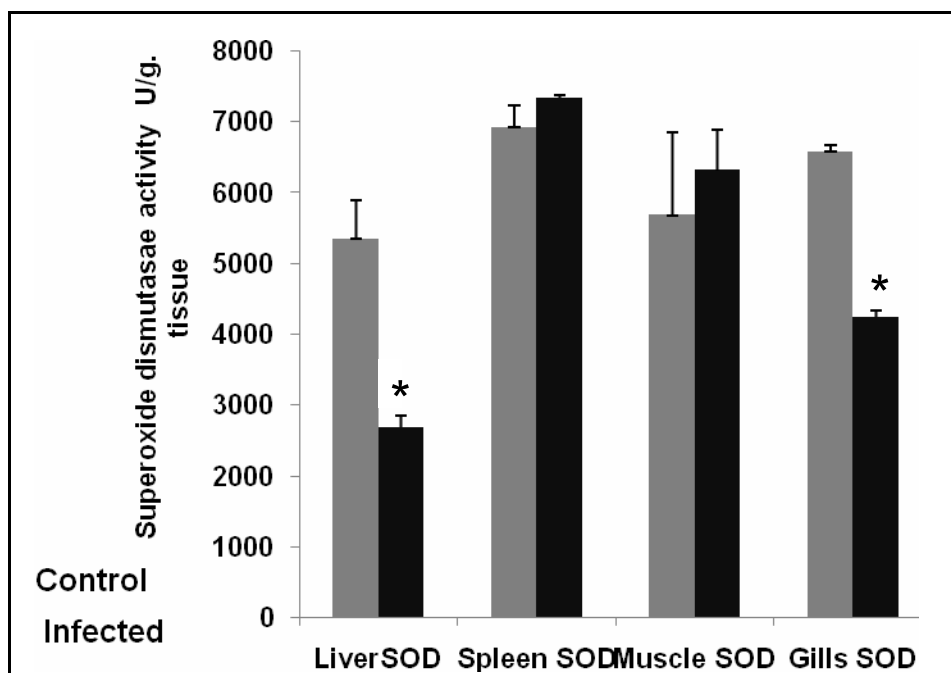


Fig 3:Superoxide dismutase activity (U/g) in liver, spleen, muscle and gills of *O.niloticus*. The values in this graph are plotted as mean ± standard error of mean. The mean values that highlighted with* means that there is a significant difference between the control and the infected fish(P<0.05).

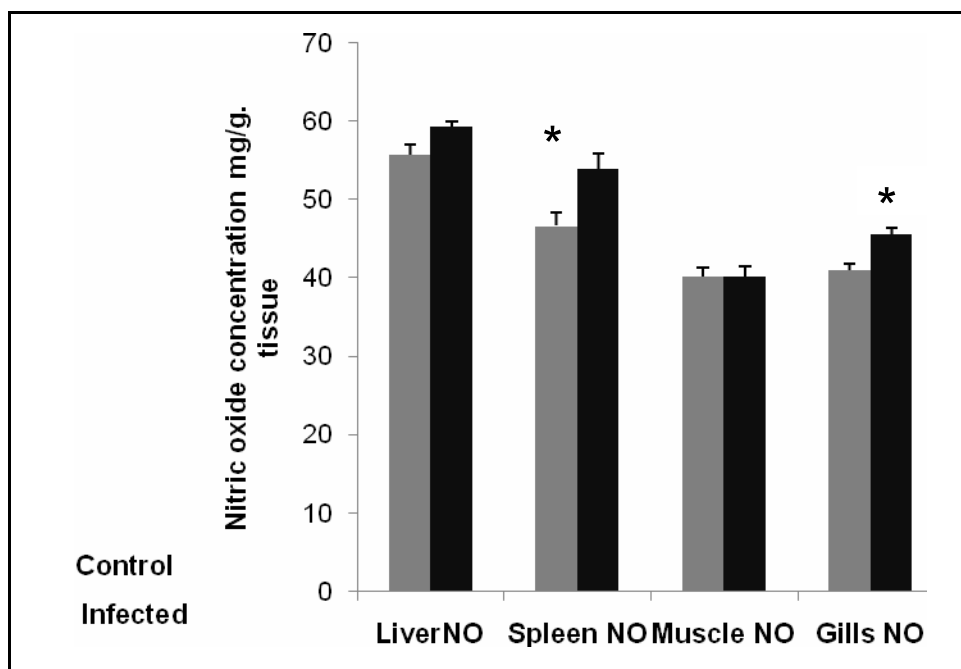


Fig.4: Nitric oxide concentration (mg/g) in liver, spleen, muscle and gills of *O.niloticus*. The values in this graph are plotted as mean ± standard error of mean. The mean values that highlighted with* means that there is a significant difference between the control and the infected fish(P<0.05).

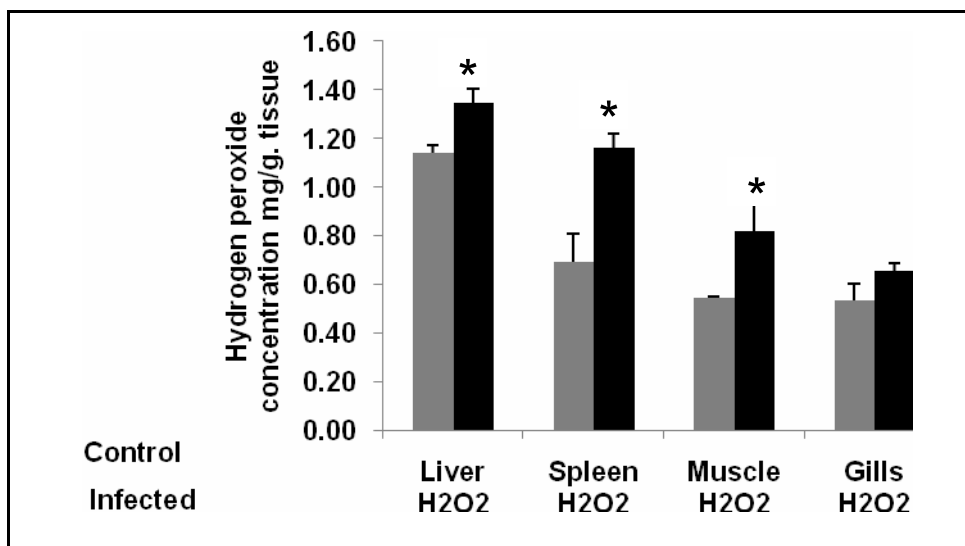


Fig. 5: Hydrogen peroxide concentration (mg/g) in liver, spleen, muscle and gills of *O.niloticus*. The values in this graph are plotted as mean ± standard error of mean. The mean values that highlighted with* means that there is a significant difference between the control and the infected fish(P<0.05).

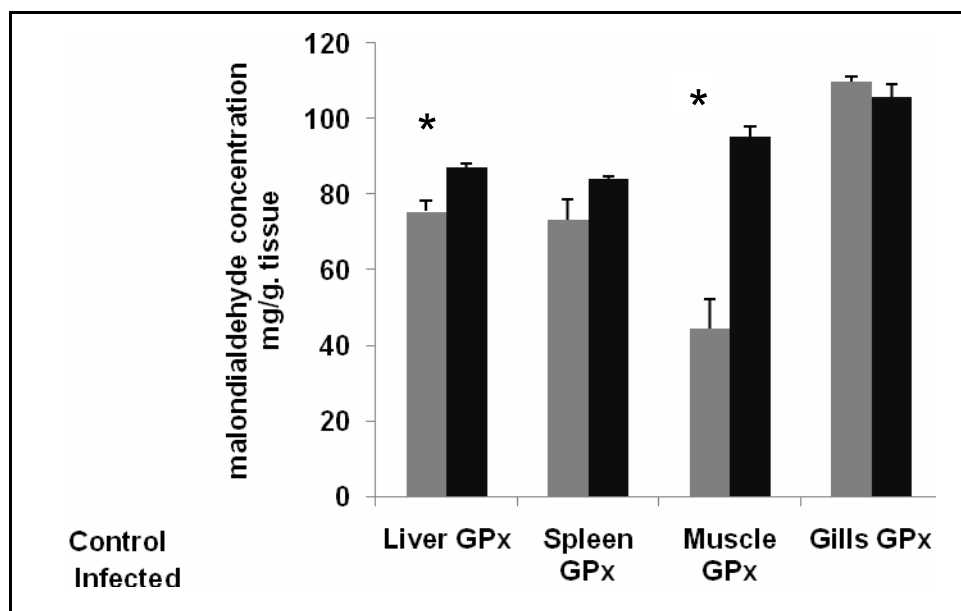


Figure 6: Malondialdehyde concentration (mg/g) in liver, spleen, muscle and gills of *O.niloticus*. The values in this graph are plotted as mean ± standard error of mean. The mean values that highlighted with* means that there is a significant difference between the control and the infected fish(P<0.05).

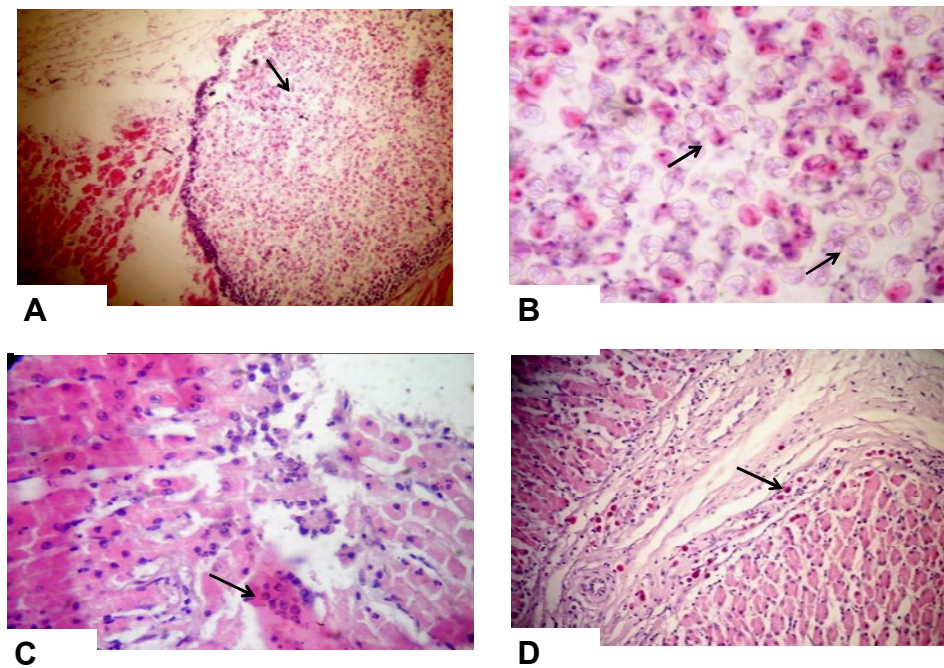


Plate (1) Histopathological section of *Oreochromis niloticus* tissues infested with *myxobolus*

Symbol	Plate 1
A	Eye showing cyst- like formation filled with large number of the spores in the peri- orbital tissue (H&E stain.x40)
B	Eye showing the spores with characteristic polar bodies and sporoplasm (H&E stain.x100)
C	Intestine showing necrosis and desquamation of epithelial lining and different stages of <i>myxobolus</i> development (H&E stain.x40)
D	Intestine showing large number of eosinophilic granular cells (EGC) in submucosa (H&E stain.x40)

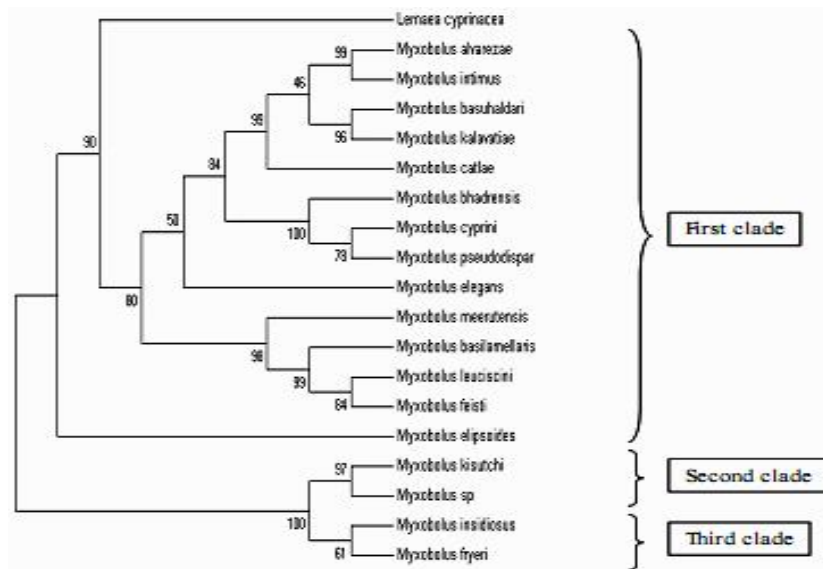


Figure 7:Phylogenetic tree analysis using neighbor joining method (boot strap= 1000). The selected sequence was based on the percent of identity of the identified sequence of Myxobolus species with the others located species in genbank. *Lernaecyprinacea* was named as an out group for the phylogenetic tree.

Table (1): List of myxobolus species that is used for phylogenetic analysis

Species	Accession number	Fish species	Tissue tropism
<i>Myxoboluskisutchi</i>	EF431919	<i>Coho salmon</i>	Brain
<i>Myxobolusinsidiosus</i>	EU346377	<i>Coho salmon</i>	skeletal muscle
<i>Myxobolusfryeri</i>	EU346372	<i>Cutthroat trout</i>	skeletal muscle
<i>Myxoboluselipsoides</i>	AF085178	<i>Rutilusrutilus</i>	Gills
<i>Myxobolusalvarezae</i>	FJ716097	<i>Aspiusaspius</i>	Gills filament
<i>Myxoboluscyprini</i>	AF380140.	<i>Cyprinuscarpio</i>	-
<i>Myxobolusleuciscini</i>	DQ439811	<i>Chub</i>	Interbranchial filament
<i>Myxobolusbasilamellaris</i>	AF507971	<i>Cyprinuscarpio</i>	-
<i>Myxoboluspseudodispar</i>	EF466088	<i>Tubifex</i>	Gills
<i>Myxobolusmeerutensis</i>	KM029977	<i>Labeorohita</i>	Gills lamellae
<i>Myxobolusbasuhaldari</i>	KM029975	<i>Labeorohita</i>	Gills lamellae
<i>Myxoboluskalavatieae</i>	KM029973	<i>Cirrhinuscirrhosus</i>	Gills lamellae
<i>Myxobolusbhadrensis</i>	KM029972	<i>Catlacatla</i>	Muscle
<i>Myxoboluscatlae</i>	KM029967	<i>Cirrhinuscirrhosus</i>	Gills lamellae
<i>Myxobolusfeisti</i>	EU598804	<i>Rutilusrutilus</i>	Gills filament cartilage
<i>Myxobolusintimus</i>	JF311899	<i>Aspiusaspius</i>	Capillaries of gill lamellae
<i>Myxoboluselegans</i>	JN252485	<i>Leuciscusidus</i>	Branchial artery
<i>Myxobolus spp.</i>	This study	<i>Oreochromis niloticus</i>	Retina of eye
<i>Lernaecyprinacea</i>	KP235363.1 (out group)	<i>Plecoglossusaltivelis</i>	skin

DISCUSSION

In general, when parasites invaded the host vital organs it is either destroy the tissue or utilize the nutrient in all tissue organs of fish which eventually ended with the massive death as recorded in the case history of the present study. Recently, the most advanced techniques used for detection of the destructive effect of fish parasites is mainly depend on the fact that the presence of parasite in aquatic organisms would result in a change biochemical and normal histological structure of the affected organ showing a certain cellular response that differs from an organ to another. This fact stimulated the idea of studying different biological markers to evaluate the condition of infected hosts (**Vasilyeva et al., 2010**).

The most important result obtained from the present study indicated that myxobolus infestation would associate with normalization of GST activity although GST was considered as an important indicator for hepatic damage in some mammalian species as recorded in mice artificial hydatid infestation (**Gollapudi and Vivekavardhani, 2013**). The non-significant change in the current study may be due to the level of damage in these organs did not stimulate GST enzyme. On the other hand, a study performed by **Frank et al., (2011)** clarified that experimental infection of *Schistocephalus solidus* and *Ligula intestinalis*, cestode parasites, decreased GST activity in three fish species which suggested that the trend of GST activity in wild and induced infection showed a different manner due to increase resistance to oxidative stress.

Liver and gills SOD activity was showing a significant decline by nearly 2 fold after myxobolus infestation which suggested the use of SOD activity in those organs as an effective biomarker for myxosporeidiosis in *O. niloticus*. It was claimed by several authors that oxidative stress weakens the ability of hepatic and branchial tissues of Nile tilapia in enhancing SOD activity. **Skuratovskaya et al., (2013)** discovered that hepatic SOD activity in Black Sea Whiting (*Merlangius merlangus*) showed a significant decrease after experimental infection with myxosporean parasite which was suggested to be due to the production of free radicals from macrophage to defeat the invaded parasites. In fact, the presence of parasite inside living organisms is eventually accompanied with a significant increase in reactive oxygen species production which mainly performed a deleterious effect on anti-oxidant status of living organisms (**Martinez-Alvarez et al., 2005**). From this point, it could be suggested that hepatic and gills SOD was a biomarker for Myxobolus infection in Nile tilapia of the present study. The levels of nitrosative stress were determined by measuring the concentration of nitric oxide, which is increased in tissues of spleen and gills revealing the sensitivity of both tissues for nitrosative stress performed by myxosporeidiosis infection. In rainbow trout, the expression levels of nitric oxide synthetase revealed a significant up-regulation after the exposure to *Myxobolus cerebralis* (**Severin et al., 2010**). In sea bream, **Golomazou et al., (2006)** said that *Enteromyxum leei* a Myxosporean parasite caused an increase in nitric oxide production in host tissues. The increase in nitric oxide concentration was showing high levels in spleen due to the over

expression of inducible NOS in these tissues in hybrid tilapia (Wang et al., 2007). In the same manner, the elevation of nitric oxide concentration in gills of fish was mainly attributed to the over-expression of neuronal NOS in these tissues which would result in an increase in nitric oxide production (Hyndman et al., 2006).

From the presented results, there was no doubt that parasitic infestation produced huge and different responses from tissues through the production of reactive oxygen species that depresses the anti-oxidant defense system of the tissues. One of the most common free radicals is hydrogen peroxide which was found to be significantly increased after exposure to myxosporidiosis infestation. Similar result was also observed in *Plasmodium falciparum* as Atamna and Ginsburg, (1993) found an elevation in both catalase and hydrogen peroxide activity and concentration, respectively after *Plasmodium falciparum* infection. The result of this study revealed that the hydrogen peroxide production in liver, spleen and muscle was increased approximately by 1.5 fold which could be used as a biomarker for myxoboliasis infestation in *O. niloticus*

The level of lipid peroxidation was used before as a biomarker for parasitic infestation in case of *Dactylogyrus* spp. infestation in gold fish (Mozhdeganloo and Heidarpour, 2014), *Raphidascarisacus* in Yellow perch (Marcogliese et al., 2005) and *Ornithodiplostomum* spp. in fat head minnows (Stumbo et al., 2012). The continuous exposure of fish to multiple stressors executed by parasitism would eventually result in production of oxidative stress that lead to lipid peroxidation and the increase of the concentration of

Malondialdehyde concentration in tissues of fish (Di Giulio et al., 1989).

The cellular damages of organs affected by myxobolus spp. were more specific in intestinal, liver and eye of all affected species of *O. niloticus*. In intestine, a desquamation of epithelial lining with invasion with eosinophilic granular cells was spread in the epithelial lining of intestine. In a study performed by Molnar, (2002) in common carp, *Myxobolus cyprinicola* invaded lamina propria of small intestine which appeared as a thick walled spherical plasmodia attached to mucosal fold of intestine, while the myxobolus spp. isolated in this study was appeared as elliptical body with different developmental stages scattered in the epithelial lining of intestine. In the same respect, *M. nodulointestinalis* was occupied the muscular layer of *Barbus sharpeyigut* in the form of large plasmodia (Masoumian et al., 1996). It was also described by Ali et al., (2002) that *Barbus bynni* was infested by oval shaped *Myxobolus intestinalis* infiltrated the circular muscular layer of the fish gut without the presence of developmental stages in intestine. In general, the localization of Myxobolus Spp. in intestinal epithelium differed from one host to another. In eyes, a cyst containing different developmental stages of myxobolus spp. was found in peri-orbital tissues. Similar result was obtained by Eissa et al., (2006), whom found the presence of Myxobolus cyst around the iris of the eye on *O. niloticus*. In liver, the most prominent pathological lesion was the infiltration of hepatic parenchyma, portal vein, hepatopancreas and blood vessels with eosinophilic granules which was also observed in stomach and intestinal epithelium in Indian major carpafter myxosporidiosis infestation. It was believed that the invasion of eosinophilic

granules in host tissue suggested its importance role in immunity against parasites which revealed the host response in defense against *Myxobolus* infestation (Dezfuli et al., 2004).

Molecular and morphological analysis of the myxobolus identified in the current study indicated that there was an identity by 90% with *Myxobolus kisutchi* after performing Basic Local Alignment Search Tool (blast) for the isolated sequence. The discrimination of every myxobolus and the other was occurred through the site of entry and the basic morphological characters that recently accompanied with molecular identification through 18S subunit (Ferguson et al., 2008). The phylogentic analysis that obtained from neighbor joining analysis revealed the presence of three obvious clades. The first clade was consisted of most of the listed myxobolus species used in the phylogentic analysis which was restricted to gills lamellae and only one species that was restricted only in muscle (*Myxobolus bhadrensis*). The second clade called aneurotropism clade that consisted of *Myxobolus kisutchi* and the identified sequence of this study. The last clade was named as muscular tropism clade that contained two species *Myxobolus fryeri* and *M. insidiosus*. The sequenced species of *Myxobolus* was showing a high identity percentage with *Myxobolus kisutchi*. *Myxobolus* infestation is characterized by its tissue tropism which separates the different myxobolus infestation into different clades according to the site of invasion. *Myxobolus fryeri* and *M. insidiosus* infested muscular tissue while *Myxobolus kisutchi* invaded the nervous tissue (Hogge et al., 2004). In the current study, the identified species of *Myxobolus* was isolated from the

eyes of *O. niloticus* in retina of the eye which related to nervous tissues.

The traditional parasitological techniques applied for diagnosis of myxosporideae were always thought as effective tool for diagnosis due to the diversity of spore morphology. However, the discrimination between different species of myxobolus with the aid of spores' morphology was considered a difficult task as several species of myxobolus shared the same spores shape and diameter (Ferguson et al., 2008). The use of molecular biological studies in the diagnosis of myxobolus was always the technique of choice especially when 18S ribosomal subunit gene was used for diagnosis because of high diversity of this gene among closely morphological related species of myxobolus (Kent et al., 2001). The small ribosomal subunit gene was also used to differentiate between the same species infested different hosts as *M. articus* affected sockeye Salmon in Columbia was showing a different sequence from *M. articus* infested the same species in Japan recorded by Andree et al., (1999)

CONCLUSION

It could be concluded from the result of this study that superoxide dismutase, Nitric oxide and Malondialdehyde showed an observed elevation which reinforced the fact of use these parameters in biomonitoring of myxobolus infestation in *Oreochromis niloticus*, while SOD activity revealed a significant decline due to the production of reactive oxygen species inactivated its action. The histopathological examination revealed an infiltration of intestinal, hepatic and periorbital

region with myxobolus bear shaped plasmodia with different developmental stages accompanied with eosinophilic granular cells that have an essential role in host immunity. The phylogenetic analysis showed that the identified species of Myxobolus was revealed a low genetic distance as well as a high identity percentage with *Myxobolus kisutchi* which clarified the tissue tropism of myxobolus infestation for each species.

REFERENCES

- Abdel-Ghaffar, F., El-Toukh, A., Al-Quraishy, S., Al-Rasheid, K., Abdel-Baki, A.S., Hegazy, A., Bashtar, A.R., 2008.** Five new myxosporean species (Myxozoa: Myxosporidia) infecting the Nile tilapia *Oreochromis niloticus* in Bahr Shebin, Nile Tributary, Nile Delta. Egypt. Parasitol. Res. 103, 1197–1205.
- Ali, M.A., Khaled A.S., Al-Rasheid, Thabit Sakran, Abdel-Azeem Abdel-Baki, Fathy A., Abdel-Ghaffar (2002):** Some species of the genus *Myxobolus* (Myxozoa: Myxosporidia) infecting freshwater fish of the River Nile, Egypt, and the impact on their hosts. Parasitol Res. 88: 9-15
- Andree, K. B., et al. "Relationships among members of the genus *Myxobolus* (Myxozoa: Bilvalvidae) based on small subunit ribosomal DNA sequences." *The Journal of parasitology* (1999): 68-74.
- Atamna H1, Ginsburg H.(1993):** Origin of reactive oxygen species in erythrocytes infected with *Plasmodium falciparum*. Mol Biochem Parasitol. 1993 Oct;61(2):231-41.
- Banudevi S, Krishnamoorthy G, Venkataraman P, Vignesh C, Aruldhas MM, Arunakaran J. 2006. Role of alpha-tocopherol on antioxidant status in liver, lung and kidney of PCB exposed male albino rats. Food Chem Toxicol 44:2040–2046.
- Bello A. R. R., Fortes E., Bello-Klein A. A. (2000):** Lipid peroxidation induced by *Clinostomum truncatum* in muscle of the freshwater fish *Rhamdia quelen* // Dis. Aquat. Org. 42. 233:236.
- Bentz CR1, Hogge CI, Meyers TR, Ferguson JA. (2012):** *Myxobolus neurotropus* infecting rainbow trout in Alaska, a new geographic record. J Aquat Anim Health. 24(4):225-31.
- Camus AC1, Griffin MJ., (2010):** Molecular characterization and histopathology of *Myxobolus koi* infecting the gills of a koi, *Cyprinus carpio*, with an amended morphological description of the agent. J Parasitol. 96(1):116-24.
- CARLA HOGGE, MATTHEW CAMPBELL AND KEITH JOHNSON (2004):** Discriminating between a Neurotropic *Myxobolus* sp. and *M. cerebralis* the Causative Agent of Salmonid Whirling Disease. Journal of Aquatic Animal Health. 16:137–144.
- Dezfuli, B. S., L. Giari, E. Simoni, A. P. Shinn, G. Bosi., (2004):** Immunohistochemistry, histopathology and ultrastructure of *Gasterosteus aculeatus* tissues infected with *Glugea anomala*. Diseases of aquatic organisms. Vol. 58: 193–202
- Di Giulio RT, Meyer JN (2008)** Reactive oxygen species and oxidative stress. In: Di Giulio RT, Hinton DE (eds) The Toxicology of Fishes. CRC Press Taylor

- and Fran-cis Group, New York, pp 273–324
- Dudin A. S.** Modern state of the level of being studied of life cycle of the Phylum Myxozoa representatives Parasitologiya.2010 (44), 3-262—272.
- Eissa, I.A.M., 2002.** Parasitic fish diseases in Egypt. Dar El-Nahda El-Arabia Publishing, 32 AbdEl-KhalekSt.Cairo, Egypt.
- Eissa A. E., I.M.K. Abu Mourad, T. Borhan (2006):**A contribution on myxosoma Infection in Cultured Oreochromis niloticus in Lower Egypt. Nature and science.4(4).40-46.
- Ferguson, Jayde A., et al.** "Molecular and morphological analysis of Myxobolus spp. of salmonid fishes with the description of a new Myxobolus species." *Journal of Parasitology* 94.6 (2008): 1322-1334.
- Fossati P, Prencipe L. Serum triglycerides determined colorimetrically with an enzyme that produces hydrogen peroxide. *ClinChem* 1982;28:2077-2080.
- Frank, S., Faust, S., Kalbe, M., Trubiroha, A., Kloas, W. and Sures, B., (2011)** Fish hepatic glutathione-S-transferase activity is affected by the cestode parasites *Schistocephalus solidus* and *Ligula intestinalis*: evidence from field and laboratory studies. *Parasitology*, 138, 939-944.
- Gollapudi VK and Vivekavardhani V (2013).** Effect of ancylostomiasis on liver protein, amino acids and gst (glutathione - s - transferase) level in male swiss albino mice. *The bioscan*, 8(2): 459–462.
- Gridley MF (1960).**Manual of Histologic and Special Staining Technique 2 edn.,McGraw-Hill Book Company.USA. pp. 28-31, 82-83.
- Habig, W.H., Pabst, M.J., Jakoby, W.B., 1974.** Glutathione S-transferases.The first enzymatic step in mercapturic acid formation.*J BiolChem* 249, 7130-7139.
- Kelly A. Hyndman, Keith P. Choe, Justin C. Havird, Rachel E. Rose, Peter M. Piermarini and David H. Evans 2006:** Neuronal nitric oxide synthase in the gill of the killifish, *Fundulus heteroclitus*. *Comparative Biochemistry and Physiology, Part B* 144, 510–519.
- Kent ML, Andree KB, Bartholomew JL, El-Matbouli M, Desser SS, Devlin RH, Feist SW, Hedrick RP, Hoffmann RW, Khattra J, Hallett SL, Lester RJG, Longshaw M, Palenzeula O, Siddall ME, Xiao C (2001)** Recent advances in our knowledge of the Myxozoa. *J EukaryotMicrobiol* 48(4):395–413.
- Kent, M. L. "Review of Myxosporea of importance in salmonid fisheries and aquaculture in British Columbia." *Folia Parasitologica* 41 (1994): 27-37.**
- Lom J., Dykova I. Myxozoan genera: definition and notes on taxonomy, life-cycle terminology and pathogenic species // *Folia Parasitologica*. – 2006. – 53. – P. 1—36.
- Marcogliese DJ, Brambilla LG, Gagne F, Gendron AD (2005)** Joint effects of parasitism and pollution on oxidative stress biomarkers in yellow perch *Perca flavescens*. *Dis Aquat Org* 63:77–84
- Martinez-Alvarez R. M., Morales A. E., Sanz A. (2005):** Antioxidant defenses in fish: biotic and abiotic factors.

Reviews in Fish Biology and fisheries.15.75:88.

Masoumian M., Baska F., Molnar K. (1996) *Myxobolus nodulointestinalis* sp. n. (Myxosporidia, Myxobolidae), a parasite of the intestine of *Barbus sharpeyi*. Dis. Aquat. Org.24:35-39.

Molnar, K., (2002): Redescription and Histopathology of *Myxobolus cyprinicola* Reuss, 1906, an Intestinal Parasite of the Common Carp (*Cyprinus carpio* L.). Acta Protozool. 41: 279 – 283

Montgomery, H., Dymock, J., 1961. Determination of nitrite in water. ROYAL SOC CHEMISTRY THOMAS GRAHAM HOUSE, SCIENCE PARK, MILTON RD, CAMBRIDGE CB4 0WF, CAMBS, ENGLAND, pp. 414.

Mozhdeganloo, Z. and M. Heidarpour (2014): Oxidative stress in the gill tissues of goldfishes (*Carassius auratus*) parasitized by *Dactylogyrus* spp. J Parasit Dis. 38(3):269–272.

Nishikimi M., Roa N. A. and Yogi K. (1972): The occurrence of superoxide anion in the reaction of reduced phenazinemethosulfate and molecular oxygen. Biochem. Biophys. Res. Commun., 46, 849 – 854.

Rudneva I. I., Zavyalov A. V., Skuratovskaya E. N. The role of molecular systems in protective reactions of fish infected by parasites // Ryb. gosp-vo Ukraini. – 2010. – N 1. – P. 2—6.

Sahoo, P.K., S.C. Mukherjee, S.K. Nayak and S. Dey., (2000): Pathology of mixed infections of saprolegniasis-myxosporidiosis in Indian major carp (*Catla catla* Ham.). Bangladesh J. Fish. Res., 4(2), 171-177

Sambrook J, Fritsch EF and Maniatis T (1989) *Molecular cloning: a laboratory manual*, Cold Spring Harbor Laboratory Press, New York.

Scholz T (1999): Parasites in cultured and feral fish. Vet Parasitol 84:317–335.

Severin VI, Soliman H & El-Matbouli M. Expression of immune-regulatory genes, arginase-2 and inducible nitric oxide synthase (iNOS), in two rainbow trout (*Oncorhynchus mykiss*) strains following exposure to *Myxobolus cerebralis*. Parasitol Res 2010;106:325–334.

Skuratovskaya, E. N., V. M. Yurakhno, and A. V. Zavyalov. "The Influence of Parasitic Infection on the Black Sea Whiting, *Merlangius merlangus* (Gadidae), Morphophysiological and Biochemical Parameters." *Vestnik zoologii* 47.4 (2013): 309-317.

Stumbo AD, Goater CP, Hontela A (2012) Parasite-induced oxidative stress in liver tissue of fathead minnows exposed to trematode cercariae. Parasitol 139:1666–1671

Tamura K, Stecher G, Peterson D, Filipowski A, and Kumar S (2011) MEGA5: Molecular Evolutionary Genetics Analysis version 5 Molecular Biology and Evolution: 28 2731-2739.

Tiago Milanin, Jorge C Eiras, Sarah Arana, Antônio AM Maia, Anderson L Alves, Márcia RM Silva, Mateus M Carriero, Paulo S Ceccarelli, Edson A Adriano (2010): Phylogeny, ultrastructure, histopathology and prevalence of *Myxobolus liveirai* sp. nov., a parasite of *Brycon hilarii* (Characidae) in the Pantanal wetland, Brazil. Mem Inst Oswaldo Cruz, Rio de Janeiro, Vol. 105(6): 762-769.

Vasilyeva O. B., Lavrova V. V., Ieshko E. P., Nemova N. N. (2010): Changes in lipid composition of burbot *Lota lota* (L.) liver under invasion by plerocercoids *Triaenophorus nodulosus*. Vol. 1. *Ecologicheskaya fiziologiya i biohimiya vodnykh organizmov*—Petrozavodsk: Karelsky Nauchny Center RAS, 2010. — P. 20—23.

Wang WS, Hung SW, Lin YH, Tu CY, Wong ML, Chiou SH, Shieh MT,

(2007): Purification and localization of nitric oxide synthases from hybrid tilapia (Nile tilapia x Mozambique tilapia). *J Aquat Anim Health*. 19(3):168-78.

Yoshioka T., Takehara Y., Shimatani M., Abe K. and Utsumi K. (1982): Lipid Peroxidation and Antioxidants in Rat Liver during Development. *The Tohoku Journal of Experimental Medicine* Vol.137, No.4. Pp. 391-400.

الملخص العربي مرض الميكسوسبورديا في أسماك الباطى النيلي: التشخيص الجزيئي وإستخدام الدلائل الأكسدة

*نفين كامل محمد عبدالخالق، **محمد على ماهر العدل، ***محمد فوزى حامد، ****مصطفى العربي

* قسم الأمراض الباطنة والمعدية والأسماك، كلية الطب البيطري- جامعة المنصورة
** قسم الكيمياء الحيوية وكيمياء التغذية- كلية الطب البيطري- جامعة المنصورة
*** قسم الباثولوجيا- كلية الطب البيطري- جامعة المنصورة
**** قسم الطفيليات- كلية الطب البيطري- جامعة المنصورة

مرض الميكسوسبورديوزس من أمراض الأسماك الطفيلية التي تسبب الأضرار في أجهزة الأسماك ويمكن أن ينتهي في نهاية المطاف مع وفيات وتدهور نوعية اللحوم الأسماك المتضررة. وعادة ما يصاحب وجود الإصابة الطفيلية في إنتاج أنواع الأكسجين والنيروجين التفاعلي الذي ينتج ضرر اضافي وتعطيل نظام الدفاع المضادة للأكسدة التي تزيد من شدة الإصابة الطفيلية. في الآونة الأخيرة، استجابة الأنسجة المصابة إلى الأكسدة تختلف على حسب نوع من الطفيل. وبالتالي فإن استخدام علامات الإجهاد التأكسدي كمؤشر للإصابة أصبح مهما. في هذه الدراسة، تم تجميع أسماك الباطى النيلي و قياس علامات الإجهاد التأكسدي (GST) ، أكسيد النيتريك، NO فوق أكسيد الهيدروجين و (MDA) في الكبد والعضلات والطحال والخياشيم في الاسماك المصابة والغير مصابة. تم إجراء فحص الأنسجة لتوضيح الإصابة الخلوية . وأشارت النتائج إلى أن كان هناك تغيير غير ملحوظ في النشاط GST في جميع الأجهزة، في حين انخفض نشاط (SOD) في الكبد والخياشيم في الاسماك المصابة. وقد زاد تركيز أكسيد النيتريك، بيروكسيد الهيدروجين، وبيروكسيد الدهون بشكل ملحوظ في (الخياشيم والطحال)؛ (الكبد والطحال والعضلات). (الكبد والعضلات)، على التوالي. أظهر الأمعاء و عيون السمك تأثر التغيرات التنكسية واستبدال الأنسجة الظهارية بجراثيم الميخوط مع حبيبات الايزينو فيل التي لها دور في مناعة ضد الطفيل وأوضح تحليل h الجزيئي أظهرت أن الأنواع التي يتم تحديدها من لى وقد كشفت الدراسة وجود علاقة وثيقة وكذلك نسبة عالية الهوية مع، و الأنسجة مماثل الذي سلط الضوء على استخدام كل من تحديد والاكسدة الواسمات الجزيئية للتشخيص الميخوط الإصابة في السمك الميت عند فحص الطفيليات وحده يصبح عدم كفاية الكشف من الميخوط الإصابة.