

# Effect of calcium acetate and quercetin on gentamicin-induced nephrotoxicity in rat

Sawsan M. El-Sheikh, Naglaa Z. H. Eleiwa, and Heba A. Nazim\*

Department of Pharmacology, Faculty of Veterinary Medicine, Zagazig University  
Department of Pharmacy Inspection, Health administration, Menia El-Kamh, Sharkia province

## ABSTRACT

**Objective:** The present work was conducted to evaluate the possible renoprotective effect of both calcium acetate and quercetin against gentamicin-induced nephrotoxicity in rat.

**Design:** Controlled study.

**Animals:** Seven groups of male albino rats.

**Procedures:** Seventy, apparently healthy, male albino rats were haphazardly divided into seven equal groups. Group 1: injected I.P with normal saline (control), Group 2: received gentamicin (80 mg/kg/d, I.P for 7 consecutive days), Group 3: received gentamicin plus lower dose of calcium acetate (75 mg/kg/d, orally for 7 consecutive days) simultaneously, Group 4: received gentamicin plus higher dose of calcium acetate (200 mg/kg/d, orally for 7 consecutive days) simultaneously, Group 5: received gentamicin; afterwards, rats were treated with quercetin (50 mg/kg/d, orally for 7 consecutive days), Group 6: received quercetin; afterwards, rats were simultaneously treated with gentamicin plus quercetin with the same doses, and Group 7: received gentamicin, calcium acetate (lower dose), and quercetin simultaneously.

**Results:** The study demonstrated the nephrotoxic impacts of gentamicin biochemically and histopathologically. Gentamicin treatment induced a significant increase in blood urea nitrogen (BUN) and serum creatinine levels besides a significant elevation in C-reactive protein (CRP) level. The significant increase in the tissue malondialdehyde (MDA) level and the significant reduction in the tissue superoxide dismutase (SOD) and glutathione (GSH) levels demonstrated that gentamicin-induced nephrotoxicity was mediated through oxidative stress reactions. Gentamicin-induced degenerative changes in renal tubules and glomeruli were also reported.

**Conclusion and clinical relevance:** The use of both calcium acetate (lower and higher doses) or quercetin (therapeutically and prophylactically) in combination with gentamicin significantly minimized its nephrotoxicity as revealed from decreasing BUN, serum creatinine, CRP levels, oxidative stress reactions, and histopathological alterations with better protective effect of quercetin than Ca acetate. Co-administration of both calcium acetate and quercetin with gentamicin could prevent gentamicin-induced nephrotoxicity.

**Keywords:** Nephrotoxicity, Gentamicin, Calcium acetate, Quercetin, and Rats

## 1. INTRODUCTION

Gentamicin, a potent aminoglycoside antibiotic used against severe Gram-negative bacterial infections, is well known to produce nephrotoxicity even in therapeutic doses in both humans and animals (Sardana et al., 2015). It is one of the common causes of drug-induced acute kidney injury (AKI) in hospitalized patients (Singh et al., 2012). It is commonly used because of its rapid concentration-dependent bactericidal effects, synergism with beta-lactams, low resistance, and particularly low-cost (Leekha et al., 2011). In clinical settings, AKI is characterized by elevated BUN and serum creatinine levels (Balakumar et al., 2017), elevated CRP, and alteration in oxidative/antioxidative status biomarkers in form of elevated MDA and reduced SOD, and GSH, activities (Casanova et al., 2017). Gentamicin-administered rats showed

acute tubular degeneration and necrosis in the epithelial lining of the renal cortex, besides glomerular atrophy, and peritubular fibrosis (Derakhshanfar et al., 2015).

Throughout the past decade, several strategies have been adopted, with varying degrees of success, in an attempt to protect or reverse gentamicin nephrotoxicity (Dontabhaktuni et al., 2016). Two general clinical strategies have been adopted, the first strategy involves reducing drug accumulation in the kidney via, for example, inhibition of gentamicin binding to renal brush border membranes, the initial site of interaction between gentamicin and renal proximal tubule cells, as in case of calcium co-administration (Pannu and Nadim, 2008). The second strategy relies on co-administration of renoprotective compounds, including natural antioxidants which seem to possess the highest

nephroprotective potential for use in the clinic (Casanova et al., 2017). Quercetin, a potent bioactive flavonoid, has been recognized to possess a variety of biological and pharmacological activities, including antioxidant, anti-inflammatory, and anti-allergic activities that are probably involved in its nephroprotective effect (Gupta et al., 2016).

Proceeding from the above, our study aimed at exploration of the alleged ameliorative effect of both calcium acetate and quercetin on gentamicin-induced acute nephrotoxicity depending upon their different mechanisms of action on the renal tissues, comparing the effects of different dosages of calcium and different administration regimen of quercetin on gentamicin-induced nephrotoxicity in rats.

## 2. MATERIALS AND METHODS

### 2.1. Drugs and Chemicals

Gentamicin sulfate was obtained from El Nasr Pharm. and Chem. Co., (Cairo, Egypt). Calcium acetate was obtained from Marcyrl Pharm. Ind., (Cairo, Egypt). Quercetin was supplied from Sigma Chemical Co. (St. Louis, MO, U.S.A.). All other chemicals used were of the highest analytical grade commercially available.

### 2.2. Animals

Seventy, apparently healthy, male albino rats weighing 150- 200 gm were used in this study. They were acquired from the Laboratory Animal's Farm, Faculty of Veterinary Medicine, Zagazig University. They were caged in wire bottom galvanized metal wall under hygienic conditions. They were fed on a balanced ration and fresh tap water ad libitum throughout the experimental period. Housing and management of animals were conducted as stipulated in the guide for the care and the use of lab. Animal's guidelines of the national institute of health (NIH) and approved by local authorities of Zagazig University, Egypt. They were acclimatized for 14 days prior to inclusion in the study.

### 2.3. Experiment Protocol

Rats were randomly divided into 7 equal groups each of 10 rats. Group 1: injected I.P with normal saline (control), Group 2: received gentamicin (80 mg/kg/d, I.P for 7 consecutive days), Group 3: received gentamicin plus lower dose of calcium acetate (75 mg/kg/d, orally for 7 consecutive days) simultaneously, Group 4: received gentamicin plus higher dose of calcium acetate (200 mg/kg/d, orally for 7 consecutive days) simultaneously, Group 5: received gentamicin; afterwards, rats were treated with quercetin (50 mg/kg/d, orally for 7 consecutive days), Group 6: received quercetin; afterwards, rats were simultaneously treated with gentamicin plus quercetin, and Group 7: received gentamicin, calcium acetate (lower dose), and quercetin simultaneously with same previously mentioned doses.

### 2.4. Samples collection and preservation

By the end of the study, rats were sacrificed; blood samples were collected into centrifuge tubes and left to clot then centrifuged at 3000 rpm for 10 minutes to allow serum separation which then aspirated into cryovials and stored at -20°C for biochemical assays (BUN, creatinine, and CRP). The kidneys of each rat were dissected out and divided into two parts. Regarding the first part; kidneys were stored at -20°C and used to measure MDA, SOD, and GSH levels. Regarding the second part, kidneys were immediately fixed in 10% buffered neutral formalin solution for histopathological examination.

### 2.5. Biochemical Analysis

#### 2.5.1. Biochemical measurement in sera

BUN and serum creatinine levels were estimated using specific Pointe® scientific inc. kit (Fawcett and Scott, 1960 and Young et al., 1975 respectively). Estimation of CRP level was carried out using Abcam® CRP ELISA kit (Helgeson et al., 1973).

#### 2.5.2. Biochemical measurement in kidney tissues

Renal tissue MDA, SOD, and GSH levels were estimated using highly sensitive ELISA kits (MDA Oxi Select™ kit, SOD Oxi Select™, and GSH Cayman® Chemical Company kit, respectively (Esterbauer et al., 1991; Misra and Fridovich, 1972; and Tietze, 1969 respectively).

### 2.6. Histopathological examination

Formalin-fixed renal tissues were trimmed, washed in distilled water, dehydrated in ascending grades of alcohol, cleaned in xylene, impregnated in paraffin, embedded and blocked out, sectioned (4-6 micron thickness), and stained with Hematoxylen and Eosin (H&E) for histopathological examination (Bancroft et al., 1996).

### 2.7. Statistical analysis

The obtained data were analyzed statistically using SPSS one-way ANOVA (SPSS ver. 22) followed by the post hoc Duncan's new multiple range test (MRT) for multiple comparisons of means in order to determine the between-group differences. Statistical significance was set at  $p < 0.05$ .

## 3. Results

### 3.1. Biochemical Analysis

#### 3.1.1. Biochemical measurement in sera

Results of the effect of calcium acetate and quercetin on BUN, serum creatinine, and CRP, levels were illustrated in Table 1. From that table, we noticed that gentamicin

administration produced significant elevations ( $P<0.05$ ) in BUN, serum creatinine, and CRP levels compared with control group. Concomitant oral administration of graded doses of calcium acetate (lower and higher) plus intraperitoneal gentamicin treatment produced a significant dose-dependent improvement ( $P<0.05$ ) in BUN, serum creatinine, and CRP levels compared with the gentamicin-treated group. Oral administration of quercetin (therapeutically and prophylactically) produced a significant improvement ( $P<0.05$ ) in BUN, serum creatinine, and CRP levels compared with gentamicin-treated group. Therapeutic oral administration of quercetin showed more significant reduction in kidney function alterations. Concomitant administration of gentamicin, calcium acetate (lower dose), and quercetin could significantly ( $P<0.05$ ) prevent kidney function alteration when compared with rats received gentamicin alone. In fact, such prophylactic regimen showed non-statistical significance compared to untreated control rats indicating regaining normal kidney function.

**Table 1.** Effects of gentamicin sulfate (80 mg/kg/d/for 7 successive days intraperitoneally), calcium acetate (graded doses for 7 successive days orally), and quercetin (50 mg/Kg/for 7 successive days orally) on kidney function tests (BUN, Creatinine) and Inflammation marker (CRP) in male albino rats. Data are expressed as mean  $\pm$  SD, n = 10/group.

Groups	Kidney function tests		CRP (ng/ml)
	BUN (mg/dl)	Creatinine (mg/dl)	
1	13.81 $\pm$ 3.51 <sup>f</sup>	0.68 $\pm$ 0.05 <sup>f</sup>	63.60 $\pm$ 5.41 <sup>a</sup>
2	41.54 $\pm$ 2.14 <sup>a</sup>	2.02 $\pm$ 0.09 <sup>a</sup>	126.60 $\pm$ 5.86 <sup>e</sup>
3	34.07 $\pm$ 2.86 <sup>b</sup>	1.71 $\pm$ 0.07 <sup>b</sup>	114.20 $\pm$ 6.14 <sup>d</sup>
4	29.21 $\pm$ 2.01 <sup>c</sup>	1.49 $\pm$ 0.15 <sup>c</sup>	93.00 $\pm$ 3.67 <sup>c</sup>
5	20.24 $\pm$ 2.72 <sup>e</sup>	1.10 $\pm$ 0.17 <sup>e</sup>	79.40 $\pm$ 4.83 <sup>b</sup>
6	24.00 $\pm$ 3.62 <sup>d</sup>	1.28 $\pm$ 0.09 <sup>d</sup>	88.60 $\pm$ 5.94 <sup>c</sup>
7	15.73 $\pm$ 2.33 <sup>f</sup>	0.82 $\pm$ 0.12 <sup>f</sup>	69.80 $\pm$ 7.33 <sup>a</sup>

Group (1) injected with normal saline, intraperitoneally for seven successive days (control), Group (2) injected intraperitoneally with 80 mg/kg/d of gentamicin sulfate for seven successive days, Group (3) simultaneously treated with gentamicin sulfate at the same previously mentioned dose and duration plus lower dose of calcium acetate orally for seven consecutive days, Group (4) simultaneously treated with gentamicin sulfate at the same previously mentioned dose and duration plus higher dose of calcium acetate orally for seven consecutive days, Group (5) injected with gentamicin sulfate with the same previously mentioned dose and duration. Afterwards, rats were orally treated with 50 mg/kg/d of quercetin for seven consecutive days, Group (6) treated with quercetin with the same previously mentioned dose and duration. Afterwards, rats were simultaneously treated with of gentamicin sulfate and quercetin at the same previously mentioned dose and duration, and Group (7) simultaneously treated with gentamicin sulfate plus calcium acetate (lower dose) plus quercetin at the same previously mentioned doses and duration. Means carrying different superscripts in the same column are significant at  $p<0.05$ .

### 3.1.2. Biochemical measurement in kidney tissues

Results of the effect of calcium acetate and quercetin on oxidative stress enzymes levels were illustrated in Table 2. From that table, we noticed that gentamicin administration

produced a significant increase ( $P<0.05$ ) in the tissue MDA level and a significant reduction in the tissue SOD and GSH levels compared with the control group.

Concomitant oral administration of graded doses of calcium acetate (lower and higher) plus intra-peritoneal gentamicin treatment produced a significant dose-dependent improvement oxidative/antioxidative status in form of significant reduction ( $P<0.05$ ) in MDA level and significant increase ( $P<0.05$ ) in SOD and GSH levels compared with the gentamicin-treated group. Oral administration of quercetin (therapeutically and prophylactically) produced a significant decrease in ( $P<0.05$ ) in MDA level and significant increase ( $P<0.05$ ) in SOD and GSH levels compared with the gentamicin-treated group. Therapeutic oral administration of quercetin showed a more significant improvement in oxidative/antioxidative status in renal tissue. Concomitant administration of gentamicin, calcium acetate (lower dose), and quercetin could significantly ( $P<0.05$ ) prevent renal oxidative/antioxidative status alteration when compared with rats received gentamicin alone. In fact, such prophylactic regimen showed non-statistical significance compared to untreated control rats indicating regaining normal oxidative/antioxidative status.

**Table 2.** Effects of gentamicin sulfate (80 mg/kg/d/for 7 successive days intraperitoneally), calcium acetate (graded doses for 7 successive days orally), and quercetin (50 mg/Kg/for 7 successive days orally) on kidney tissue oxidative stress/antioxidative status (MDA, SOD, and GSH) in male albino rats. Data are expressed as mean  $\pm$  SE, n = 10/group.

Groups	MDA (nmo/g.tissue)	SOD (ng/ml)	GSH (mmol/g.tissue)
1	51.64 $\pm$ 4.99 <sup>f</sup>	14.82 $\pm$ 0.99 <sup>a</sup>	2.16 $\pm$ 0.45 <sup>a</sup>
2	138.44 $\pm$ 3.24 <sup>a</sup>	2.44 $\pm$ 0.29 <sup>e</sup>	0.69 $\pm$ 0.098 <sup>e</sup>
3	115.38 $\pm$ 6.45 <sup>b</sup>	4.72 $\pm$ 0.78 <sup>d</sup>	0.95 $\pm$ 0.09 <sup>d</sup>
4	102.03 $\pm$ 4.01 <sup>c</sup>	6.26 $\pm$ 0.25 <sup>c</sup>	1.21 $\pm$ 0.12 <sup>c</sup>
5	80.22 $\pm$ 10.47 <sup>e</sup>	9.38 $\pm$ 0.67 <sup>b</sup>	1.83 $\pm$ 0.15 <sup>c</sup>
6	94.22 $\pm$ 2.53 <sup>d</sup>	6.72 $\pm$ 1.69 <sup>c</sup>	1.70 $\pm$ 0.06 <sup>b</sup>
7	58.92 $\pm$ 5.16 <sup>f</sup>	13.76 $\pm$ 1.10 <sup>a</sup>	2.11 $\pm$ 0.45 <sup>a</sup>

Group (1) injected with normal saline, intraperitoneally for seven successive days (control), Group (2) injected intraperitoneally with 80 mg/kg/d of gentamicin sulfate for seven successive days, Group (3) simultaneously treated with gentamicin sulfate at the same previously mentioned dose and duration plus lower dose of calcium acetate orally for seven consecutive days, Group (4) simultaneously treated with gentamicin sulfate at the same previously mentioned dose and duration plus higher dose of calcium acetate orally for seven consecutive days, Group (5) injected with gentamicin sulfate with the same previously mentioned dose and duration. Afterwards, rats were orally treated with 50 mg/kg/d of quercetin for seven consecutive days, Group (6) treated with quercetin with the same previously mentioned dose and duration. Afterwards, rats were simultaneously treated with of gentamicin sulfate and quercetin at the same previously mentioned dose and duration, and Group (7) simultaneously treated with gentamicin sulfate plus calcium acetate (lower dose) plus quercetin at the same previously mentioned doses and duration. Means carrying different superscripts in the same column are significant at  $p<0.05$ .

### 3.1.3. Histopathological examination

Examined renal sections from control group revealed normal histomorphological structure with preserved nephrons, medullary, papillary and pelvic structures (Fig. 1 A, and B). Examined renal sections from gentamicin-treated group revealed shrinkage and lobulation of a moderate number of glomeruli with widening of glomerular spaces and degenerative changes in most of the renal cortical tubules. Marked interstitial nephritis with round cells infiltration was seen. Coagulative necrosis of some renal tubules and renal papillary necrosis with dilated blood vessels stuffed with many leukocytes mainly lymphocytes could be observed (Fig. 2 A, B, and C).

Concomitant oral administration of graded doses of calcium acetate (lower and higher) plus intraperitoneal gentamicin treatment produced a significant dose-dependent improvement in the histopathological picture compared with the gentamicin-treated group. The higher dose of calcium acetate was significantly more efficacious than lower one in normalizing the histopathological alterations in renal tubules and glomeruli. Examined renal sections from group received the lower dose of calcium acetate showed mild lobulation of some glomeruli, degenerative changes in some renal tubules (vacuolar and hydropic degeneration) with necrotic renal tubular epithelium in some of these tubules. Hyaline casts in some tubules and mild perivascular edema together with mild lymphocytic infiltration in renal papillae were also observed (Fig. 3 A, B, C, and D).

Examined renal sections from group received the higher dose of calcium acetate showed apparently normal renal parenchyma with mild degenerative changes in the tubular epithelium and mild dilatation of some tubules beside lymphocytic infiltration in renal papillae (Fig. 4 A, B, and C). Oral administration of quercetin (therapeutically and prophylactically), produced a significant improvement in the histopathological picture alterations compared with the gentamicin-treated group. Therapeutic oral administration of quercetin showed a more significant reduction in histopathological alterations. Examined renal sections from group received quercetin therapeutically revealed apparently normal histomorphological structures with mild degenerative changes in proximal and distal convoluted tubules and cystic dilatation of a moderate number of the collecting tubules. Focal fibrotic area in the renal medulla, especially at the corticomedullary junction, was noticed. Focal regeneration of some renal tubules could also be detected (Fig. 5 A, B, C, and D).

Examined renal sections from group received quercetin prophylactically revealed apparently normal nephron structures, medullary collecting tubules and renal papillae with mild degenerative changes in some tubular epithelium and mild dilatation of some renal tubules (Fig. 6 A, B, and C). Concomitant administration of gentamicin, calcium acetate

(lower dose), and quercetin revealed apparently normal nephron structures, renal papillae and renal pelvis with mild degenerative changes in few number of tubules and glomeruli (Fig. 7 A, and B).

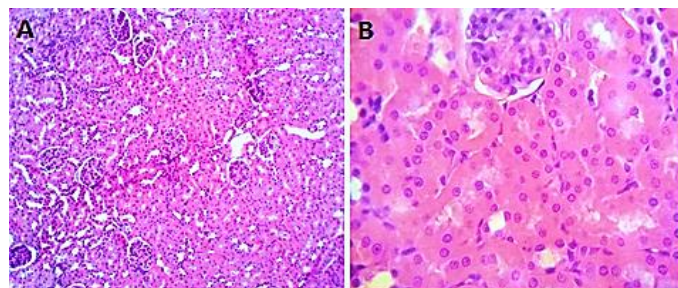


Figure 1. Photomicrograph from kidney group 1 (control) showing normal histomorphological structure, (H&E X 100,400).

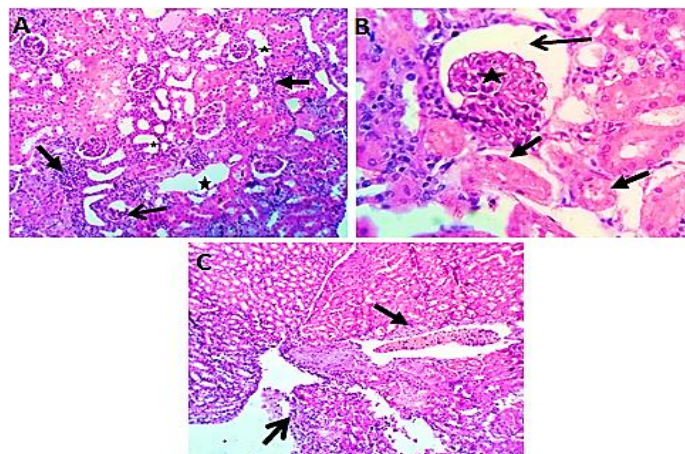
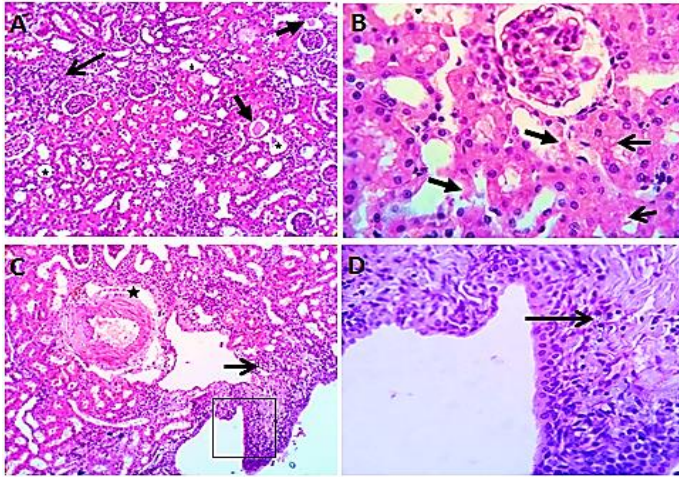


Figure 2. Growth Photomicrograph from kidney (group 2) showing (A) Shrinkage and lobulation of a moderate number of glomeruli (open arrow). Interstitial nephritis with marked round cells infiltration (closed arrow) with dilatation of some renal tubules (star), (B) Coagulative necrosis of some renal tubules (closed arrow) and widening of glomerular spaces (open arrow) with shrinkage and lobulation of a moderate number of glomeruli (star), and (C) Renal papillary necrosis (open arrow) with dilated blood vessels stuffed with many leukocytes mainly lymphocytes (closed arrow), (H&E X 100,400).

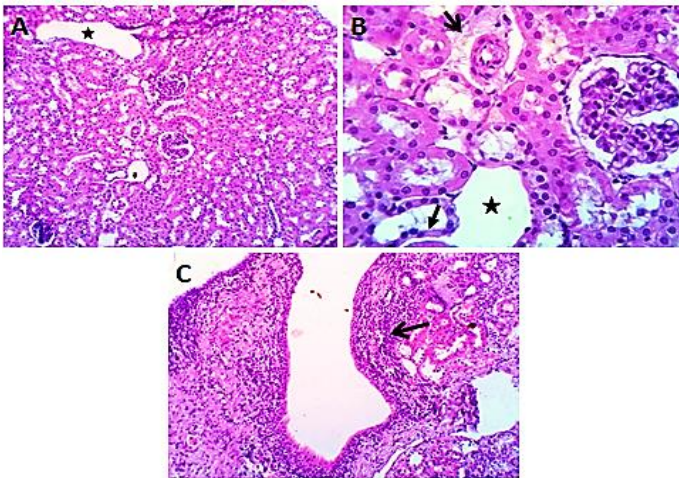
#### 4. Discussion

Gentamicin is a potent aminoglycoside antibiotic against Gram-negative bacterial infection. Unfortunately, nephrotoxicity and ototoxicity represent its main adverse effects that limit its frequent therapeutic use (Sardana et al., 2015). Even at therapeutic doses, about 30% of the patients, undergone gentamicin treatment for more than 7 days, display signs of AKI that usually refers to a sudden reversible decrease in kidney function (Hur et al., 2013). In our work, intraperitoneal gentamicin administration induced nephrotoxicity evidenced by significant elevations in BUN, serum creatinine, and CRP levels compared with the control group. Moreover, the study reported a significant increase in the tissue MDA level and a

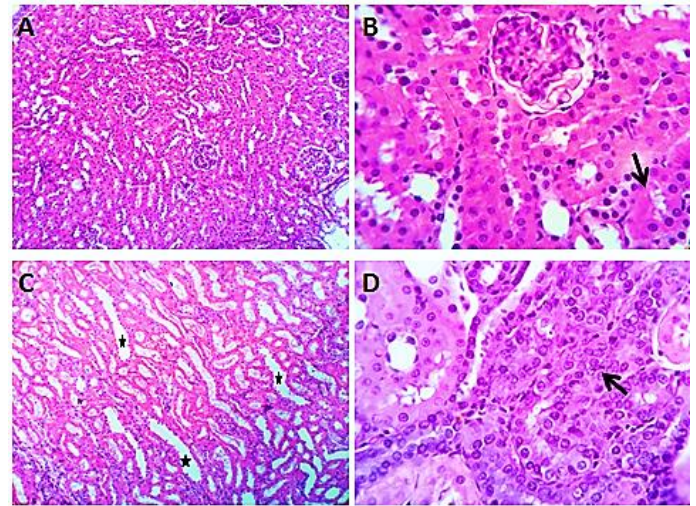
significant reduction in the tissue SOD and GSH level. Degenerative changes in renal glomeruli and tubules were also reported in the gentamicin-treated group.



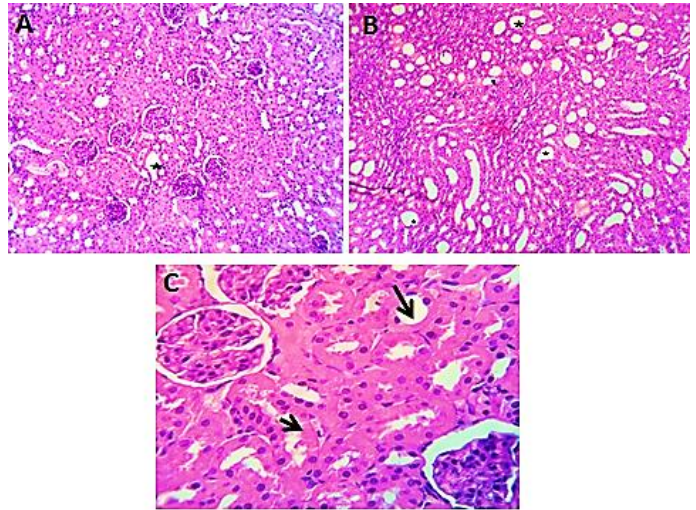
**Figure 3.** Photomicrograph from kidney (group 3,4) showing (A) Interstitial nephritis (open arrow) with tubular hyaline casts (closed arrow),(B) Degenerative changes (vacuolar and hydropic degeneration) (opened arrow) and necrotic renal tubular epithelium (closed arrows),(C) Mild perivascular edema (star) and mild lymphocytic infiltration in renal papillae (open arrow), and (D) mild lymphocytic infiltration in renal papillae (open arrow).H&EX 100,400.



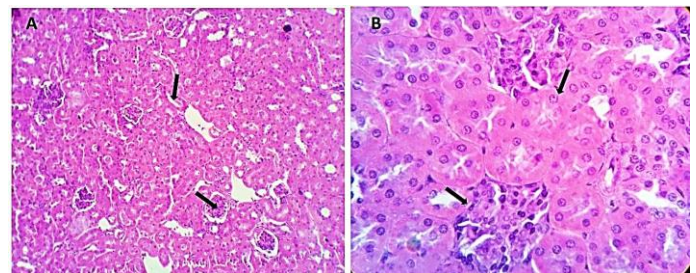
**Figure 4.** Photomicrograph from kidney (group 5,6) showing (A) Apparently normal renal parenchyma with cystic dilatation in some tubules (star),(B) mild degenerative changes (closed arrow) and perivascular edema (open arrow),with cystic dilatation in some tubules (star), and (C) lymphocytic infiltration in renal papillae (open arrow). H&EX 100,400.



**Figure 5.** Photomicrograph from kidney (group 5,6) showing (A) apparently normal nephron structures,(B) Mild degenerative changes in proximal and distal convoluted tubules(open arrow),(C)Cystic dilatation of a moderate number of collecting tubules(stars),and (D)focal regeneration of some renal tubules(open arrow).H&E X 100,400.



**Figure 6.** Photomicrograph from kidney (group 6) showing (A, B, and C) apparently normal renal structures with mild degenerative changes (open arrow) and mild dilatation of renal tubules (stars). H&EX 100,400.



**Figure 7.** Photomicrograph from kidney (group 7) showing (A, and B) apparently normal renal structures with mild degenerative changes in some tubular epithelium (arrow). H&EX 100,400.

The nephrotoxic effect of gentamicin administration was clearly described in many previous studies, manifested by elevation of serum BUN and creatinine levels (Lopez-Novoa et al., 2011; Boroushaki and Sadeghnia, 2015; Balakumar et al., 2017; and Abdelrahman, 2018), elevation of serum inflammation marker (CRP) (Balakumar et al., 2010; El-Ashker et al., 2015; and He et al., 2016), and alteration in oxidative/antioxidative status biomarkers in form of increased MDA and decreased superoxide dismutase (SOD), glutathione (GSH), and catalase (CAT) activities (Abdel-Raheem et al., 2009; Patil et al., 2014; and Casanova et al., 2017). The histopathological alterations reported in this study are consistent with the former studies. Gentamicin-administered rats induced degeneration and necrosis in the epithelial lining of the renal cortex tubules with hyaline casts formation, congestion, and tubular dilation. Interstitial nephritis, glomerular atrophy, and peritubular fibrosis were also reported (Padmini and Kumar, 2012; and Derakhshanfar et al., 2015).

Gentamicin selectively accumulates in the renal proximal convoluted tubule epithelial cells inducing nephrotoxicity. Besides, gentamicin decreases renal blood flow contributing or intensifying its cytotoxicity (Quiros et al., 2010). However, other effects of gentamicin linked to tubular cell death include phospholipidosis, where gentamicin accumulates in cell membranes, binds to membrane phospholipids causing cell membrane structure alterations causing a condition known as phospholipidosis that is tightly related to gentamicin toxicity (Fujiwara et al., 2009). In addition, gentamicin enhances the reactive oxygen species (ROS) production, which is responsible for prompt cell death (Poormoosavi et al., 2010).

Our findings proved that, concomitant oral administration of graded doses of calcium acetate (lower and higher) with intraperitoneal gentamicin treatment produced a significant dose-dependent improvement in the biochemical indices of nephrotoxicity in sera and renal tissue and histopathological picture compared with the gentamicin-treated group. Consistent with Our results, earlier studies proved the protective effect of calcium against gentamicin nephrotoxicity. Calcium chloride co-administration with gentamicin treatment diminished gentamicin plasma levels and the amount accumulated in kidney, thus reducing renal damage and improving renal function (Veyssier and Bryskier, 2005). The ameliorative effect of oral calcium carbonate supplementation simultaneously with gentamicin administration, in form of reduction of kidney functional and histomorphological alterations, was clearly proved (Stojiljkovic et al., 2012; Shoman et al., 2013; and Patil et al., 2014). Calcium dobesilate co-administration with gentamicin significantly ameliorated the biochemical indices in plasma and renal cortex (Jafarey et al., 2014). In our work, we testified the nephroprotective effect of calcium acetate as a new nephroprotective calcium salt. Ca<sup>2+</sup> acetate could also

produce a dose-dependent elaboration in the biochemical indices and histological picture of gentamicin-induced nephrotoxicity.

The mechanism for such protection may be attributed to competitive inhibition of the calcium ions to gentamicin binding to renal proximal tubule, brush border membranes, thus it prevents plasma and subcellular membrane damage (Pannu and Nadim, 2008, and Shoman et al., 2013). Others suggested that the protective action of Ca<sup>2+</sup> might be via enhancing the Ca<sup>2+</sup> solute flux, thereby competitively inhibiting the primary lesion: anionic phospholipid binding (Stojiljkovic et al., 2012) or by enhancing the excretion of gentamicin (Patil et al., 2014).

Our study showed that, oral administration of quercetin (therapeutically and prophylactically) produced a significant improvement in the biochemical indices of nephrotoxicity in sera and renal tissue and reversed most of the histopathological alterations induced by gentamicin treatment. These findings may be in concord with many other studies, which found that antioxidant compounds like quercetin overcame biochemical indices of nephrotoxicity in serum and renal cortex in addition to improvement histopathological picture. Quercetin blocked cellular inflammatory process via reducing mononuclear leucocytes inflammatory cells infiltration and alleviation of glomerular tufts endothelium lining swelling (Eldin et al., 2008; Abdel-Raheem et al., 2009; and Chaudhary et al., 2015). It has been reported that quercetin nephroprotection activity can be attributed to its antioxidant effects by scavenging free superoxide and hydroxyl radicals on one hand and by inhibiting xanthine oxidase activity and lipid peroxidation (Abdel-Raheem et al., 2009).

Therapeutic administration of quercetin showed a better improvement in renal function. The histopathological renal sections of rats received quercetin orally after the end of gentamicin treatment course showed focal regeneration of some renal tubules leading to restoration of normal continuity and function of the tubular epithelium. This clearly explains why quercetin administration in this group was statistically more efficacious in normalizing the biochemical parameters and restoring the apparently normal histo-morphological structures of renal tubules and glomeruli compared with rats received quercetin orally before gentamicin treatment course followed by simultaneous administration of gentamicin plus quercetin. Stopping gentamicin administration implied stop of its accumulation in renal tubules and increased clearance rate (Dontabhaktuni et al., 2016). In fact, mild AKI normally recovers as a result of the renal tubule capacity to start regeneration a few days after AKI (Toyohara and Osafune, 2016). The serum creatinine level usually returns to its normal level within 14-21 days of the stop of gentamicin administration (Forni et al., 2017). Results of this study

showed that concomitant administration of gentamicin, calcium acetate (lower dose), and quercetin prevented gentamicin-induced nephrotoxicity. To the best of our knowledge, this is the first study in which the combination of calcium acetate and quercetin was applied for amelioration of gentamicin-induced tubular toxicity.

Last but not least, the ameliorative effect of both Ca acetate and quercetin against gentamicin-induced nephrotoxicity was demonstrated in this study, with the better protective effect of quercetin than Ca acetate. The natural antioxidants seem to possess the highest nephroprotective potential for use in the clinic (Casanova et al., 2017). The best candidates are generally molecules that possess the highest power antioxidant capacity, the highest permeability to the mitochondrion, the longest half-lives, and the best enhancement of enzyme activity (Oršolić et al., 2011). It would not be surprising to tell that quercetin exhibits all of these traits (Gomes et al., 2014). Additionally, quercetin enhances superoxide dismutase, catalase, glutathione peroxidase, glutathione reductase and glutathione activities promoting free radical scavenging activity, anti-inflammatory, and anti-apoptotic effects and thus contributes to renal protection against gentamicin-induced nephrotoxicity (Duranti et al., 2018).

## Conclusion

In conclusion, the present study proved the nephrotoxic effects of gentamicin. The use of both calcium acetate (lower and higher doses) or quercetin (therapeutically and prophylactically) in combination with gentamicin significantly minimized its nephrotoxicity as revealed from decreasing BUN, serum creatinine, CRP levels, oxidative stress reactions, and histopathological alterations with better protective effect of quercetin than Ca acetate. In addition, co-administration of both calcium acetate and quercetin with gentamicin could prevent gentamicin-induced nephrotoxicity.

## 5. REFERENCES

- Abdel-Raheem, I. T., Abdel-Ghany, A. A., and Mohamed, G. A. (2009): Protective effect of quercetin against gentamicin-induced nephrotoxicity in rats. *Biol. Pharm. Bull.*, 32(1): 61-67 .
- Abdelrahman, R. (2018): Protective effect of apocynin against gentamicin-induced nephrotoxicity in rats. *Hum. Exp. Toxicol.*, 37(1): 27-37 .
- Abdelrahman, R. (2018): Protective effect of apocynin against gentamicin-induced nephrotoxicity in rats. *Hum. Exp. Toxicol.*, 37(1): 27-37 .
- Balakumar, P., Rohilla, A., and Thangathirupathi, A. (2010): Gentamicin-induced nephrotoxicity: do we have a promising therapeutic approach to blunt it? *Pharmacol. Res.*, 62(3): 179-186 .
- Balakumar, P., WitnessKoe, W. E., Gan, Y. S., JemayPuah, S. M., Kuganesswari, S., Prajapati, S. K., Varatharajan, R., Jayachristy, S. A., Sundram, K., and Bahari, M. B. (2017): Effects of pre and post-treatments with dipyrindamole in gentamicin-induced acute nephrotoxicity in the rat. *Regul.Toxicol.Pharmacol.*, 84: 35-44.
- Bancroft, J., Stevens, A., and Turner, D. (1996): *Theory and practice of histological techniques 4th Ed Churchill Living Stone, New York Edinburgh. Madrid, Sanfrancisco.*
- Boroushaki, M. T., and Sadeghnia, H. R. (2015): Protective effect of safranal against gentamicin-induced nephrotoxicity in rat. *Iran. J. Med. Sci.*, 34(4): 285-288 .
- Casanova, A. G., Vicente-Vicente, L., Hernández-Sánchez, M. T., Pescador, M., Prieto, M., Martínez-Salgado, C., Morales, A. I., and López-Hernández, F. J. (2017): Key role of oxidative stress in animal models of aminoglycoside nephrotoxicity revealed by a systematic analysis of the antioxidant-to-nephroprotective correlation. *Toxicology*, 385: 10-17.
- Chaudhary, S., Ganjoo, P., Raiusddin, S., and Parvez, S. (2015): Nephroprotective activities of quercetin with potential relevance to oxidative stress induced by valproic acid. *Protoplasma*, 252(1): 209-217 .
- Derakhshanfar, A., Sadeghian, M. H., Abbasabadi, N., and Imanian, M. H. (2015): Histopathologic and biochemical study of the effect of saffron extract on gentamicin-induced nephrotoxicity in rats. *Comp. Clin. Pathol.*, 24(6): 1347-1351 .
- Dontabhaktuni, A., Taft, D. R., and Patel, M. (2016): Gentamicin Renal Excretion in Rats: Probing Strategies to Mitigate Drug-Induced Nephrotoxicity. *Pharmacology & Pharmacy*, 7(01): 43-55.
- Duranti, G., Ceci, R., Patrizio, F., Sgrò, P., Di Luigi, L., Sabatini, S., Felici, F., and Bazzucchi, I. (2018): Chronic consumption of quercetin reduces erythrocytes oxidative damage: Evaluation at resting and after eccentric exercise in humans. *Nutr. Res.*, 50: 73-81 .
- El-Ashker, M., Abdelhamid, F., Risha, E., Salama, M., and El-Sebaei, M. (2015): Vitamin C ameliorates gentamicin-induced acute kidney injury in equines: an experimental study. *J. Equine Vet. Sci.*, 35(3): 238-243.
- Eldin, A. A. K., Shaheen, A. A., Elgawad, H. M. A., and Shehata, N. I. (2008): Protective effect of taurine and quercetin against renal dysfunction associated with the combined use of gentamycin and diclofenac. *Indian J. Biochem.Biophys.*: 332-340 .
- Esterbauer, H., Schaur, R. J., and Zollner, H. (1991): Chemistry and biochemistry of 4-hydroxynonenal, malonaldehydeand related aldehydes. *Free Radic. Biol. Med.*, 11(1): 81-128 .
- Fawcett, J., and Scott, J. (1960): A rapid and precise method for the determination of urea. *J. Clin. Pathol.*, 13(2): 156-159.
- Forni, L., Darmon, M., Ostermann, M., Oudemans-van Straaten, H., Pettilä, V., Prowle, J., Schetz, M., and Joannidis, M. (2017): Renal recovery after acute kidney injury. *Intensive Care Med.*, 43(6): 855-866 .
- Fujiwara, K., Shin, M., Matsunaga, H., Saita, T., and Larsson, L.-I. (2009): Light-microscopic immunocytochemistry for gentamicin and its use for studying uptake of the drug in kidney. *Antimicrob. Agents Chemother.*, 53(8): 3302-3307 .
- Gomes, I. B., Porto, M. L., Santos, M. C. L., Campagnaro, B. P., Pereira, T. M., Meyrelles, S. S., and Vasquez, E. C. (2014): Renoprotective, anti-oxidative and anti-apoptotic effects of oral low-dose quercetin in the C57BL/6J model of diabetic nephropathy. *Lipids Health Dis.*, 13(1): 184-194.
- Gupta, A., Birmhan, K., Raheja, I., Sharma, S. K., and Kar, H. K. (2016): Quercetin: a wonder bioflavonoid with therapeutic potential in disease management. *Asian Pacific Journal of Tropical Disease*, 6(3): 248-252.
- He, J., Mao, E.-Q., Jing, F., Jiang, H.-T., Yang, W.-H., and Chen, E.-Z. (2016): Pre-Treatment Serum C-Reactive Protein Level Is An Independent Risk Factor for Development of Nephrotoxicity in Patients Receiving High-Dose Vancomycin. *Pharmacology*, 97(5-6): 294-300.
- Helgeson, N., Adamson, D., Pike, R., JAMES, D., NICODEMUS, D., LEE, B., and MILLER, G. (1973): *Reactive Protein. Lab. Med.*, 2(chapter 29.)
- Hur, E., Garip, A., Camyar, A., Ilgun, S., Ozisik, M., Tuna, S., Olukman, M., NarliOzdemir, Z., YildirimSozmen, E., and Sen, S. (2013): The effects of vitamin D on gentamicin-induced acute kidney injury in experimental rat model. *Int. J. Endocrinol.*, 2013: 313528.
- Jafarey, M., Ashtiyani, S. C., and Najafi, H. (2014): Calcium dobesilate for prevention of gentamicin-induced nephrotoxicity in rats. *Iran. J. Kidney Dis.*, 8(1): 46-52 .
- Leekha, S., Terrell, C. L., and Edson, R. S. (2011). General principles of antimicrobial therapy. Paper presented at the Mayo Clin. Proc.
- Lopez-Novoa, J. M., Quiros, Y., Vicente, L., Morales, A. I., and Lopez-Hernandez, F. J. (2011): New insights into the mechanism of aminoglycoside nephrotoxicity: an integrative point of view. *Kidney Int.*, 79(1): 33-45 .

- Misra, H. P., and Fridovich, I. (1972): The role of superoxide anion in the autoxidation of epinephrine and a simple assay for superoxide dismutase. *J. Biol. Chem.*, 247(10): 3170-3175.
- Oršolić, N., Gajski, G., Garaj-Vrhovac, V., Đikić, D., Prskalo, Z. Š., and Sirovina, D. (2011): DNA-protective effects of quercetin or naringenin in alloxan-induced diabetic mice. *Eur. J. Pharmacol.*, 656(1-3): 110-118 .
- Padmini, M. P., and Kumar, J. V. (2012): A histopathological study on gentamycin induced nephrotoxicity in experimental Albino rats. *IOSR J Dent Med Sci*, 1(1): 14-17 .
- Pannu, N., and Nadim, M. K. (2008): An overview of drug-induced acute kidney injury. *Crit. Care Med.*, 36(4): 216-223 .
- Patil, A. N., Arora, T., Desai, A., and Tripathi, C. D. (2014): Comparison of the species-sensitive effects of different dosages of calcium and verapamil on gentamicin-induced nephrotoxicity in rats and rabbits. *Toxicol. Int.*, 21(3): 225-231 .
- Poormosavi, S., Behmanesh, M., and Najafzadeh, H. (2010): Effect of cimetidine on gentamicin-losartan induced-nephrotoxicity in rats. *African Journal of Pharmacy and Pharmacology*, 4(6): 341-345.
- Quiros, Y., Vicente-Vicente, L., Morales, A. I., López-Novoa, J. M., and López-Hernández, F. J. (2010): An integrative overview on the mechanisms underlying the renal tubular cytotoxicity of gentamicin. *Toxicol. Sci.*, 119(2): 245-256 .
- Sardana, A., Kalra, S., Khanna, D., and Balakumar, P. (2015): Nephroprotective effect of catechin on gentamicin-induced experimental nephrotoxicity. *Clin. Exp. Nephrol.*, 19(2): 178-184.
- Shoman, A. A., Al-Awam, M., Ahmed, U. F., Metwally, E. S., and Samea, T. A. (2013): Taurine and Calcium Carbonate (CaCO<sub>3</sub>) in Gentamycin Induced Nephrotoxicity in Albino Rats. *Med. J. Cairo Univ.*, 88(1): 619-623 .
- Singh, A. P., Muthuraman, A., Jaggi, A. S., Singh, N., Grover, K., and Dhawan, R. (2012): Animal models of acute renal failure. *Pharmacol. Rep.*, 64(1): 31-44 .
- SPSS (Statistical Package for Social Sciences) Ver22. Statistical Program under Windows®, U.S.A.
- Stojiljkovic, N., Stojiljkovic, M., Mihailovic, D., Randjelovic, P., Ilic, S., Gocmanac-Ignjatovic, M., and Veljkovic, M. (2012): Beneficial effects of calcium oral coadministration in gentamicin-induced nephrotoxicity in rats. *Ren.Fail.*, 34(5): 622-627 .
- Tietze, F. (1969): Enzymic method for quantitative determination of nanogram amounts of total and oxidized glutathione: applications to mammalian blood and other tissues. *Anal. Biochem.*, 27(3): 502-522 .
- Toyohara, T., and Osafune, K. (2016): Novel regenerative therapy for acute kidney injury. *Renal Replacement Therapy*, 2(1): 34-42.
- Veysier, P., and Bryskier, A. (2005): Aminocyclitol aminoglycosides. *Antimicrobial Agents*: 453-469 .
- Young, D., Postaner, L., and Giberman, V. (1975): Colorimetric determination of serum creatinine. *Journal of Clinical Chemistry*, 21: 112.