

Efficacy of Ginger and Nutritox® in counteracting aflatoxin effects on white Pekin ducklings

Walaa A. Abu El-Ela^{1*}, Kamel I. Abou.Elazm², Sanaa S. A. Awad²



¹Veterinary Teaching Hospital, Faculty of Veterinary Medicine Mansoura University, Mansoura 35516, Egypt.

²Departments of Poultry and Rabbit Diseases, Faculty of Veterinary Medicine Mansoura University, Mansoura 35516, Egypt.

ARTICLE HISTORY

Received: 16.10.2019

Revised: 06.12.2019

Accepted: 09.12.2019

Address correspondence Walaa A. Abu El-Ela; Tel: +201224000367;

E-mail: walaaabuelela@hotmail.com

ABSTRACT

Objective: To evaluate the anti-aflatoxin effects of Ginger and Nutritox® in white Pekin ducklings.

Design: Randomized experimental study

Animals: Ninety- one-day-old white Pekin ducklings.

Procedures: Ducklings were alienated randomly into six equal groups, each group in 3 replicates (each replicate, n=5). Control group G1) was fed on commercial broiler basal diet without any medications, while other experimental groups, namely 2, 3, 4, 5 and 6 were received diet containing: G2) basal diet (BD) + 300 ppb AF (aflatoxin); G3) BD + 300 ppb AF + 250 mg kg⁻¹ Gr (Ginger); G4) BD +300 ppb AF +1gm/kg feed Nutritox®; G5) BD + 250 mg kg⁻¹ mg/kg of B.W Gr; G6) BD + 1gm/kg feed Nutritox® during study (1-14) days respectively.

Results: Results showed that, addition of Ginger and Nutritox® ameliorated in different degrees the adverse effects of aflatoxin and improved growth performance and some serum biochemical parameters [Aspartate aminotransferase (AST), alanine aminotransferase (ALT) and Alkaline phosphatase (ALP)]. They hasten the recovery of antioxidant enzymes (MDA and GSH) in tissue to their normal levels during certain periods of our experiments. Histopathological liver changes run in the same track with biochemical results. Results revealed that administration of Ginger or Nutritox® in diet prevents and/or reduce some adverse effects of aflatoxin in ducks.

Conclusion and clinical relevance: Our study indicates that ginger, an alternative natural product can provide protection against aflatoxin as Nutritox®.

Keywords: Aflatoxin, duckling, ginger, Nutritox®, antioxidants, histopathology.

1. INTRODUCTION

Aflatoxins are hepatotoxic metabolites of *Aspergillus flavus* and *Aspergillus parasiticus* as well as *Penicillium puberulum* [1]. In livestock and laboratory animal, the most biologically active form of AF is aflatoxin B1 (AFB1); it is responsible of increasing mortalities, decreasing performance, increasing liver lesions, and immunosuppression in poultry [2-4]. Although extensive data is obtainable on the effects of aflatoxin in livestock animals, yet there is less on ducklings; the most sensitive poultry species, who reveal 100% mortality at 1 ppm AF [5].

The adverse effects of mycotoxins in broiler chicks were ameliorated by many physical, chemical and biological methods [6]. Chemoprevention of toxins using antioxidant nutrients is being investigated because of their ability to reduce disease formation by induction or inhibition of key enzyme systems [7]. Numerous herbal products were believed to have therapeutic benefits with minimal side effects, easy viability and long lasting curative effects for hepatic fibrosis [8; 9]. The biological method, using microorganisms or their metabolites, was suggested as a favorable alternative to detoxify mycotoxins [10].

Ginger (*Zingiber officinale*), is herbaceous rhizomatous perennial consumed as a medicine, delicacy, or spice. Its family name is Zingiberaceae [11]. It used as a medicinal compound in various traditional systems of medicine to treat common illnesses such as gastrointestinal disturbances, rheumatic complaints, diarrhea, nausea and parasitic infestations [12]. Laboratory studies have shown that ginger possesses free radical-scavenging, antioxidative, anti-inflammatory, antimicrobial, antiviral, antidiabetic, antihypertensive, anticancer, chemo preventive and immunomodulatory effects [12; 13]. Ginger works in many different ways: as a scavenger of free radicals, inhibits or breaks the chain of lipid peroxidation, possesses anti-inflammatory effects, enhances antioxidant defense system and modulates detoxifying enzymes [14].

Probiotic is a live microbial feed supplement which increasingly used in poultry diets to improve feed utilization, enhance growth rate and control intestinal infections [15]. Many commercial products are used for detoxification containing mycotoxin-binders that holds promise for using in contaminated feeds [16]. *Lactobacillus* cultures [17], yeasts and lactic acid bacteria [18] act as biological adsorbents that

prevent absorption of aflatoxin from intestine of humans and animals. Nutritox[®], one of a commercial mycotoxin binder products existing in the Egyptian market and used in broiler diet contaminated with aflatoxin [19; 20].

Therefore, the aim of the current investigations was to evaluate the ameliorative effect of herb (ginger) against aflatoxicosis in white Pekin duckling and to focus on the hepatoprotective of ginger (as a herbal compound) in prevention and treatment of hepatic damage induced by aflatoxin compared with Nutritox[®] as a detoxifying commercial product mixture.

2. MATERIALS AND METHODS

2.1. Diet

Broiler diets (EL-Baraka Company) were analyzed in the Mycotoxins Central Lab and Food Safety of the National Research Center (NRC) to make sure that it was free from aflatoxins via high performance liquid chromatography (HPLC).

2.2. Artificially toxicated diet

Productions of aflatoxins were done by culturing of standard toxigenic strain of *Aspergillus parasiticus* NRRL2999, from fresh potato dextrose agar media (PDA) on rice according to the method of Shotwell et al. [21] in the laboratory of poultry diseases department, Faculty of Vet Med, Mansoura University. Moldy rice was autoclaved, dried, grounded to fine powder and analyzed for aflatoxins content by HPLC in mycotoxins central lab and food safety of the National Research Center (NRC). Ground rice was added to duckling basal diet to produce 300 ppb aflatoxin.

2.3. Feed additives

1. *Zingiber officinale* (Ginger): Obtained as a ginger extract in form of hard capsules. Each one contains fine powder of 550 mg from Puritans's Pride, Inc. (Oakdale, NY, USA).

2. Nutritox[®] (PROFARM[®]): Obtained from local market

2.4. Experimental design

Ninety, one-day-old white Pekin ducklings were equally divided randomly into 6 groups, each contains 15 birds. All birds were weighed individually at the beginning of the experiment and on a weekly basis during the experimental period (14 days). According to dietary treatments; ducklings were allocated into the following groups: Group (1), control diet without any additives; Group (2), Basal diet + 300 ppb Aflatoxin (BAF) [22]; Group (3), Basal diet + 300 ppb AF + 250 mg/kg of BW Gr (Ginger) (BAFGr) [23]; Group (4), Basal diet + 300 ppb AF + 1gm/kg feed Nutritox[®] (BAFNut) [15]; Group (5), Basal diet + 250 mg/kg of B.W Gr (Ginger) (BGr) and; Group (6), Basal diet + 1gm/kg feed Nutritox[®] (BNut).

2.5. Body weight and feed intake

All experimental ducklings were daily observed for clinical signs, on day 7 and 14 all life birds were weighed individually and total feed intake were recorded for each pen. Feed conversion rate (FCR) was calculated according to the following formulae:

$$\text{FCR (g/g)} = \text{FI (g)} / \text{WG (g)}. \text{ Where FI is the Dry feed intake (g)}$$

2.6. Serum samples

Blood samples were collected into a dry and clean centrifuge tubes without anticoagulant at day 7 and day 14. Clotted blood was centrifuged at 3000 rpm for 15 min and serum were separated and preserved at -20° C until submitted for biochemically analysis.

2.7. Liver samples

On 14 day 6 birds from each group were slaughtered, sacrificed and dead birds were subjected for postmortem examination. Liver was dissected out and divided into two parts; one part processed for histopathological examinations and the other used for liver homogenate.

2.8. Preparation of liver homogenate

Liver tissue was perfused with PBS (phosphate buffered saline) solution (pH 7.4) containing 0.16 mg / ml heparin to remove any red blood cells or clots. Tissue was homogenized in 10 ml cold buffer (i, e, 50 mM potassium phosphate, pH 7.5) per gram tissue, centrifuge (Hettich) at 4000 r-p-m for 15 minutes, then supernatant was removed and stored on ice for further analysis.

2.9. Biochemical parameters

Serum alanine aminotransferase (ALT) and aspartate aminotransferase (AST) enzymes were determined using readymade kits of Biodiagnostic CAT. NO. AT 10 34 (45). Alkaline phosphatase (ALP) was determined using readymade kits of Biodiagnostic CAT. NO. AP 10 20. Malondialdehyde (MDA) was determined by using readymade kits of Biodiagnostic CAT. NO (GR 25 11). Reduced glutathione (GSH) was determined by using readymade kits of Biodiagnostic Cat. No (MD 25 29). All biochemical parameters were measured spectrophotometrically. All used kits were purchased from Biodiagnostic Co, Tahreer St., Dokki, Giza, Egypt.

2.11. Histopathological examination

Liver specimens were placed in plastic cassette and immersed in 10% neutral buffered formalin. Five µm thick paraffin sections were prepared and stained with hematoxylin and eosin for histopathological examination [24].

2.12. Statistical analysis

All data were analyzed and expressed as means ± standard deviations of the means. Obtained data were analyzed by two ways analysis of variance (one ways ANOVA) using the SPSS software statistical package (SPSS version 16.0 for Window). Differences were considered statistically significant when P < 0.05.

3. RESULTS

3.1. Ducks performance

In the present study, the cumulative mortality was up to 13.3% and 20% at day 7 and 14, respectively ducklings fed

on 300 ppb level of aflatoxin – contaminated diet (BAF). Only one bird died in ginger treated group in association with reduction of the severity of clinical signs, but no mortality was recorded in other groups.

As shown in tables 1 and 2, aflatoxin caused a severe reduction in body weight, weight gain, feed intake and growth performance. Weight gain of duckling fed Nutritox[®] treated ration was significantly improved all over the experimental time points. Although the weight gain of duckling fed ginger (BAFGr) was significantly affected by aflatoxin in the 7th day of life but not in the 14th day. In table 2, FCR was significantly increased by aflatoxin (BAF) and significantly improved by ginger and Nutritox[®] addition.

3.2. Biochemical parameters

As shown in table 4, aflatoxin spiked diet caused a significant increase in ALT, AST and ALP in the 7th and 14th day. Dietary supplementation of ginger to the aflatoxin contaminated diet (BAFGr) caused significant improvement in ALT levels in the 7th and 14th days. Serum activity of enzymes (ALT, AST and ALP) in ducks of (BAFNut) group revealed significant improvement in comparison to the normal picture at 7th and 14th days of experiment; except AST at 7th day.

In table 5, feeding on aflatoxin spiked diet displayed significant increased and decrease MDA in and GSH level; respectively, when compared to control group. GSH level was improved ($P < 0.05$) and the elevated level of MDA was decreased significantly in BAFGr and BAFNut groups. Co-administration of AF with ginger (BAFGr). No significant change was found in (BNut) group fed only nutritox[®].

3.3. Histopathology

In the study, a significant increase in relative liver weight of sacrificed ducklings was noticed in BAF group, as

shown in table 3. At day 14, the liver showed characteristic macrosteatosis, periportal intense inflammatory response, proliferation and fibrosis of the bile ductules, sometimes with apoptotic changes in their walls. Some of the hepatocytes and their nuclei were enlarged (megalocytosis). Marked peri-portal edema associated with compression atrophy of some bile ducts, icteric changes, multifocal peri-portal and midzonal coagulative necrosis together with adenomatous biliary proliferation were recorded (Fig.1).

BAFGr group revealed moderate portal biliary proliferation; portal and interstitial lympho-plasmacytic aggregations together with peri-portal coagulative necrosis were seen 14 days post-treatment (Fig.1).

Aflatoxin intoxicated ducklings treated with Nutritox[®] showed Mild biliary proliferation, congestion of portal blood vessels, round cells infiltration (lymphoplasmacytic) and a small focal peri-portal areas of coagulative necrosis, infiltrated by lymphocytes and macrophages were seen, 14 days post-treatment (Fig.1).

Histological examination of liver sections from ducklings treated by Ginger (BGr) or Nutritox[®] (BNut) for 7 or 14 days revealed, liver parenchyma covered by a thin connective tissue capsule. The hepatic parenchyma was arranged in hepatic lobules, composed of polygonal hepatocytes organized as irregular, radial interconnecting cords or groups of cells around a central vein and separated by blood sinusoids. In the boundary of each lobule a portal area was seen, consists of a branch of hepatic artery; one or more branches of hepatic vein and one to four branches of the bile ducts lined by cuboidal cells, such bile ducts, sometime contain a bile secretion.(Fig.1).

Table 1. Comparative effect of ginger and nutritox[®] on body weights of ducklings undergoing experimental aflatoxicosis.

Parameter	Dietary Treatments						P value
	BD	BAF	BAFGr	BAFNut	BGr	BNut	
day 1	56.7±4.5 ^a	54.3±2.6 ^a	53.3±3.1 ^a	54.7±3.9 ^a	56.0±3.8 ^a	55.7±4.2 ^a	0.470
day 7	146.7±18.8 ^a	128.1±21.1 ^b	135.4±17.6 ^{ab}	140.7±27.2 ^{ab}	144.0±15.9 ^{ab}	143.3±11.3 ^{ab}	0.124
day 14	334.3±19.1 ^a	296.8±18.1 ^b	317.3±17.0 ^a	318.2±27.2 ^a	329.6±17.2 ^a	334.3±16.8 ^a	0.001

B.wt: Body weight; BD: Basal diet; BAF: Basal diet+aflatoxin; BAFGr: Basal diet+aflatoxin+ginger; BAFNut: Basal diet+aflatoxin+Nutritox; BGr: Basal diet+ginger; BNut: Basal diet+Nutritox.

^{a, b} values in a column with different subscript differ significantly ($P \leq (0.05)$).

NB.: Numbers were approximated to one decimal point.

Table 2. Comparative effect of ginger and nutritox[®] on mortalities, feed intake, weight gain and FCR in duckling undergoing with experimental aflatoxicosis.

Parameter	Dietary Treatments						P value
	BD	BAF	BAFGr	BAFNut	BGr	BNut	
Mortalities							
day 7	0	2 (13.3%)	1 (6.7%)	0	0	0	
day 14	0	1 (20%)	0 (6.7%)	0	0	0	
F.I (g)							
day 7	120.7±1.4 ^b	110.62±2.2 ^a	120.0±2.5 ^b	120.7±1.5 ^b	120.7±1.4 ^b	120.7±0.9 ^b	0.00
day 14	468.6±10.6 ^b	409.0±7.4 ^d	455.4±16.1 ^{abc}	442.9±6.5 ^c	474.6±23.1 ^a	452.5±10.7 ^{abc}	0.001
Wt.gain (g)							
day 7	90.0±2.8 ^a	65.8±1.4 ^d	78.0±2.3 ^c	86.0±4.1 ^b	88.0±2.7 ^b	86.7±1.1 ^b	0.00
day 14	187.6±2.6 ^b	145.5±1.33 ^f	181.9±3.14 ^d	177.5±2.25 ^e	185.6±2.11 ^c	190.9±1.45 ^a	0.00
FCR							
day 7	1.3±.01 ^d	1.7±.1 ^a	1.5±.0 ^b	1.5±.0 ^c	1.4±.0 ^{cd}	1.4±.0 ^{cd}	0.00
day 14	2.5±.013 ^b	2.8±.09 ^a	2.5±.01 ^b	2.6±.12 ^b	2.5±.07 ^b	2.5±.38 ^b	0.097

F.I: Feed intake; Wt.gain: weight gain; FCR: Feed conversion rate; BD: Basal diet; BAF: Basal diet+aflatoxin; BAFGr: Basal diet+aflatoxin+ginger; BAFNut: Basal diet+aflatoxin+Nutritox; BGr: Basal diet+ginger; BNut: Basal diet+Nutritox.

^{a, b, c, d} values in a column with different subscript differ significantly ($P \leq (0.05)$).

NB.: Numbers were approximated to one decimal point.

Table 3. Comparative effect of ginger and nutritox[®] on body weight and relative liver weight of sacrificed ducklings undergoing experimental aflatoxicosis at day 14 of age.

Parameters	Dietary Treatments						P value
	BD	BAF	BAFGr	BAFNut	BGr	BNut	
B. wt (g)	336.7±23.6 ^b	295.0±23.8 ^a	315.0±25.0 ^b	321.7±25.2 ^b	331.7±5.8 ^b	338.3±12.6 ^b	0.101
R.L wt (g)	3.9±0.3 ^b	5.2±0.3 ^a	3.6±0.3 ^b	3.9±0.2 ^b	3.8±0.2 ^b	3.8±0.2 ^b	0.003

B.wt: Body weight; R.L wt: Relative liver weight; BD: Basal diet; BAF: Basal diet+aflatoxin; BAFGr: Basal diet+aflatoxin+ginger; BAFNut: Basal diet+aflatoxin+Nutritox; BGr: Basal diet+ginger; BNut: Basal diet+Nutritox.

^{a, b} values in a column with different subscript differ significantly ($P \leq (0.05)$).

N.B: Numbers were approximated to one decimal point.

Table 4. Comparative effect of ginger and nutritox[®] on different biochemical parameters (ALT, AST, ALP, GSH and MDA) in ducklings undergoing experimental aflatoxicosis.

Parameters	Dietary Treatments						P value
	BD	BAF	BAFGr	BAFNut	BGr	BNut	
ALT(U/L)							
day 7	81.2±5.4 ^b	110.2±15.6 ^a	89.1±20.7 ^b	88.6±11.2 ^b	85.9±10.8 ^b	80.2±13.3 ^b	0.374
day 14	121.6±6.5 ^b	157.3±9.2 ^a	118.3±1.9 ^b	120.8±7.3 ^b	129.1±7.0 ^b	120.8±7.3 ^b	0.000
AST(U/L)							
day 7	54.9±3.1 ^{bc}	71.7±8.2 ^a	69.9±13.6 ^{ab}	57.4±6.1 ^{abc}	62.9±11.2 ^{abc}	56.1±4.4 ^{bc}	0.024
day 14	55.3±4.5 ^b	75.9±3.5 ^a	62.5±6.5 ^{ab}	59.2±17.5 ^b	59.5±9.0 ^b	57.2±2.9 ^b	0.111
ALP(U/L)							
day 7	54.5±3.9 ^b	63.6±6.4 ^a	50.9±5.1 ^b	51.9±1.2 ^b	57.3±8.7 ^{ab}	49.4±4.8 ^b	0.023
day 14	48.4±5.8 ^b	59.8±1.2 ^a	52.7±6.6 ^{ab}	51.5±7.0 ^{ab}	50.8±1.6 ^{ab}	49.8±1.6 ^b	0.019
GSH(mg/g.tissue)							
day 14	.26±.02 ^a	.17±.05 ^b	.26±.06 ^a	.26±.03 ^a	.26±.02 ^a	.26±.02 ^a	0.135
MDA(mg/g.tissue)							
day 14	.25±.01 ^b	.47±.01 ^a	.26±.03 ^b	.25±.03 ^b	.25±.02 ^b	.21±.09 ^b	0.041

ALT: alanine aminotransferase; AST: aspartate aminotransferase; ALP: alkaline phosphatase; GSH: reduced glutathione; MDA: Malondialdehyde; BD: Basal diet; BAF: Basal diet+aflatoxin; BAFGr: Basal diet+aflatoxin+ginger; BAFNut: Basal diet+aflatoxin+Nutritox; BGr: Basal diet+ginger; BNut: Basal diet+Nutritox.

a, b, c values in a column with different subscript differ significantly ($P < (0.05)$).

NB.: Numbers were approximated to two decimal points.

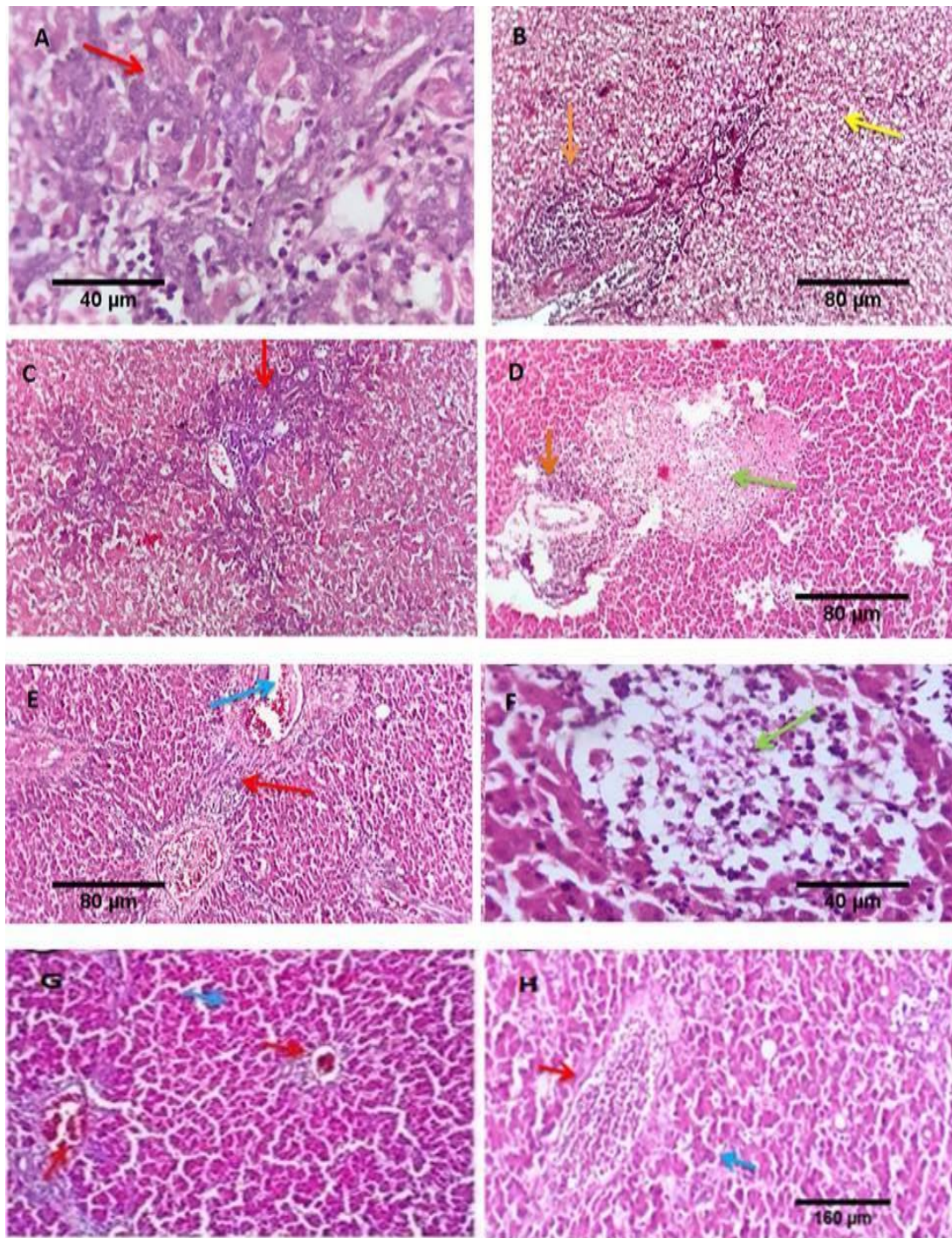


Figure 1: Photomicrograph of liver of 14days ducklings. **(A)** liver of (Basal diet+aflatoxin), showing characteristic adenomatous biliary proliferation was recorded (red arrow) Scale bars 40 um. . **(B)** Liver of (Basal diet+aflatoxin) macrosteatosis (yellow arrow), periportal intense inflammatory response (orange arrow) scale bars 80 um. **(C)** Liver of (Basal diet+aflatoxin+ginger) showing Moderate portal biliary proliferation (red arrow). **(D)** Liver of (Basal diet+aflatoxin+ginger) portal and interstitial lympho-plasmacytic aggregations (orange arrow) together with peri-portal coagulative necrosis (Green arrow) scale bar, 80 um. **(E)** Liver of (Basal diet+aflatoxin+nutritox) showing Mild biliary proliferation (red arrow), congestion of portal blood vessels (blue arrow) scale bar, 80 um. **(F)** Liver of (Basal diet+aflatoxin+nutritox) showing small focal peri-portal areas of coagulative necrosis, infiltrated by lymphocytes and macrophages (green arrow) scale bars, 40 um. **(G)** Liver of (Basal diet+ginger) and **(H)** liver of (Basal diet+nutritox) showing hepatic parenchyma arranged in hepatic lobules, composed of polygonal hepatocytes organized as irregular, radial interconnecting cords or groups of cells around a central vein and separated by blood sinusoids. In the boundary of each lobule a portal area is seen, scale bar, 160 um.

4. DISCUSSION

Although extensive information is available on the effects of aflatoxins in other livestock animals, yet there is less information regarding ducklings; the most sensitive poultry species [1; 5; 25]. One-day-old white Pekin ducklings were used in this experiment to evaluate the protective efficacy of ginger and Nutritox[®] against aflatoxicosis.

In the present research work, the cumulative mortality was 13.3% and 20% at 7th and 14th day, respectively, in ducklings fed on 300 ppb level of aflatoxin – contaminated diet (BAF). LD₅₀ were assumed to be 1 ppm in white Pekin duckling [1]. Similar finding has been recorded in a previous report of Abbasi et al. [26] who recorded that mortality was significantly increased at level of 200 µg/kg AFB1 in diets from day 1 to 14. On contrary Chen et al. [27] reported that dietary AFB1 (0.21 mg/kg) did not affect duck mortality which averaged 3.5% across all treatments at 14 d of age. Interestingly, ginger administration in (BAFGr) reduced mortality rate. This result is in accordance with that of Doaa and Ghada. [28]. Ginger reduced the severity of clinical signs through improving protein digesting enzymes and decreasing pathogenic bacteria [29].

AFB1 in diet caused significant reduction in the growth of 3 weeks old mule duckling [30] and 14 day Pekin duckling [27; 31] with no beneficial effects in average daily gain. Adverse effects of aflatoxin were species and dose-dependent, and might be due to the deleterious effects of aflatoxin B1 on protein, carbohydrate, lipid metabolism and pancreatic enzymes activity [10]. In accordance with that of previous reports [28; 32], weight gain of duckling fed Nutritox[®] supplemented diet was significantly improved all over the experimental time points. Ginger increased the body weight and this may be due to its content of volatile oils as gingrol, zingibaine and zingiberol which accelerate digestion, improve protein digesting enzymes, stimulates lactic acid bacteria and decreases pathogenic bacteria [29; 33]. Our findings revealed that dietary supplementation of ginger significantly increased the feed intake. This improvement indicated that pungent taste and strong aromatic odor of ginger did not affect the feed intake [29; 34].

Interestingly, FCR was significantly increased by aflatoxin (BAF) [31] and significantly improved by ginger and Nutritox[®] addition. Dietary supplementations of ginger increased fiber content in diet leading to decrease the feed energy concentration with better growth performance in chickens [35].

Liver function tests as evaluated by alanine aminotransferases (ALT), serum aspartate aminotransferases (AST) and alkaline phosphatase (ALP), indicated a liver damage as described by Kubena et al. and Ortatali et al. [36; 37]. Aflatoxin in diet caused a significant increase in ALT, AST and ALP. Changing in those enzymes during aflatoxicosis has been recorded previously by Mahmoud and Khorshom; Walaa et al. and Ostrowski-

Meissner [1; 31]. Aflatoxin was reported to elevate serum levels of AST, ALT and ALP due to muscular trauma, liver damage [30; 36], hepatocellular damage in ducks, biliary cholestasis and hyperplasia of bile duct [27; 38]. Significant improvement in ALT levels was recorded in (BAFGr) group. These results were in harmony with Doaa and Ghada. [28]; where broiler chicks fed on ginger revealed positive effects on liver enzymes through a reduction in AST, ALT and ALP levels. Insignificant improvement in AST levels occurs in the 14th day of aflatoxin administration. ALT is a specific cytoplasmic liver enzyme increased in hepatic diseases and fatty changes, while increase serum levels of AST alone is not indicative to specific organs [39]. Vipin et al. [40] found that ALP was not affected by ginger addition. Serum biochemical enzymes (ALT, AST and ALP) of ducks fed on aflatoxin plus Nutritox[®] (BAFNut) revealed significant improvement when compared with aflatoxicated ducks (BAF). These results agree with those of Abdalla et al. and Walaa et al. [19; 31]. This may be attributed to the beneficial effect of L. form of bacteria that reduce aflatoxin and improve health status [41].

GSH and MDA levels were analyzed to determine antioxidant status and the oxidative damage. MDA is a reactive aldehyde that appears during the peroxidation and degradation of polyunsaturated fatty acid in cell membrane, so it considered as an intermediate product of lipid peroxidation [42]. Aflatoxin spiked diet increased MDA level significantly and decreased GSH level significantly. Our results are consistent with Ayoub et al., 2010; Yang et al. and Vipin et al. [40; 43; 44]. Increase hepatic level of MDA could be attributed to AFB1 metabolites by cytochrome P450 enzyme to form AFB1-8,9-epoxide, which in turn reacts with macromolecules such as DNA and lipid, which leads to lipid peroxidation and cellular injury. Depletion of liver GSH may be related to its conjugation with the electrophilic metabolites [40; 45].

Ginger is a good scavenger of peroxide radicals, and contains polyphenols that increase the antioxidant enzyme gene expression and derive the intracellular response against oxidative stress [46] that leads to increase GSH level, enhanced the detoxification by neutralization of reactive oxygen sources (ROS) and it protect the liver from injury [40].

Supplementation of nutritox[®] with AF (BAFNut) significantly improved the decreased level of GSH and elevated level of MDA. These results are in accordance with those of [10; 47]. Serum and hepatic MDA level was relatively decreased, and the activity of GSH-Px increased markedly in liver when ducks fed on aflatoxin-contaminated diets containing *Bacillus subtilis* (*B. subtilis*) [47]. Additionally, dietary supplementation of yeast probiotic in broiler chicken enhance serum antioxidant enzyme activities [10].

The liver is the major target organ for aflatoxicosis [4]. Ahmed et al. and Ellakany et al. [48; 49] recorded moderate

to severe fatty changes, loss of architecture, mild to severe aggregation of lymphoid cell and heterophils in periportal and parenchymatous areas in addition to multifocal necrotic foci in liver of broiler chicken. The observed dystrophic and necrotic changes in liver, in our results, can be attributed to the altered primary macromolecules (lipids, proteins and DNA) provoked by the oxidative stress-induced DNA damage and lipid peroxidation. Aflatoxins undergo bioactivation to reactive 8,9-epoxide, which then binds to DNA and proteins [44; 50; 51]. Moreover, Aflatoxin B1 is cytotoxic for hepatocytes and inhibits their proliferation. The hyperplasia of bile duct epithelium occurs consequently to the direct toxic effect of AFB1 on bile duct epithelium or excessive production of prostaglandins due to AFB1- induced lipid peroxidation [52]. Marked micro-hepatosteatosis, moderate portal biliary proliferation, portal and interstitial lymphoplasmacytic aggregations together with peri-portal coagulative necrosis in BAFGr group. Our results are parallel with Doaa and Ghada. [28], who stated that co-administration of ginger with aflatoxin, liver at 21 day showed foci of lymphohistiocytic exudate replaced hepatic exudates in broilers and also in rats [40]. Ginger improved the histoarchitecture of liver with well-formed polygonal hepatocyte arrangement and nearly normal sinusoids [53]. Ginger extract could be able to enhance hepatocytes regeneration, protect against membrane fragility, and decrease leakage of the enzymes into circulation [54].

In this study, Nutritox[®] treated aflatoxicated ducklings (BAFNut) showed mild biliary proliferation, congestion of portal blood vessels, peri-portal edema, acute cholangitis and vacuolation of moderate number of hepatocytes. Nutritox[®] ameliorates the adverse effect of AF and this attributed to its excellent content of essential micronutrients, organic acids and their salts and *Lactobacillus acidophilus* extract [19], which have adsorbing capacity and play an important role in preventing mycotoxins absorption through the gastrointestinal tract, so help in getting rid of these toxins outside the bird body [20].

Conclusion

Administrations of Ginger and Nutritox[®] in diet could ameliorate the adverse effects of aflatoxin in ducks diet. Although we can consider ginger as a natural alternative anti-aflatoxin, yet Nutritox[®] is still giving much higher protection against aflatoxicosis than ginger.

Conflict of interest statement

The authors declare that there is no any conflict of interest in the current research work

Research ethics committee permission

The current research work is permitted to be executed according to standards of Animal Research Ethics committee, Faculty of Veterinary Medicine, Mansoura University.

Authors' contribution

W. A. A. performed the experiment, drafted the MS and performed the statistical analysis. A. K. I and S. A. A. conceived the study, supervised the whole research work, reviewed, edited and revised the MS.

5. REFERENCE

- [1] Mahmoud KI and Korshom M. Recovery of experimentally aflatoxicated white pekin duckling. In: Food borne contamination and Egyptian's Health 1996.
- [2] Ledoux D, Rottinghaus G, Bermudez A and Alonso-Debolt M. Efficacy of a hydrated sodium calcium aluminosilicate to ameliorate the toxic effects of aflatoxin in broiler chicks. *Poult Sci* 1999; 78, 204-210.
- [3] Agag B. Mycotoxins in foods and feeds: 1-Aflatoxins. *Ass. Univ. Bull. Environ. Res* 2004; 7, 173-205.
- [4] Abdelhamid A. Thirty two years (1978-2010) of mycotoxins research at Faculty of Agriculture, Almansoura University, Egypt. In: *Mycotoxin Res* 2010.
- [5] Muller R, Carlson C, Semeniuk G and Harshfield G. The response of chicks, ducklings, gosling, pheasants and poult to graded levels of aflatoxins. *Poult Sci* 1970; 49, 1346-1350.
- [6] Jalili M. A review on aflatoxins reduction in food. *Iran J Health Saf Environ* 2016; 3, 445-459.
- [7] Guarisco JA, Hall JO and Coulombe Jr RA. Mechanisms of butylated hydroxytoluene chemoprevention of aflatoxicosis—inhibition of aflatoxin B1 metabolism. *Toxicol Appl Pharmacol* 2008; 227, 339-346.
- [8] Seeff LB, Lindsay KL, Bacon BR, Kresina TF and Hoofnagle JH. Complementary and alternative medicine in chronic liver disease. *J Hepato* 2001; 34, 595-603.
- [9] Del Prete A, Scalera A, Iadevaia MD, Miranda A, Zulli C, Gaeta L, Tuccillo C, Federico A and Loguercio C. Herbal products: benefits, limits, and applications in chronic liver disease. *Evid Based Complement Alternat Med* 2012; 837939.
- [10] Salem R, El-Habashi N, Fadl SE, Sakr OA and Elbially ZI. Effect of probiotic supplement on aflatoxicosis and gene expression in the liver of broiler chicken. *Environ Toxicol Pharmacol* 2018; 60, 118-127.
- [11] Ghosh S, Bhateja P, Saini A and Rani J. In vitro evaluation of antioxidant activity of Ginger (*Zingiber officinale*). *Valley Int J* 2014; 1, 89-96.
- [12] Watson RR and Preedy VR. Bioactive food as dietary interventions for liver and gastrointestinal disease: bioactive foods in chronic disease states, Academic Press 2012.
- [13] Eman SI, Magdy SA and Mohamed HK. Pharmacological studies on some medicinal plants. *Fac. Of Vet. Med. Mans. University* 2014.
- [14] Haniadka R, Saxena A, Shivashankara A, Fayad R, Palatty P, Nazreth N, Francis A, Arora R and Baliga M. Ginger protects the liver against the toxic effects of xenobiotic compounds: preclinical observations. *J Nutr Food Sci* 2013; 3, 1000226.
- [15] Amer M, El-Bayomi, K and Zeinab M. Field studies on effect of probiotic on reproductivity of 51 weeks old broiler breeder chickens fed on mycotoxins contaminated ration. *Am. J. Sci* 2011; 7, 840-844.
- [16] Piva A and Galvano F. Nutritional approaches to reduce the impact of mycotoxins. *Biotechnology in the Feed Industry* 1999; 381-399.
- [17] El-Nezami H, Mykkänen H, Kankaanpää P, Salminen S and Ahokas J. Ability of *Lactobacillus* and *Propionibacterium* strains to remove aflatoxin B1 from the chicken duodenum. *J Food Prot* 2000; 63, 549-552.
- [18] Wu Q, Jezkova A, Yuan Z, Pavlikova L, Dohnal V and Kuca K. Biological degradation of aflatoxins. *Drug Metab Rev* 2009; 41, 1-7.
- [19] Abdalla O, Ahmed T and Almesalamy MM. pathological and biochemical changes induced by aflatoxin in chickens and a trial for treatment using *Lactobacillus acidophilus*. *Assiut. Vet. Med. J* 2012; 58.
- [20] Amin A. Comparative studies on antitoxic effect of Nutritox[®] and hydrated sodium calcium aluminosilicate on chicken aflatoxicosis. *Egypt. J. Comp. Path & Clinic Path.* 2013; 26.
- [21] Shotwell OL, Hesselstine C, Stubblefield R and Sorenson W. Production of aflatoxin on rice. *Appl. Environ. Microbiol* 1966; 14, 425-428.
- [22] Newberne PM and Butler WH. Acute and chronic effects of aflatoxin on the liver of domestic and laboratory animals: a review. *Cancer Res* 1969; 29, 236-250.
- [23] Abdulaziz Bardi D, Halabi MF, Abdullah N.A, Rouhollahi E, Hajrezaie M and Abdulla MA. In vivo evaluation of ethanolic extract of *Zingiber*

- officinale rhizomes for its protective effect against liver cirrhosis. *Biomed Res Int* 2013; 918460.
- [24] Suvarna KS, Layton C and Bancroft JD. *Bancroft's Theory and Practice of Histological Techniques E-Book*, Elsevier Health Sci 2018.
- [25] Bibu K. Aflatoxicosis in a white pekin duck. *Vet World* 2011; 4.
- [26] Abbasi F, Liu J, Zhang H, Shen X and Luo X. Effects of feeding corn naturally contaminated with aflatoxin on growth performance, apparent ileal digestibility, serum hormones levels and gene expression of Na⁺, K⁺-ATPase in ducklings. *Asian-Australas J Anim Sci* 2018; 31, 91.
- [27] Chen X, Horn N, Cotter P and Applegate T. Growth, serum biochemistry, complement activity, and liver gene expression responses of Pekin ducklings to graded levels of cultured aflatoxin B1. *Poult Sci* 2014; 93, 2028-2036.
- [28] Doaa A. and Ghada A. Evaluation of antimycotoxin effects of *Curcuma longa* and *Zingiber officinale* on broilers toxicated with aflatoxin. *Egypt J Chem Environ Health* 2015; 1, 503-523.
- [29] Karangiya V, Savsani H, Patil SS, Garg D, Murthy K, Ribadiya N and Vekariya S. Effect of dietary supplementation of garlic, ginger and their combination on feed intake, growth performance and economics in commercial broilers. *Vet World* 2016; 9, 245.
- [30] Cheng YH, Shen TF, Pang VF and Chen BJ. Effects of aflatoxin and carotenoids on growth performance and immune response in mule ducklings. *Comparative Biochemistry and Physiology Part C :Toxicol & Pharmacol* 2001; 128, 19-26.
- [31] Walaa AA, Mahmoud KI and Awad SA. Studies on the efficiency of aflatoxin control methods in poultry farms. *Zag. Vet. J* 2013; 1, 25-34.
- [32] Hashem MA and Mohamed MH. Haemato-biochemical and pathological studies on aflatoxicosis and treatment of broiler chicks in Egypt. *Vet Ital* 2009; 45, 323-337.
- [33] Iqbal Z, Nadeem QK, Khan M, Akhtar M and Waraich FN. In vitro anthelmintic activity of *Allium sativum*, *Zingiber officinale*, *Curcubita mexicana* and *Ficus religiosa*. *Int J Agric Biol* 2001; 3, 454-457.
- [34] Herve T, Raphaël KJ, Ferdinand N, Victor Herman N, Marvel W, Moyo N, Cyril D'Alex T, Vitrice L and Tiwa F. Effects of ginger (*Zingiber officinale*, roscoe) essential oil on growth and laying performances, serum metabolites, and egg yolk antioxidant and cholesterol status in laying japanese quail. *J Vet Med*, Vol 2019;7857504, 8.
- [35] Ghazi S, Malekizadeh M and Moeini M. The effects of different levels of ginger and turmeric rhizomes powder on productive performance characteristics of laying hens. *Euphrates J Agr Sci* 2011; 3, 1-5.
- [36] Kubena L, Harvey R, Phillips T and Clement B. Effect of hydrated sodium calcium aluminosilicates on aflatoxicosis in broiler chicks. *Poult Sci* 1993; 72, 651-657.
- [37] Ortatatli M and Oğuz H. Ameliorative effects of dietary clinoptilolite on pathological changes in broiler chickens during aflatoxicosis. *Vet Sci Res* 2001; 71, 59-66.
- [38] Méndez-Albores A, Del Río-García J and Moreno-Martinez E. Decontamination of aflatoxin duckling feed with aqueous citric acid treatment. *Anim Feed Sci Tech* 2007; 135, 249.262-
- [39] Ambrojo KS, Poggi JCG and Juzado AM. Use of laboratory testing to diagnose liver and biliary dysfunction in the horse. *J Gastroenterol Hepatol* 2013; 2, 807-813.
- [40] Vipin A, Rao R, Kurrey NK, KA AA and Venkateswaran G. Protective effects of phenolics rich extract of ginger against Aflatoxin B1-induced oxidative stress and hepatotoxicity. *Biomed Pharmacother* 2017; 91, 415-424.
- [41] Nasr El-Deen A. Clinicopathological studied on mycotoxicosis in chickens. , *Fac. Vet. Med. Zagazig University, Egypt* 2002.
- [42] Zhu Q, Qian Y, Zheng ZP, Lo C, Chen F and Wang M. Natural polyphenols alleviated lipid peroxidation-induced modification on BSA. *J Funct Foods* 2013; 5, 355-361.
- [43] Ayoub, M, El-Far A, Taha N, Korshom M, Mandour A, Abdel-Hamid H and El-Neweshy M. The biochemical protective role of some herbs against aflatoxicosis in ducklings: I. Turmeric. *Lucrări. Științifice. Seria Medicină Veterinară* 2011; 55, 150-159.
- [44] Yang J, Bai F, Zhang K, Bai S, Peng X, Ding X, Li Y, Zhang J and Zhao L. Effects of feeding corn naturally contaminated with aflatoxin B1 and B2 on hepatic functions of broilers. *Poult Sci* 2012; 91, 2792-2801.
- [45] Kheir Eldin AA, Motawi TM and Sadik NA. Effect of some natural antioxidants on aflatoxin B1-induced hepatic toxicity *Excli J* 2008; 7: 119-131.
- [46] El Shemy M, Abdalla A and Fararh K. Antioxidant and hepatoprotective effect of ginger in rats. *BVMJ* 2011; Vol.22, No 2: 7-14.
- [47] Zhang L, Ma Q, Ma S, Zhang J, Jia R, Ji C and Zhao L. Ameliorating effects of *Bacillus subtilis* ANSB060 on growth performance, antioxidant functions, and aflatoxin residues in ducks fed diets contaminated with aflatoxins. *Toxins* 2017; 9, 1.
- [48] Ahmed M, Ravikanth K, Rekhe D and Maini S. Histopathological alterations in Aflatoxicity and its amelioration with herbomineral toxin binder in broilers. *Vet World* 2009; 2.
- [49] Ellakany HF, Abuakkada SS, Oda SS and El-Sayed YS. Influence of low levels of dietary aflatoxins on *Eimeria tenella* infections in broilers. *Trop Anim Health Pro* 2011; 43, 249-257.
- [50] Bailey R, Kubena L, Harvey R, Buckley S and Rottinghaus G. Efficacy of various inorganic sorbents to reduce the toxicity of aflatoxin and T-2 toxin in broiler chickens. *Poult Sci* 1998; 77, 1623-1630.
- [51] Pasha T, Farooq M, Khattak F, Jabbar M and Khan A. Effectiveness of sodium bentonite and two commercial products as aflatoxin adsorbents in diets for broiler chickens. *Anim Feed Sci Tech* 2007; 132, 103-110.
- [52] Valchev I, Kanakov D, Hristov T, Lazarov L, Binev R, Grozeva N and Nikolov Y. Investigations on the liver function of broiler chickens with experimental aflatoxicosis. *Bulg J Vet Med* 2014; 17.
- [53] Joshi D, Srivastav SK, Belemkar S and Dixit VA. *Zingiber officinale* and 6-gingerol alleviate liver and kidney dysfunctions and oxidative stress induced by mercuric chloride in male rats: A protective approach. *Biomed Pharmacother* 2017; 91, 645-655.
- [54] Motawi TK, Hamed MA, Shabana MH, Hashem RM and Naser AFA. *Zingiber officinale* acts as a nutraceutical agent against liver fibrosis. *Nutr metabo* 2011; 8, 40.