

Evaluation of Diaphragmatic electromyography of cervical spinal cord hemi section in Rat model

Samah Fouad¹, Basem²Awad², Awad Rizk³, Shaymaa Rezk⁴ and Esam Mosbah³

¹Medical experimental research center, Faculty of Medicine, Mansoura University, Egypt.

² Department of Neurosurgery, Faculty of Medicine, Mansoura University, Egypt.

³ Department of Surgery, Anesthesiology and Radiology, Faculty of Veterinary Medicine, Mansoura University, Mansoura, Egypt.

⁴ Department of Cytology and Histology, Faculty of Veterinary Medicine, Mansoura



ARTICLE HISTORY

Received: August 4, 2021

Revised: August 24, 2022

Accepted: September 2, 2021

Correspondence to: Samah Fouad, Tel: 002001273934778; drsamahawad85@yahoo.com

ABSTRACT

Objective: Estimation the degree of induced hemisection damage of the cervical segments of the two separately diaphragmatic pillars in rat model using Electromyography (EMG).

Design: Prospective controlled study.

Animals: Sixteen Sprague dawley rats were divided into 2 groups

Procedures: Cervical hemi lateral cord section below the cervical dorsal root number 2 was induced with micro scalpel. After 28 days post-injury, EMG record was done at the two diaphragmatic crural regions, followed by histopathological and immunohistochemical examinations.

Results: There was significant decrease in mean integrated EMG activity of LT diaphragmatic muscles than RT one in the hemi sectioned group $P < 0.05$. Moreover, there was a significant decrease ($P < 0.05$) in the integrated traces (mv) for peak burst area of LT diaphragmatic muscles activity. On histopathological examination, affected neurons of hemi-sectioned group appeared shrunken with chromatolysis, others were completely lost and replaced by cavities. The neutrophil adjacent to the necrotic neurons lost its homogeneous appearance and appeared vacuolated or edematous with significant decrease in the number of viable motor neurons compared to the control group ($P < 0.05$). On other hand, the astrocytosis become more evident and the number of astrocytes was significantly increased ($P < 0.05$). The surrounding white matter exhibited severe degeneration and demyelination. Glial fibrillary acidic protein (GFAP) immune expression for hemi-sectioned group was significantly increased than control group ($P < 0.05$)

Conclusion and clinical relevance: Parallel impairment of the diaphragmatic EMG occurred to the decrease in the number of viable motor neurons of the anterior horn of the cervical segment below the level of the cervical hemisection together with the disintegration of Nissl bodies and the developed astrocytosis.

Keywords: Electromyography (EMG), cervical spine hemi section, Glial fibrillary acidic protein (GFAP), Rat.

1. INTRODUCTION

Spinal cord injury (SCI) usually leads to loss of motor and sensory function below the site of injury [1] leading to degenerative processes affecting ascending and descending pathways that carry information between the brain and the spinal cord [2]. Unilateral hemi section of high cervical spinal cord results in the immediate cessation of ipsilateral phrenic activity and paralysis of the hemi diaphragm due to phrenic motor neuron (PhMN) loss and consequent denervation at the diaphragm neuromuscular and injury to descending bulbospinal respiratory axons and consequent silencing of spared PhMNs [3]. A broad spectrum strategies has been potentially examined to enhance recovery in animal models with spinal cord injury. Estimation of the cervical spine traumatic damage and evaluation of the induced recovery is needed. It is important to have a sensitive test to evaluate the efficiency of a therapeutic strategy. EMG recording after spinal cord hemi section translate the degree of damage of traumatic injury of cervical segments [4]. The aim of current study is to evaluate the functional state of diaphragmatic muscles through EMG after spinal cord hemi section and correlate it to the histological structure and the immunohistochemistry for GFAP immune peroxidase of cervical cord.

2. MATERIALS AND METHODS

2.1. Animals, housing and feeding

The present study was carried out on a total number of 16 female Sprague–Dawley rats (body weight 200–250 gram). Rats were bred and housed at temperature 20°C–25°C in the animal house of Medical Experimental Research Center (MERC), Faculty of Medicine, at Mansoura University. They were conditioned in standard metallic cages (4 rats per cage) with an alternating 12 h light – dark cycle. They were acclimatized to the laboratory conditions, fed standard rat chow and water was available ad libitum. The experimental protocol of this work was approved by the Local Ethical Committee, Faculty of Medicine, and Mansoura University in accordance with the Ethics committee of national research Center-Egypt.

2.2. Study design

Sixteen female rats were recruited and allocated in to two groups Group (1) :(control group, 8rats) with no lesion and intervention. Group (2): (C2 segment hemi section Group, 8rats).

Rats were anaesthetized by IP injection of a mixture 75mg/kg ketamine Hcl (Ketamax 50mg/ml , Troikaa Pharmaceuticals Ltd, Gujarat, India) and 10 mg/kg Xylazine Hcl (Xylajet 20mg/ml, ADWIA, Egypt) [5].

Rats were positioned on a heated surgical plate of wax, with the nose pointing at 90° angle to the surgeon **Figure 1(A)**. Maintain the body temperature around 37.5 °C throughout the surgery skin

incision between C1 and C3 was done to expose spinal vertebrae. The rhomboid muscle was dissected to access the spinalis muscles (surrounding the vertebra). The spinalis muscle from C1 to C3 vertebra was retracted. The C2 vertebra with a prominent apophysis was appeared, the muscle around the dorsal part of the vertebra was cleaned using sterile cotton swabs. The apophysis of C2 was carefully removed with a rongeur. Then the dorsal spinal cord was exposed. Laminectomy (dorsal hemi laminectomy) was insured **Figure 1(B)**. With a forceps dissection of bone was done rostra-caudally and the dura along C2 and CSF was sponged up.

A lateral cord section below the cervical dorsal root number 2 was done with micro scalpel. The extent of the lesion is close enough to reach the midline of the spinal cord **Figure 1(C)**. The muscles sutured with 3/0 absorbable suture and the back sutured with 3/0 nylon **Figure 1(D)** [6]. Two diaphragmatic pillars using EMG were recorded after 28 days. Postmortem histological sections for both histological and immunohistochemical examination were performed (GFAP).

2.3. Evaluation of cervical spinal cord hemi section

Functional assessment of diaphragmatic muscles paralysis was estimated after 28 days of hemi sectioning using Biopac system inc. with electrode MEC110C. The following criteria were used to establish the state of ipsilateral hemi diaphragm EMG activity:- Mean frequency (MNF) is an average frequency which is calculated as the sum of product of the EMG power spectrum and the frequency divided by the total sum of the power spectrum [7] and peak estimation [8].

For assessment of hemi diaphragmatic paralysis, the animals were anesthetized with urethane 97% in a dose of 1.2g/kg I/P at 28th days after hemi section, and a laparotomy was performed to expose the abdominal surface of the hemi diaphragm ipsilateral to hemi section. A pair of bipolar recording electrodes was inserted into the crural regions of the diaphragm. Electrophysiological assessment of activity in the two hemi diaphragms was then conducted [4]. Rats in each group were euthanized by me / P injection of overdose of urethane in the 28th postoperative day.

At the end of the study all rats were deeply anesthetized with urethane and their cervical vertebral column was exposed dorsally at the site of the lesion. The spinal cord was removed, transversally cut and fixed in neutral buffer formalin for 48 hours. Fixed samples were dehydrated with ascending grades of ethyl alcohol (70, 80, 90 and 100, 1 hour each), cleared in xylene and paraffin embedded, 5 µm thickness sections were obtained using a rotatory microtome and mounted in coated glass slides for H&E and Cresyl Violet stain to characterize the spinal tissue architecture in the two groups [9, 10] or in positive glass slides for GFAP immune peroxidase to examine the distribution and

GFAP immune peroxidase was applied. Briefly, spinal cord sections were deparaffinized and rehydrated and the primary anti-GFAP antibody (1:1000 dilution, polyclonal goat, anti-rat, IgG) was used for 2 hours at room temperature then was washed and stained with secondary antibody (ready to use) for 15 min at room temperature. Horse-reddish peroxidase substrate was applied

until the brown color was obviously detected then sections were counterstained with hematoxylin for 3 min [11].

Five different sections from eight different animals from each group were selected for morphometric analyses using the image programme LAS EZ software. Cresyl violet stained sections (40 x magnifications) were used to count the total numbers of viable motor neurons and astrocytes. GFAP stained sections (40 x magnifications) were used to estimate the density of GFAP expression that was expressed as percent.

2.4. Statistical analysis

All the data obtained from the experiment were expressed as means ± SD. Statistical analysis of data was carried out by software SPSS program package version 17 using Student t test for testing the significant differences of the variables between the control and the hemi section groups. Results were considered significant only at the level of ($p \leq 0.05$).

3. RESULTS

3.1. Clinical findings

The hemi sectioned rats developed gradually decreased activity, decreased appetite, decrease respiratory activity of diaphragmatic muscles, pale appearance of conjunctiva and some rats suffered from weight loss. All these clinical signs were diminished gradually.

3.2. EMG findings

Table 1. Effects of cervical left spinal cord hemisection on Diaphragmatic EMG, Viable motor neurons, Astrocyte count and GFAP density% (mean ±SD; n=8).

	Cervical section group (n=8)	Hemi group (n=8)	Control group(n=8)
EMG mean (mV)			
Right(RT)	0.906±0.054		1.089 ±0.049
Left(LT)	0.900 ±0.054		0.357 ±0.049*
PP-EMG (mV)			
Peak Right	2.075±0.127		2.024 ± 0.096
Peak Left	2.099 ± 0.164		0.545±0.103*
Viable motor neurons	03.733 ±1.629		00.333 ±0.488*
Astrocyte count	32.730 ± 4.464		68.070±5.574*
GFAP density%	1.732 ± 0.567		16.1991± 0.327*

Student t-test test, Significance corresponds to $P < 0.05$. *Significance in comparison to SHAM, and for EMG; ■ comparing left to right diaphragm

There was significant decrease in mean integrated EMG activity of LT diaphragmatic muscles than RT one in the hemi sectioned group $P < 0.05$. The integrated traces (mv) for peak burst area of RT and LT showed no significant changes in control group (**Figure 1**), in the other hand, there was a significant decrease in LT diaphragmatic muscles activity compared to RT one in hemi sectioned group ($P < 0.05$) (**Table 1; Figure1**).

3.3. Histomorphometric results

The light microscopic examination of Spinal cord from the control group exhibited viable motor neurons irregular with a basophilic cytoplasm and a light vesicular nucleus with prominent nucleus (**Figure3- a1, a2**). The Nissl granules distributed in the cytoplasm of their soma and dendrites and appeared as a mottled basophilic structure by cresyl violet stain (**Figure4- a1, a2**). On

other hand, the surrounding neuroglia cells only identified by their nuclear morphology with H&E or cresyl violet stains; the astrocytes had relatively large light-stained nucleus meanwhile the oligodendrocytes had dark small nucleoli and localized in close contact with neuronal body (Figure3, 4- a1, a2). The white matter had a fine network appearance of myelinated nerve fiber named tracts which formed from central axons, unstained myelin sheath and outermost neurolemma (Figure3-a3).

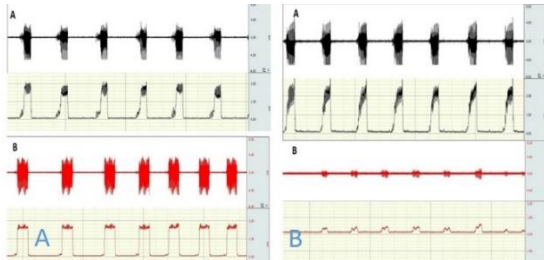


Figure 1: (A) Raw integrated EMG recording of RT (A) < (B) diaphragmatic muscle in control group there was no significant difference between mean integrated EMG of RT and Lt diaphragmatic activity. (B) Raw integrated EMG recording of RT (A) < (B) diaphragmatic muscle in hemi section group. There was significant decrease in activity of Lt diaphragmatic muscles than RT one in the hemi sectioned group.

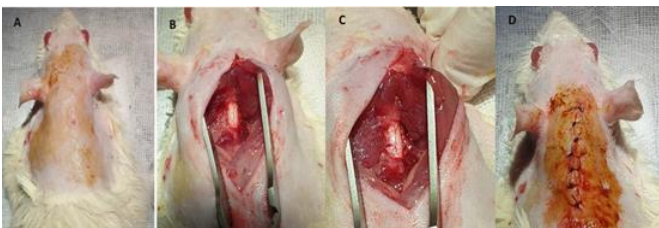


Figure 2. Cervical spinal cord hemi section in rats A) Rats were positioned on a heated surgical plate of wax ,B) dorsal hemi laminectomy was insured ,C) lateral section under the cervical dorsal root number 2 was severed with the micro scissors D) The muscles were sutured with 3/0 absorbable suture(polysorb) as a protective layer , the back the skin was suture with 3/0 nylon sutures

By contrast, hemi sectioned group, had variety of neurodegenerative alterations (Figure3,4- b1, b3) in the gray matter of the ventral horn and surrounding white matter. Some of affected neurons appeared shrunken and dark eosinophilic (dead red neuron) with pyknotic nucleus with loss of Nissl granules (chromatolysis); others were completely lost and replaced by cavities. Some of these cavities enclosed remnant of degenerated neurons. The neuropil adjacent to the necrotic neurons lost its homogeneous appearance and appeared vacuolated or edematous with significantly ($P < 0.05$) decrease in the number of viable motor neurons compared to the control group. On other hand, the astrocytosis become more evident and the number of astrocytes was significantly ($P < 0.05$) increased compared to the control group. The surrounding white matter exhibited severe degeneration and demyelination.

3.4. Immune histochemistry results for GFAP

The expression of GFAP was mainly detected in the primary cell process of astrocytes. The astrocyte appears as branched cells with small soma. Immunostained sections from control group revealed normal (resting) astrocytes appeared with fine cytoplasmic process, well-spaced from each other and with mild

GFAP immune expression (Figure5-a1, a3). Conversely, after hemisection injury, the astrocytes appeared with bold projection, overlapped with each other and with significantly ($P < 0.05$) increase in GFAP expression (Figure5-b1, b3).

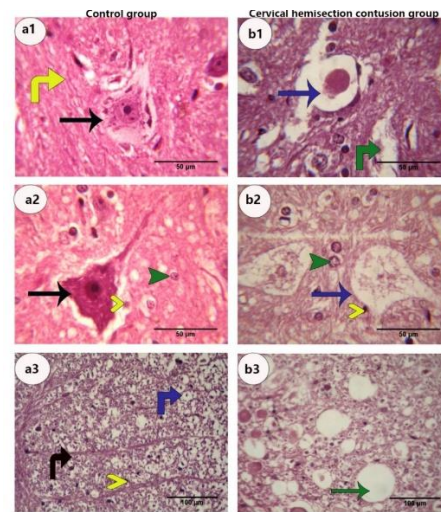


Figure 3. Photomicrograph of a section of normal rat's spinal cord stained with H&E stain control group (a) and those with hemi-section (b). Control group, a1) showing viable multipolar motor neurons (black arrow) with basophilic cytoplasm, large vesicular nucleus and prominent nucleolus, Homogenous neuropils (yellow vertical arrow). a2) Homogenous neuropil (yellow vertical arrow). Astrocytes with light vesicular nucleus (green arrow head), oligodendrocytes with dark nucleus. a3) white matter contains axon fiber (blue vertical arrow), axon tract (black vertical arrow). On the other hand in cervical hemisection group. b1) gray matter showing vacuoles containing debris of dead neurons (blue arrow), dishomogenous vacuolation neutrophil (green vertical arrow). b2) gray matter showing astrocytosis (blue arrow head), oligodendrocytes with dark nucleus (yellow arrow head), b3) white matter has completely degenerated axons fibers leaving white empty spaces (green arrows), (100x magnification).

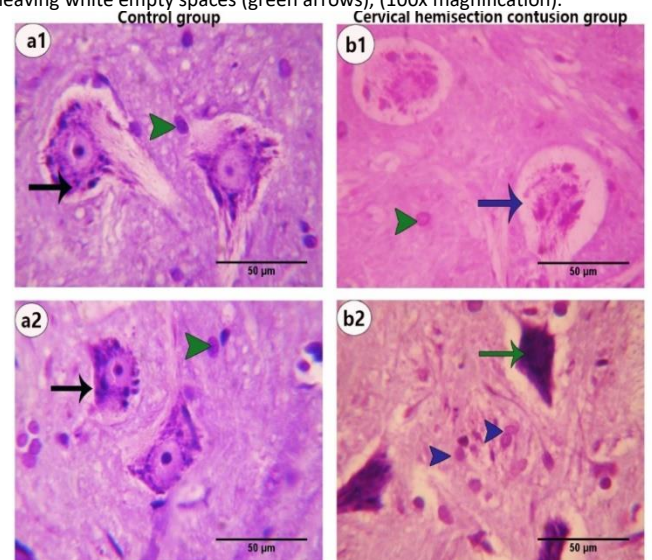


Figure 4. Photomicrograph of cresyl violet stained section of rat's spinal cord control group (a) and spinal cord hemi section group (b). a1, a2) viable multipolar motor neurons (black arrow) with basophilic cytoplasm, large vesicular nucleus, prominent nucleolus and mottled Nissl granules (black arrow), Astrocytes (green arrow head), on the other hand gray matter of hemi section group b1) showing vacuoles containing debris of dead neurons (blue arrow), b2) gray matter showing astrocytosis (blue arrow head), neuron with chromatolysis (blue arrow), and dark dead neuron (green arrow). (100x magnification).

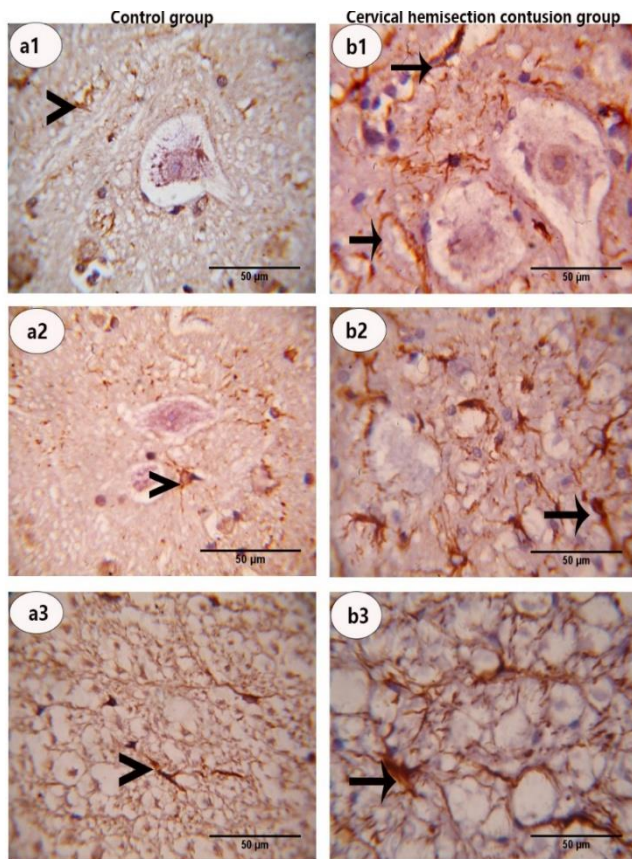


Figure 5. Photomicrograph of Enzyme immune histo- chemical staining of spinal cord for GFAP. Control group a1,a2.a3) showing, resting astrocytes with fine cytoplasmic process and mild GFAP expression (arrow head) on the other hand hemi section group showing b1,b2,b3) showing stimulated astrocytes with bold cytoplasmic process and strong GFAP expression (arrow) (100x magnification).

4. DISCUSSION

Spinal cord injury is a devastating problem results in loss of sensation and partial or complete paralysis depending on the severity of injury[12].

We aimed to develop an animal model to reproduce many clinical and pathological events of spinal cord injury. In the present study, cervical spinal cord hemisection was performed at level C2. Spinal hemisection at the second cervical spinal cord (i.e., C2Hx) is widely used to investigate respiratory function following cervical SCI in rodent models[13] ; [14]; [15] ;[16] .

The present control positive group displayed progressive decrease in functional activity of diaphragmatic ms, which is considered identical signs of cervical SCI, matching with the previous results of [17]; [15] [3]; [18]; [19].

Mean burst area and peak amplitude of the EMG activity ipsilateral to injury (injured side) was then presented as a percentage of the activity contralateral to injury (non-injured side). EMG recordings from both sides of the diaphragm showed a unique alternating interaction. As intense activity

on the lesioned side was significantly decreased , these results agree with [20]; [21] .

EMG finding in positive control group, showed a significant decrease between RT and LT diaphragmatic ms due to PhMN degeneration, interruption of descending axonal populations, this agree with [3, 22]; [23].

At 28th day post-injury, the mean integrated activity of left diaphragm recorded in hemi section rats (0.357 +0.049) ipsilateral to the cord hemi section was significantly lower than in the control group (0.90 +0.054) $P < 0.05$. This result is in agreement with [24] [25] [3] .

The spinal cord in the current study in positive control group was associated with severe degeneration and demyelination in the axons leaving wide and empty periaxonal vacuoles. Our results are in harmony with results of [26] who showed total axonal degeneration and large empty spaces in white matter following SCI as a part of post-traumatic infarction and generalized edema.

In the present study the histological examinations of spinal cord revealed evident distorted histo architecture in the gray matter of ventral horn and white matter after the spinal cord hemi section injury. The degenerated neurons appear shrunken with pyknotic nuclei, loss of Nissl granules (chromatolysis). Numbers of viable motor neurons were markedly decreased leaving wide cavities in the gray matter compared to the control group (Figure 2).

In the current study; the GFAP immunohistochemical expression was significantly increased after SCI and the astrocytes appeared hypertrophied with bold projection and overlapped with each other (Astrogliosis also known as astrocytosis) . At the same time their numbers were also significantly increased compared to the control group through both the grey matter and the white matter .These findings are agreement with many previous studies that have noted steadily astrocytes activation and GFAP expression up regulation following nervous tissue injury [27];[28].

Astrocytes have a critical role in CNS, these cells act as support cells for neurons, energy reserves, cerebral blood flow and neurogenesis [29]-[30, 31]. Numerous pathological stimuli such as neurodegenerative disease, trauma, aging, infarction and ischemia enhance the proliferation of astrocytes and change in the expression of its proteins leading to both functional and morphological changes. After activation, astrocytes secrete several neurotoxic substances and express an enhanced level of glial GFAP. GFAP over expression is related to degree of reactivity, hypertrophy of cell body and increase in the number of cellular processes [32],[33].The increase in GFAP production was considered a hallmark of astrogliosis and an early biomarker of neurotoxicity [34].

However GFAP is an intermediate filament protein expressed primarily by astrocytes in the CNS. Its main function is to maintain astrocyte structural integrity and aid in cell movement and shape change [32] .They have a regulatory role

of brain functions that are implicated in neurogenesis and synaptogenesis, controlling blood–brain barrier permeability and maintaining extracellular homeostasis. Mature astrocytes also express some genes enriched in cell progenitors, suggesting they can retain proliferative potential

Astrocytosis (reactive astrogliosis) is an abnormal increase in the number of astrocytes due to the destruction of nearby neurons from central nervous system (CNS) trauma, infection, ischemia, stroke, autoimmune responses or neurodegenerative disease [34]. In the current study; the GFAP immunohistochemical expression was significantly increased after SCI and the astrocytes appeared hypertrophied with bold projection and overlapped with each other (Astrogliosis also known as astrocytosis). At the same time the numbers of astrocyte were also significantly increased compared to the control group through both the grey matter and the white matter. These findings are agreed with many previous studies that have noted steadily astrocytes activation and GFAP expression up regulation following nervous tissue injury [27] [28]. In the present study, cervical spinal cord hemi section was performed at level C2. Spinal hemi section at the second cervical spinal cord is widely used to investigate respiratory function following cervical SCI in rodent models [15] [16].

In the current study; the GFAP immunohistochemical expression was significantly increased after SCI and the astrocytes appeared hypertrophied with bold projection and overlapped with each other (Astrogliosis also known as astrocytosis). At the same time their numbers were also significantly increased compared to the control group through both the grey matter and the white matter. These findings are agreement with many previous studies that have noted steadily astrocytes activation and GFAP expression up regulation following nervous tissue injury [27];[28].

Astrocytosis or referred to as reactive astrogliosis is an abnormal increase in the number of astrocytes due to the destruction of nearby neurons from central nervous system (CNS) trauma, infection, ischemia, stroke, autoimmune responses or neurodegenerative disease [34].

Astrocytes have a critical role in CNS, these cells act as support cells for neurons, energy reserves, cerebral blood flow and neurogenesis [29]-[30, 31]. Numerous pathological stimuli such as neurodegenerative disease, trauma, aging, infarction and ischemia enhance the proliferation of astrocytes and change in the expression of its proteins leading to both functional and morphological changes. After activation, astrocytes secrete several neurotoxic substances and express an enhanced level of glial GFAP. GFAP over expression is related to degree of reactivity, hypertrophy of cell body and increase in the number of cellular processes [32],[33]2016. The increase in GFAP production was considered a hallmark of astrogliosis and an early biomarker of neurotoxicity [34]

However, GFAP is an intermediate filament protein expressed primarily by astrocytes in the CNS. Its main function is

to maintain astrocyte structural integrity and aid in cell movement and shape change [32]. They have a regulatory role of brain functions that are implicated in neurogenesis and synaptogenesis, controlling blood–brain barrier permeability and maintaining extracellular homeostasis. Mature astrocytes also express some genes enriched in cell progenitors, suggesting they can retain proliferative potential.

5. Conclusion

parallel impairment of the diaphragmatic EMG occurred to the decrease in the number of viable motor neurons of the anterior horn of the cervical segment below the level of the cervical hemisection together with the disintegration of Nissl bodies and the developed astrocytosis suggest a value of the peripheral study of the phrenic nerve activity through recording the diaphragmatic EMG as a marker of the state of cervical cord injury.

Conflict of interest

The authors declare that there is no conflict of interest in the current research work.

Animal ethics committee permission

This study was approved by the Local Ethical Committee, Faculty of Medicine, and Mansoura University in accordance with the Ethics committee of national research Center-Egypt

Authors' contribution

S. F., B. A., A. R. and E. M. conceived of the idea, contributed to its design and performed the experiment as well as performed the analysis of the data and drafted the

Manuscript, S. R. performed and interpreted the histopathology. All authors read and approved the final manuscript.

Acknowledgment

Many grateful thanks for Prof. Dr. Mohamed-Ahdy A.A Saad Professor of clinical pharmacology; Faculty of Medicine, Mansoura University for his help in acquisition of the data.

5. REFERENCES

- [1] Dietz V, Curt A. Neurological aspects of spinal-cord repair: promises and challenges. *The Lancet Neurology*. 2006;5:688-94. [https://doi.org/10.1016/S1474-4422\(06\)70522-1](https://doi.org/10.1016/S1474-4422(06)70522-1)
- [2] Freund P, Weiskopf N, Ward NS, Hutton C, Gall A, Ciccarelli O, et al. Disability, atrophy and cortical reorganization following spinal cord injury. *Brain*. 2011;134:1610-22. <https://doi.org/10.1093/brain/awr093>
- [3] Ghosh B, Wang Z, Nong J, Urban MW, Zhang Z, Trovillion VA, et al. Local BDNF delivery to the injured cervical spinal cord using an engineered hydrogel enhances diaphragmatic respiratory function. *Journal of Neuroscience*. 2018;38:5982-95. <https://doi.org/10.1523/JNEUROSCI.3084-17.2018>
- [4] Jimenez-Ruiz F, Khurram OU, Zhan W-Z, Gransee HM, Sieck GC, Mantilla CB. Diaphragm muscle activity across respiratory motor behaviors in awake and lightly anesthetized rats. *Journal of Applied Physiology*. 2018;124:915-22. <https://doi.org/10.1152/jappphysiol.01004.2017>
- [5] Flecknell P. *Laboratory animal anaesthesia*: Academic press; 2015.
- [6] Liu F, Zhang Y, Schafer J, Mao G, Goshgarian HG. Diaphragmatic recovery in rats with cervical spinal cord injury induced by a theophylline nanoconjugate: Challenges for clinical use. *The journal of spinal cord*

- medicine. 2019;42:725-34. <https://doi.org/10.1080/10790268.2019.1577058>.
- [7] Fuglsang-Frederiksen A. The utility of interference pattern analysis. *Muscle & Nerve: Official Journal of the American Association of Electrodiagnostic Medicine*. 2000;23:18-36. [https://doi.org/10.1002/\(SICI\)1097-4598\(200001\)23:1<18::AID-MUS4>3.0.CO;2-B](https://doi.org/10.1002/(SICI)1097-4598(200001)23:1<18::AID-MUS4>3.0.CO;2-B).
- [8] Tarata M, Spaepen A, Puers R. The accelerometer MMG measurement approach, in monitoring the muscular fatigue. *Measurement Science Review*. 2001;1:47-50.
- [9] Bancroft C, Joshi S, Rundle A, Hutson M, Chong C, Weiss CC, et al. Association of proximity and density of parks and objectively measured physical activity in the United States: A systematic review. *Social science & medicine*. 2015;138:22-30. <https://doi.org/10.1016/j.socscimed.2015.05.034>.
- [10] Carson EA, Anderson E. Prisoners in 2014. US Department of Justice, Office of Justice Programs, Bureau of Justice Statistics, NCI. 2015;247282:2.
- [11] Petrosyan K, Tamayo R, Joseph D. Sensitivity of a novel biotin-free detection reagent (Powervision™) for immunohistochemistry. *Journal of histotechnology*. 2002;25:247-50. <https://doi.org/10.1179/014788802794791951>.
- [12] Cox A, Varma A, Banik N. Recent advances in the pharmacologic treatment of spinal cord injury. *Metabolic brain disease*. 2015;30:473-82. <https://doi.org/10.1007/s11011-014-9547-y>
- [13] Plosker GL, Gauthier S. Cerebrolysin. *Drugs & aging*. 2009;26:893-915. <https://doi.org/10.2165/11203320-000000000-00000>
- [14] Sharma HS, Sharma A, Moessler H, Muresanu DF. Neuroprotective effects of cerebrolysin, a combination of different active fragments of neurotrophic factors and peptides on the whole body hyperthermia-induced neurotoxicity: modulatory roles of co-morbidity factors and nanoparticle intoxication. *International review of neurobiology*. 2012;102:249-76. <https://doi.org/10.1016/B978-0-12-386986-9.00010-7>
- [15] Gill L, Ross H, Lee K, Gonzalez-Rothi E, Dougherty B, Judge A, et al. Rapid diaphragm atrophy following cervical spinal cord hemisection. *Respiratory physiology & neurobiology*. 2014;192:66-73. <https://doi.org/10.1016/j.resp.2013.12.006>
- [16] Ciesla MC, Seven YB, Allen LL, Smith KN, Asa ZA, Simon AK, et al. Serotonergic innervation of respiratory motor nuclei after cervical spinal injury: Impact of intermittent hypoxia. *Experimental neurology*. 2021;113609. <https://doi.org/10.1016/j.expneurol.2021.113609>
- [17] Mantilla CB, Greising SM, Stowe JM, Zhan W-Z, Sieck GC. TrkB kinase activity is critical for recovery of respiratory function after cervical spinal cord hemisection. *Experimental neurology*. 2014;261:190-5. <https://doi.org/10.1016/j.expneurol.2014.05.027>
- [18] Gutiérrez AH, Cámara GEC, Carranza VG, García ST, de León FCP. Phrenic nerve neurotization utilizing half of the spinal accessory nerve to the functional restoration of the paralyzed diaphragm in high spinal cord injury secondary to brain tumor resection. *Child's Nervous System*. 2020;36:1307-10. <https://doi.org/10.1007/s00381-019-04490-9>
- [19] Michel-Flutot P, Mansart A, Deramaudt TB, Jesus I, Lee K-Z, Bonay M, et al. Permanent diaphragmatic deficits and spontaneous respiratory plasticity in a mouse model of incomplete cervical spinal cord injury. *Respiratory Physiology & Neurobiology*. 2021;284:103568. <https://doi.org/10.1016/j.resp.2020.103568>
- [20] Alilain WJ, Li X, Horn KP, Dhingra R, Dick TE, Herlitze S, et al. Light-induced rescue of breathing after spinal cord injury. *Journal of Neuroscience*. 2008;28:11862-70. <https://doi.org/10.1523/JNEUROSCI.3378-08.2008>
- [21] Li K, Javed E, Hala TJ, Sannie D, Regan KA, Maragakis NJ, et al. Transplantation of glial progenitors that overexpress glutamate transporter GLT1 preserves diaphragm function following cervical SCI. *Molecular Therapy*. 2015;23:533-48. <https://doi.org/10.1038/mt.2014.236>
- [22] Fuller D, Doperalski N, Dougherty B, Sandhu M, Bolser D, Reier P. Modest spontaneous recovery of ventilation following chronic high cervical hemisection in rats. *Experimental neurology*. 2008;211:97-106. <https://doi.org/10.1016/j.expneurol.2008.01.013>
- [23] Michel-Flutot P, Mansart A, Deramaudt TB, Jesus I, Lee K-Z, Bonay M, et al. Permanent diaphragmatic deficits and spontaneous respiratory plasticity in a mouse model of incomplete cervical spinal cord injury. *Respiratory Physiology & Neurobiology*. 2020;284:103568. <https://doi.org/10.1016/j.resp.2020.103568>
- [24] Baussart B, Stamegna J-C, Polentes J, Tadie M, Gauthier P. A new model of upper cervical spinal contusion inducing a persistent unilateral diaphragmatic deficit in the adult rat. *Neurobiology of disease*. 2006;22:562-74. <https://doi.org/10.1016/j.nbd.2005.12.019>
- [25] Mantilla CB, Gransee HM, Zhan W-Z, Sieck GC. Motoneuron BDNF/TrkB signaling enhances functional recovery after cervical spinal cord injury. *Experimental neurology*. 2013;247:101-9. <https://doi.org/10.1016/j.expneurol.2013.04.002>
- [26] Tatebayashi Y, Lee MH, Li L, Iqbal K, Grundke-Iqbal I. The dentate gyrus neurogenesis: a therapeutic target for Alzheimer's disease. *Acta neuropathologica*. 2003;105:225-32. <https://doi.org/10.1007/s00401-002-0636-3>
- [27] Kang W, Hébert JM. Signaling pathways in reactive astrocytes, a genetic perspective. *Molecular neurobiology*. 2011;43:147-54. <https://doi.org/10.1007/s12035-011-8163-7>
- [28] Hol EM, Pekny M. Glial fibrillary acidic protein (GFAP) and the astrocyte intermediate filament system in diseases of the central nervous system. *Current opinion in cell biology*. 2015;32:121-30. <https://doi.org/10.1016/jceb.2015.02.004>
- [29] Abbott NJ. The milieu is the message. *Nature*. 1988;332:490-1. <https://doi.org/10.1038/332490a0>
- [30] Okamoto M, Inoue K, Iwamura H, Terashima K, Soya H, Asashima M, et al. Reduction in paracrine Wnt3 factors during aging causes impaired adult neurogenesis. *The FASEB Journal*. 2011;25:3570-82. <https://doi.org/10.1096/fj.11-184697>
- [31] Allaman I, Bélanger M, Magistretti PJ. Astrocyte-neuron metabolic relationships: for better and for worse. *Trends in neurosciences*. 2011;34:76-87. <https://doi.org/10.1016/j.tins.2010.12.001>
- [32] Eng LF, Ghirnikar RS, Lee YL. Glial fibrillary acidic protein: GFAP-thirty-one years (1969-2000). *Neurochemical research*. 2000;25:1439-51. <https://doi.org/10.1023/A:1007677003387>
- [33] Anderson M, Burda J, Ren Y, Ao Y, O'Shea T, Kawaguchi R, & Sofroniew, MV (2016). Astrocyte scar formation aids central nervous system axon regeneration. *Nature*. 532:195-200. <https://doi.org/10.1038/nature17623>
- [34] Liu Y, Zhu H, Liu M, Du J, Qian Y, Wang Y, et al. Downregulation of Pax3 expression correlates with acquired GFAP expression during NSC differentiation towards astrocytes. *FEBS letters*. 2011;585:1014-20. <https://doi.org/10.1016/j.febslet.2011.02.034>