



Histopathological study on the effect of Artemisinin multiple doses on the pathogenesis and immune reaction of *Trichinella spiralis* in albino rats.

Zeinab Dwidar, Hebatallah Mahgoub *, Iman Ibrahim, Ahmed Elshaieb

1 Pathology department, Faculty of Veterinary Medicine, Mansoura University, Egypt.

ARTICLE HISTORY

Received: January 18, 2022

Revised: February 4, 2022

Accepted: February 6, 2022

Corresponding author: Heba Mahgoub;

Email:

hebamahgoub@mans.edu.eg

Phone: +201112316644

ABSTRACT

Objective: The aim of this study was to determine the therapeutic effect of Artemisinin (AR) multiple doses on the pathogenesis and immune reaction of (*T. spiralis*) during the intestinal and muscular phases in albino rats.

Design: Randomized controlled study.

Animal Models: The experiment was performed on 80 adult male and female albino rats weighting (160 g \pm 20 g) and their age ranged from (4-6) weeks.

Procedures: rats were divided into four experimental groups; 20 rats/each. 1-(Control negative) group. 2- *T. spiralis* infested (TR) group: each animal was orally infested with 300 *T. spiralis* larvae. 3- *T. spiralis* treated (AR+TR) group: each animal in this group was orally infested with 300 *T. spiralis* larvae followed by treatment with AR at dose of (400 mg / kg body weight) one day post infection (PI) for three successive days and other three successive doses on days 21, 22 and 23 PI. 4-(AR) group, animals received AR only at the same dose.

Results: The current study recorded that AR administration showed improvement of the intestinal histopathological, morphohistopathological analysis and ultra-structural alterations during the intestinal phase. In addition to its efficacy in decreasing the larval count during the muscular phase. However minimal improvement in the histopathological and ultra-structural alterations of the infested skeletal muscles were observed. The findings of muscular morphohistopathological analysis, biochemical and hematological analysis were not improved.

Conclusion and clinical relevance: AR had significant anthelmintic efficacy against the adult stage of *T. spiralis* during the intestinal phase and minimal efficacy against encysted muscle larvae

Keywords: *Trichinella spiralis*, Artemisinin, intestine, skeletal

1. Introduction

Trichinella spiralis (*T. spiralis*) is an intracellular parasitic nematode with several unique features, causes a disease called "trichinellosis" or "trichinosis" [1, 2]. Trichinellosis is a globally distributed parasitic zoonosis that recorded in many countries of different climatic zones [3, 4]. It affects the human health and causes severe economic losses in the porcine animal industry and food safety [5, 6].

Infestation is acquired through the ingestion of undercooked pork meat containing *T. spiralis* encysted first stage larvae [7-9]. Excystation of the ingested larvae takes place in the stomach then they move to the small intestine where they molt and mature into adult males and females during the first 3–7 days PI [10]. After maturation and fertilization, the newly born larvae migrate through the blood or the lymphatic system to the striated muscles where they alter the structural, chemical environment of the myocytes forming new structure called nurse cells [11, 12].

The host defense mechanisms including humoral and cellular immunity are elicited by parasitic infestations. In addition, the type of the parasite and the stage of infestation direct this response [13, 14].

Invasion and destruction of the small intestine mucosa by *T. spiralis* induce the host immune response resulting in many pathological changes [15]. Type 2 helper T lymphocyte (Th2) produce cytokines that interact with intestinal mucosal immune cells as eosinophils, Dendritic cells, goblet cells and mast cells causing regulatory changes in these cells [16]. Th2 cells release interleukin 5 (IL-5) that induce the infiltration of eosinophils [17] in addition IL-4 and IL-13 induce goblet cell hyperplasia [18, 19]. Furthermore Type 1 helper T lymphocyte (Th1) produce Interferon gamma (IFN γ) that stimulated goblet cell hyperplasia in experimentally infested mice [10].

Artemisinin (Quinghaosu) (AR) is a natural compound extracted from a plant called *artemisia annua* (Quinghao). It was discovered from many years ago and used by the Chinese to cure haemorrhoides and fever. AR was widely used as anti-malarial drug [20], in addition to its efficacy

against other protozoa and helminthes as as *Leishmania spp*, *Acanthamoeba spp* and *Taenia spp* [21, 22], *Toxocara canis*, *Trichinella spiralis*, *Globodera rostochiensis*, *Haemonchus contortus*, *Meloidogyne spp*, *Xiphinema index*, *Echinococcus spp.*, *Echinostoma spp.*, *Fasciola spp.*, *Clonorchissinensis*, *Opisthorchis viverrini*, *Taenia crassiceps*, *monogenea*, *Dactylogyus* and *Gyrodactylus* [23]

Artemisinin showed antimicrobial [24], antiviral activities [25] against *influenza virus A* [26, 27], some types of human *herpes viruses* [27, 28] as HIV-1 [27], hepatitis B and C [29, 30] beside bovine viral diarrhea virus [31]. Moreover it showed some activities *in vitro* against some fungi as *Pneumocystis carinii* [32, 33]. AR was used in some disease models as nephritic syndrome [34] rheumatoid arthritis [35, 36], pancreatitis [37] and lupus nephritis [38-40]. Additionally AR played an effective role against cancer cells using several mechanisms as reducing the angiogenesis [41].

The aim of this study was to determine the therapeutic effect of AR multiple doses on the pathogenesis and immune reaction of *T.spiralis* during the intestinal and muscular phases in albino rats.

3. MATERIAL AND METHODS

3.1. Animals

The laboratory-bred parasite free, 80 adult albino rats of both sexes, 4–6 weeks old, weighted 140 g - 180 g each, were used in this study. The animals were obtained from Medical Experimental Research Center (MERC), Faculty of Medicine, Mansoura University and accommodated in Pathology lab, Faculty of Veterinary Medicine, Mansoura University for 7 days before the start of the experimental procedure. The animals were placed in plastic cages (ten rats / cage), supplied with standard pellet rat diet, water ad libitum and maintained under standard human and hygienic conditions of temperature, humidity, and light.

3.2. Parasite

The used *T. spiralis* isolate was originally obtained from infected pork meat from Cairo abattoir and maintained in Theodore Bilharz Research Institute (Giza, Egypt), by consecutive passages in rats and mice. This isolate was genotyped as *T. spiralis* by the European Union Reference Laboratory for Parasites, Superior Institute of Health, Rome, Italy.

3.3. Medication

Artemisinin extract powder, purity (approximately 100 %), was purchased from Xi'an Longze Biotechnology Co., LTD, China. AR was dissolved in 3% ethanol, 7% Tween 80 and distilled water forming suspension. It was administered orally at dose of (400 mg/kg body weight) [42-44] one day PI for three successive days and other three successive doses on days 21, 22 and 23 PI.

3.4. Experimental design

The experimental procedures were carried out according to the Ethical Committee of faculty of veterinary Medicine, Mansoura University. Eighty adult albino rats of both sexes were divided into four experimental groups, 20 rats/each) and each group subdivided into (10 males and 10 females). The first group; (control group), the second group; (*T. spiralis*) (TR) group, each animal was orally infested with 300 *T. spiralis* larvae [45-48]. The third group; (AR+TR) group, each animal in this group was orally infested with 300 *T. spiralis* larvae followed by treatment with AR at dose of (400 mg / kg body weight) [42-44] one day PI for three successive days and other three successive doses on days 21, 22 and 23 PI. The fourth group; (AR) group, animals in this group received AR only at the same dose.

3.5. Sample collection

On the 7th day and 35th day PI, blood samples were collected from the orbital sinus of the eye under complete anesthesia of ether. Blood samples were collected in EDTA containing test tubes for blood film analysis. Other samples were collected for serum separation via centrifugation at 4000 rapid per minute for ten minutes. Serum samples were stored at -20°C until assessment of creatine kinase (CK) and lactate dehydrogenase (LDH) activity. Ten rats from each group were given ether anesthesia and sacrificed on 7th day PI. The small intestine of each sacrificed rat was removed and opened longitudinally then washed several times, cut into pieces about 1cm and preserved separately in neutral buffered formalin 10% for histopathological examination. Other intestinal samples were fixed in 4% glutaraldehyde and used for transmission electron microscopic examination. The remaining animals in each group were sacrificed on the 35th day PI. Samples from thigh, masseter, diaphragm and intercostal muscles were collected and preserved separately in formalin 10% for the histopathological examination. Other muscle samples were fixed in 4% glutaraldehyde and used for transmission electron microscopic examination.

3.6. Biochemical analysis

3.6.1 Determination of creatine kinase activity

Creatine phosphokinase serum level was measured by creatine kinase (CK) activity assay, the used kit was purchased from MG Science & Technology Center, Cat.No. MG 238 001. In the presence of CK enzyme, creatine phosphate reacted with adenosine diphosphate (ADP) to produce creatine and adenosine triphosphate (ATP). ATP reacted with glucose in the presence of hexokinase enzyme to produce ADP and glucose-6-phosphate. In the presence of glucose-6-phosphate dehydrogenase, glucose-6-phosphate reacted with nicotinamide adenine dinucleotide phosphate (NADP+) to produce 6-phosphogluconate and NADPH +H. The enzyme activity of creatine kinase in the serum sample U / L was calculated by $4127 \times \Delta A$ at 340 nm/min [49].

3.6.2 Determination of lactate dehydrogenase activity

The used kit was purchased from MG Science & Technology Center, Cat. No. MG 283 001. The lactate dehydrogenase (LDH) activity was determined by kinetic ultraviolet method. LDH enzyme is a hydrogen transfer enzyme that catalyzes the oxidation of L-Lactate to pyruvate. The initial rate of the NADH oxidation is directly proportional to the catalytic LDH activity. It is determined by measuring the decrease in absorbance at 340 nm. LDH activity was calculated by using the following formulae: $U/L=8095 \times \Delta A$ at 340 nm/ min [50, 51].

3.7. Blood film preparation

Blood samples were collected in EDTA containing test tubes. A drop of blood was withdrawn by capillary tube and placed 1 cm away from the slide edge, the spreader slide was positioned in front of the blood drop then moved backwards to touch the blood drop led to its spread along the width of the slide then the spreader slide was pulled across the slide in about 30 to 45 degrees above the angle of the blood. The smears were left for air drying then fixed by absolute methanol or ethyl alcohol [52]. The dried smears stained with 10% Giemsa solution by putting the slides on the staining rack and covering them by the stain for 8-10 minutes then rinsing them by water and let them to dry in air. For manual differential leukocytic cells count the stained blood films were examined under the light microscope and white blood cells were counted and differentiated according to their appearance [53].

3.8. Histopathological technique (hematoxylin and eosin H&E)

The fixed tissue specimens were trimmed under fume hood to fit into cassettes and labeled. Tissue samples were routinely processed in ascending grades of ethanol (ethanol 70% for 1hr then 95% for 1hr two times then 100% for 1hr two changes), xylene (two changes) for 1hr then embedded in melted paraffin. Serial sections of 4-5µm were cut for H&E staining and IHC using microtome then placed on clean glass slides. At time of staining, slides were dewaxed by xylene, rehydrated by descending grades of ethanol then washed, placed in hematoxylin for 3-5 min, washed by tap water and counterstained by eosin for 8 min. Finally, slides were washed in water, dehydrated by ethanol, cleared by xylene, mounted with quick mount. The stained slides were examined by light microscope [54]

3.9. Morphohistopathological analysis of H&E-stained sections

Random images were captured from each tissue section using XSZ-07 series of biological microscope (China) and Apex Minigrab (UK). H&E stained sections were analyzed automatically using Image J <https://imagej.nih.gov/ij>. Intestinal images were analyzed for the intestinal villous height, the intestinal villous width, the intestinal width of the villous lamina propria, the size of the intestinal inflammatory area, the depth of the intestinal inflammatory area, the height of the intestinal villous epithelial cells, goblet cells count and eosinophils count. Muscular images were analyzed for the area of ensheathing

nurse cell complex, the size of larval surrounding area of inflammatory reaction, the encapsulated larval minor axis length, the encapsulated larval major axis length and the thickness of collagen sheath.

3.10. Transmission electron microscopy (TEM)

Freshly cut intestinal and muscular samples, size 1mm³ each, were collected and immersed in 5% neutral buffered glutaraldehyde for 12 hours. Then were washed in cacodylate buffer at PH 7.2 for three to four times, 20 minutes each, followed by fixation in 1% osmium tetroxide for two hours. Dehydration was done using ascending grades of ethyl alcohol 30%, 50%, 70%, 90%, and 100% for two hours.

Specimens were embedded in Epon 812 via using of gelatin capsules. For polymerization, the embedded specimens were kept in incubator at 35f °C or one day, 45 °C for another day, and 60 °C for three days. Using LKB ultra microtome, semi thin sections at thickness of (0.5-1µm) were prepared from the prepared blocks, stained with toluidine blue, examined by light microscope, photo-figured, and regions for preparation of ultrathin sections were oriented. Ultrathin sections were prepared at thickness of (500- 800 Å) by Leica ultramicrotome.

The ultrathin sections were fixed on copper grids (200 µm meshes), contrasted in uranyl acetate for 15 minutes and lead citrate for five minutes and examined by transmission electron microscope [55]. Ultrathin sections were observed at 160 kV using a JEOL JEM -2100 at EM Unit, Mansoura University, Egypt.

3.11. Statistical analysis

Data of morphometric measurements were statistically analyzed using either T-test or one-way analysis of variance (ANOVA) followed by Tukey's multiple comparisons test using P value ≤ 0.05 , GraphPad Prism for macOS, version 9.3.0 (345). Statistical analysis of other data was executed using analysis of variance (ANOVA) with Tukey's test for group of comparison. The hypothesis was depending on the lack of difference between groups ($p < 0.05$) [56].

4. RESULTS

4.1. Clinical signs and mortality observations

Male and female rats in control, AR and AR+ TR groups were apparently normal with normal feed intake, physical conditions, activities and viability. Meanwhile, rats in *T.spiralis* infested group showed loss of appetite, weakness, low viability and decrease in the normal physical activities started at the 2nd day PI and persisted until the end of the experiment. The mortality rates of the current study were calculated for each group and represented in percentage (%). The mortality rates in control, AR, AR+TR groups were zero % in both sexes, while the mortality rate in TR group was 10 % among the males.

4.2. Biochemical analysis

4.2.1. Creatine kinase (CK)

4.2.1.1. The intestinal phase

The assessment of CK concentration in the serum during the intestinal phase showed no significant effect of trichinosis infection on CK level, when compared to the negative control group. Meanwhile, AR+TR showed a significant increase in the level of CK, when compared to the control group (Figure 1).

4.2.2. Lactate dehydrogenase (LDH)

4.2.2.1. The intestinal phase

Estimation of LDH concentration in the serum during the intestinal phase showed no significant variation across control, TR and AR groups. Meanwhile, AR+TR group showed significant increase in the levels of LDH when compared to control group (Figure 1).

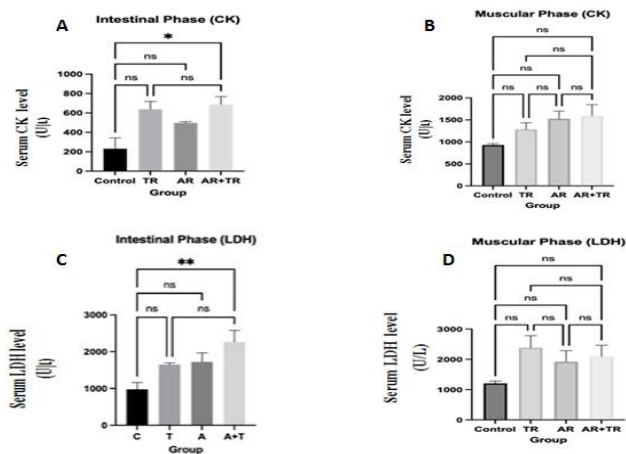


Figure 1. A,B) Assessment of CK concentration in the serum during the intestinal phase and muscular phase. C,D) Assessment of LDH concentration in the serum during the intestinal phase and muscular phase. * means significant when P value < or equal to 0.05. AR= artemisinin group, TR= trichinilla spiralis group, AR+TR= Artemisinin+ Trichinella group

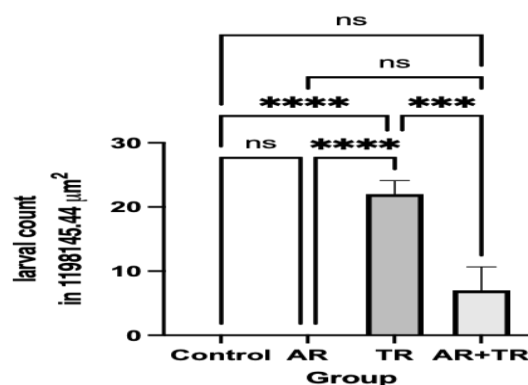


Figure (3): A, B, D) Microscopic images of the small intestine showing mild inflammatory reaction in villous lamina propria (L) in the negative control, AR and AR+TR groups. C) Moderate inflammatory reaction in villous lamina propria (L) in the TR group. H&E. 125x.

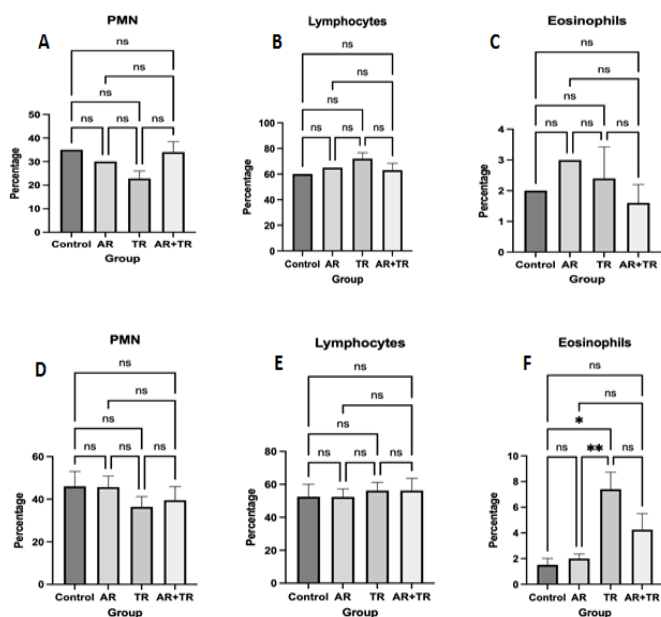


Figure (2): A,B,C) Assessment of PMN cells, lymphocytes and eosinophils percentage in Giemsa stained blood films during the intestinal phase. D,E,F) Assessment of PMN cells, lymphocytes and eosinophils percentage in Giemsa stained blood films during the muscular phase. * means P value < or equal to 0.05 and ** means P value < or equal to 0.01.

4.2.1.2. The muscular phase

The assessment of CK concentration in the serum during the muscular phase showed no significant variation across all experimental groups (Figure 1).

4.2.2.2. Muscular phase

Assessment of LDH concentration in the serum during the muscular phase showed no significant variation across all experimental groups (Figure 1).

4.3. Blood film analysis

4.3.1. The intestinal phase

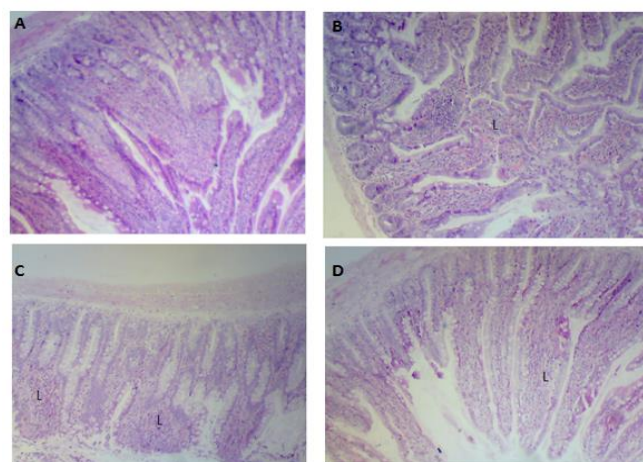


Figure (4): The effect of AR treatment A) on the duodenal villous height (VH), B) the duodenal villous width (VW), C) the duodenal inflammatory area and D) the depth of duodenal inflammatory area of in trichinosis infestation model in rats. Data represents the mean fold change in villous height, villous width, duodenal inflammatory area and the mean depth of duodenal inflammatory area to the whole intestinal depth from the negative control ± SEM. * means significant when P value ≤ 0.05.

Assessment of polymorphnuclear (PMN), lymphocytes and eosinophils percentages in Giemsa stained blood films during the intestinal phase showed no significant variation across all experimental groups (Figure 2).

The lamina propria of the intestinal villi in negative control and AR groups showed mild inflammatory reaction. The lamina propria of the intestinal villi in TR group showed moderate inflammatory reaction along with various forms of eosinophils, mast cells and lymphocytes. Meanwhile, mild inflammatory reaction in the lamina propria of the intestinal villi is shown in AR+TR group beside many eosinophils, mast cells, macrophages and lymphocytes (Figure 3).

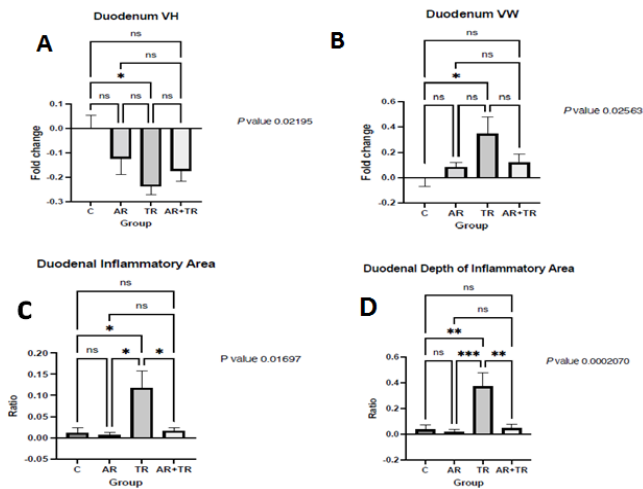


Figure (5): The effect of AR treatment on A) the duodenal goblet cell count (GC), B) duodenal eosinophils count (EC), C) duodenal villous epithelial height, D) duodenal width of villous lamina propria in trichinosis infestation model in rats. Data represents the mean ratio of the GC count, the mean EC, the mean fold change of duodenal villous epithelial height and the duodenal width of villous lamina propria from the negative control \pm SEM. * means significant when P value \leq 0.05. ** = P value \leq 0.01. *** = P value \leq 0.001.

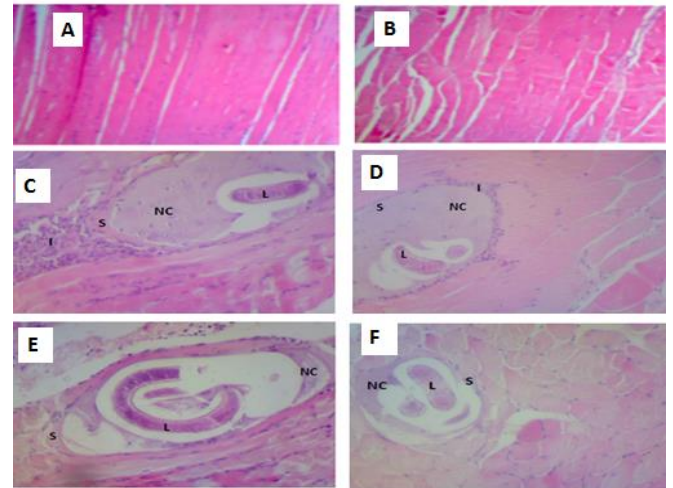


Figure (7): A,B): Microscopic images of the thigh muscles in the negative control and AR groups showing elongated skeletal muscle fibers with acidophilic cytoplasm, multiple peripheral basophilic nuclei and transverse striations H&E. 50x, 125x. C) The thigh muscles in the TR group showing trichinosis larva (L) in a nurse cell complex, where it is surrounded by a nucleated mass (nurse cell= NC) followed by a collagen sheath (S) triggering moderate inflammatory reaction (I). 125x. D) The thigh muscles in the AR+TR group are focally replaced by a migrating larva in a nurse cell complex, where it is surrounded by a nucleated mass (nurse cell= NC) followed by a collagen sheath (S) and a mild inflammatory reaction (I). 125x. H&E. E) Microscopic image of the diaphragm in the TR group showing trichinosis larva (L) in a nurse cell complex, where it is surrounded by a nucleated Mass (nurse cell= NC) followed by collagen sheath(S).H&E.125x. F) The diaphragm in the AR+TR group showing trichinosis larva (L) in a nurse cell complex, where it is surrounded by a nucleated mass (nurse cell= NC) followed by collagen sheath (S) without evidence of an inflammatory reaction. H&E. 125x H&E.

4.4.1.2. Intestinal morphohistopathological analysis

TR group showed significant decrease in the duodenal villous height (VH) compared to control and AR groups along with significant increase in the duodenal villous width (VW) when compared to control and AR groups (P value \leq 0.05). Meanwhile, duodenal VH and duodenal VW showed no significant variation between TR group and AR+TR group (Figure 4). Assessment the duodenal inflammatory area showed significant increase in TR group when compared to control, AR and AR+TR groups (P value \leq 0.05) (Figure 4). The depth of the duodenal inflammatory area in TR group showed highly significant increase when compared to control, AR+TR and AR groups (P value \leq 0.01, \leq 0.01 and \leq 0.001), respectively (Figure 4). Duodenal goblet cells count showed highly significant increase in TR group when compared to control, AR+TR group and AR groups P value \leq 0.0001. Also the AR+TR group showed significant increase in the duodenal goblet cells count when compared to control and AR groups (Figure 5). Duodenal eosinophils

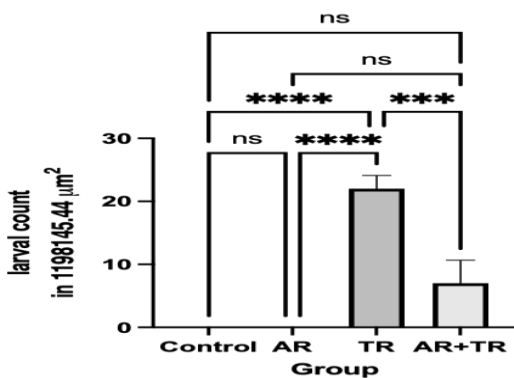


Figure (6): Larval count in the skeletal muscles of experimental rats using light microscopy. *** means significant when P value $<$ or equal to 0.001 and **** means P value $<$ or equal to 0.0001.

4.3.2. The muscular phase

Assessment of PMN and lymphocytes percentages in Giemsa stained blood films during the muscular phase showed no significant variation across control, AR and AR+TR groups. Meanwhile assessment of eosinophils percentage in TR group showed a significant increase when compared to other experimental groups (Figure 2).

4.4. Pathological examinations

4.4.1. The intestinal phase

4.4.1.1. H&E-stained sections

count showed significant increase in TR group when compared to control, AR+TR group and AR groups (P value ≤ 0.01) (Figure 5). The TR group showed significant increase in the duodenal villous epithelial height when compared to control, AR+TR and AR groups (P value ≤ 0.05 , $\leq 0.001 \leq 0.001$, respectively) (Figure 5). Assessment of the duodenal width of villous lamina propria showed significant increase in TR group when compared to control, AR+TR and AR groups P value ≤ 0.05 , $\leq 0.001 \leq 0.001$, respectively (Figure 5).

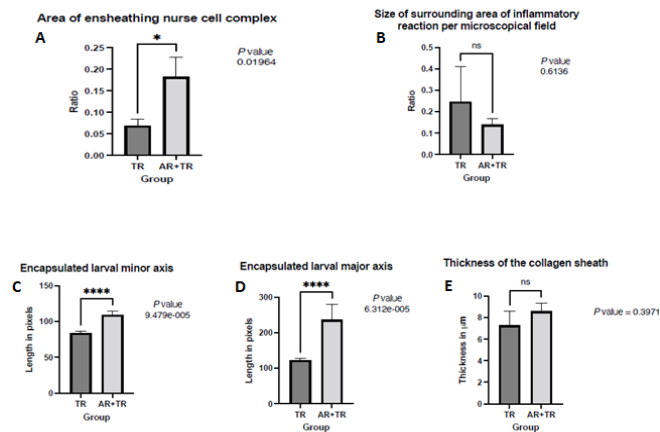


Figure (8): The effect of AR treatment on the area of ensheathing nurse cell complex (A), on the size of larval surrounding area of inflammatory reaction per microscopical field (B), on the encapsulated larval minor axis length (C), on the encapsulated larval major axis length (D) and on the thickness of collagen sheath in trichinosis infestation model in rats. Data represents the mean area as a ratio \pm SEM. * means significant when P value ≤ 0.05 . **** means significant when P value ≤ 0.0001

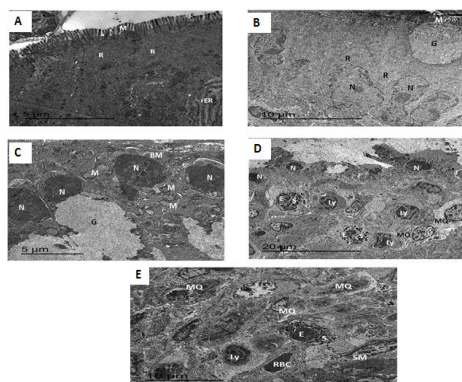


Figure (9): TEM micrograph of an intestinal section from the negative control group, showing focal shortening (S) of the microvilli (M). The enterocytes show evident ribosomes (R) and rough endoplasmic reticulum (rER). B) The intestinal section from AR group, showing mucin-containing granules (G) of a goblet cell that could be seen towards the brush border (microvillous, M) of the cell. The enterocytes show evident ribosomes (R) and nuclei (N). C,D) intestinal section from TR group, showing mucin-containing granules (G) of goblet cells that could be seen filling the cytoplasm of the cells. In this sections, the enterocytes show general pyknosis, where nuclear chromatin is condensed (N). The enterocytes show evident mitochondria (M). The basement membrane could be seen beneath the intestinal enterocyte layer (BM). In addition to marked leukocytic aggregation that consisted of Lymphocytes (Ly), macrophages (MQ) and eosinophils (E) that are dominated by large ovoid specific granules (S). E) The intestinal section from AR+TR group, showing smooth muscle cells (SM) surrounded with slight leukocytic aggregation that consisted of Lymphocytes (Ly), macrophages (MQ), and eosinophils (E) that are dominated by large ovoid specific granules (S). Erythrocytes (RBC) are also evident in this section.

4.4.2. The muscular phase

4.4.2.1. Larval count

Larval count in the skeletal muscles revealed marked decrease in AR +TR group compared to TR group (Figure 6).

4.4.2.2. H&E stained sections

H&E-stained sections of the skeletal muscles of control and AR groups showed normal histopathological appearance. Histopathological examination of the thigh and diaphragm sections from TR group showed focal replacement of the skeletal muscles with multiple encysted *T. spiralis* larvae surrounded by thick collagen sheath. Local inflammatory reaction, composed mainly of eosinophils, macrophages, lymphocytes and mast cells surrounded the nurse cells and intensified at their poles. The muscle fibers showed degenerative changes, hyalinization, loss of their striation (Figure 7).

Thigh muscle fibers of AR+TR group were focally replaced by migrating larvae in nurse cell complex, where they were surrounded by a nucleated masses (nurse cells) followed by collagen sheaths and mild inflammatory reactions that were composed predominantly of lymphocytes, eosinophils and fibroblasts. The histopathological examination of the diaphragm showed evident trichinosis larvae in a nurse cell complex followed by collagen sheath without evidence of inflammatory reaction (Figure 7).

4.4.2.3. Muscles morphohistopathological analysis

H&E sections were analyzed automatically to determine the effect of AR treatment during the muscular phase. The area of ensheathing nurse cell complex showed significant increase in AR+TR group when compared to TR group while the thickness of collagen sheath showed no significant variation between the same groups. The encapsulated larval minor and major axis length showed highly significant increase in AR+TR group when compared to TR group. Moreover, the size of larval surrounding area of inflammatory reaction showed no significant variation between AR+TR and TR groups (Figure 8).

4.4.3. Transmission electron microscope (TEM) findings

4.4.3.1 Intestinal phase

TEM micrograph of the intestinal section from the negative control group showed focal shortening of the microvilli and the enterocytes showed evident ribosomes and rough endoplasmic reticulum. Meanwhile the intestinal section from AR group showed mucin-containing granules of a goblet cell that could be seen towards the brush border of the cell and the enterocytes showed evident ribosomes and nuclei. The intestinal section from TR group showed mucin-containing granules of goblet cells that could be seen filling the cytoplasm of the cells. In addition, the enterocytes showed general pyknosis, where nuclear chromatin was condensed with evident mitochondria and basement membrane could be seen beneath the intestinal enterocyte layer. Moreover marked leukocytic aggregation

consisted of Lymphocytes, macrophages and eosinophils dominated by large ovoid specific granules were noticed in the intestinal section from TR group.

The intestinal section from AR+TR group showed smooth muscle cells surrounded with slight leukocytic aggregation consisted of Lymphocytes, macrophages and eosinophils that dominated by their large ovoid specific granules. In addition, mucin-containing granules of goblet cells seen in the cytoplasm of the cells ready for exocytosis and following exocytosis along with evident mitochondria, free ribosomes and rough endoplasmic reticulum were noticed in the enterocytes (Figure 9).




Figure (10): A,B)TEM micrographs of the skeletal muscle cells from the negative control and AR groups, in longitudinal section demonstrating the main elements of the conducting system. They are composed of alternating broad light I bands and dark A bands. Fine dark lines called Z lines can be seen bisecting the I bands. Note the nucleus (N), the mitochondria (M), and the sarcoplasmic reticulum (SR). The plane of section has also included a part of a tubule system which branches to encompass several different sarcomeres. C,D) the skeletal muscle from TR group, showing *Trichinella spiralis* larva that focally replaced the muscular tissue. The epi-, exo-, and meso-cuticular regions are evident of the annulated larval cuticle (Ep, epicuticle; Ex, exocuticle; Me, mesocuticle). The larval sections also shows the hypodermis (H), the somatic muscles of the body (M) and a stichocyte (S). The section also elucidates separation of superficial layers of the cuticle from the overlying muscular layer (*). In addition the neighbouring muscle cells show mild separation of myofibrils (Sp) and loss in the continuity of the plasmalemma or sarcolemma (P). Other local muscle cells show closer appearance of normal muscle histology (NM). The intercellular space (ICS) is widened because of the inflammatory edema, where mild leukocytic reaction that consisted mainly of lymphocytes (Ly) and mild necrotic debris (ND) could be recorded in the section. E) skeletal muscle section from AR+TR group, showing blunting of epicuticle of the muscle larva (Arrow).

4.4.3.2. Muscular phase

TEM micrographs of the skeletal muscle cells from the negative control and AR groups showed normal appearance. Meanwhile the skeletal muscle from TR group showed *T. spiralis* larva with annulated cuticle was focally replaced the muscular tissue and the superficial layers of the cuticle was separated from the overlying muscular layer. *T. spiralis* larva was surrounded by a nurse cell and ensheathed by a collagen sheath. The neighboring muscle cells showed mild separation of myofibrils in addition to loss in the continuity of the plasmalemma or sarcolemma also the intercellular spaces were widened because of the inflammatory edema with mild leukocytic reaction that consisted mainly of lymphocytes and mild necrotic debris. TEM micrograph of a skeletal muscle section from AR+TR

group showed blunting of epicuticle of the muscle larva (Figure 10).

5. Discussion

Trichinellosis is a globally distributed parasitic zoonosis that recorded in many countries of different climatic zones [57, 58]. The anthelmintic effect of medicinal plant extracts or their derived components on trichinosis infestation took a great concern and research due to the evidence of anthelmintic drug resistance, defective safety profile and their low efficacy against *Trichinella spiralis* (*T. spiralis*) encapsulated larvae [59, 60]. One of the tested pharmaceutical compound against trichinosis infestation is AR [44, 61].

In the current study, we investigated the anthelmintic effect of AR (400 mg/kg Body weight) on one day PI for three successive days (intestinal phase) and other three successive doses on days 21, 22 and 23 PI (muscular phase) against *T. spiralis* infestation in experimental rats. The histopathological examination of the small intestine in TR group showed moderate inflammatory reaction. Meanwhile, small intestine of AR+TR group showed mild inflammation as in control group. The image analysis of the small intestine should that the villous height and villous width were negatively affected in TR group when compared to the other groups. The villi exhibited shortening and blunting with increased width of the villous lamina propria that may be due to the inflammatory cells infiltration. In accordance with [62-64] who noticed that the core of the intestinal villi and the submucosa were packed with lymphocytes, plasma cells, eosinophils, neutrophils and fibroblast. In addition to sloughing and ulceration of the lining epithelium, decrease in the villous height to crypt depth ratio, hyperplasia of crypts of Lieberkühn, mucosal lymphoid tissue and goblet cells were all seen in the mice orally infested with 200 TSL. [62-64].

The size and the depth of the inflammatory area in addition to goblet cells in AR+TR group showed prominent improvement compared to TR group. These results were in accordance with [44] who recorded reduction in the intensity of the inflammatory infiltrate in AR treated group along with marked improvement of the other histopathological changes of the intestine, including the number of goblet cells. Moreover, eosinophils count in AR+TR group showed significant decrease when compared to TR group these results in accordance with [65] who recorded strong anti-inflammatory effects of artesunate (Artemisinin derivative) on the pulmonary cell infiltration in OVA-challenged mice, especially eosinophil and neutrophil recruitment. Furthermore artesunate showed significant drop in total cell count, eosinophil, lymphocyte counts, suppressed the goblet cell hyperplasia and prevented the mucous hypersecretion in the bronchoalveolar lavage fluid of OVA-challenged mice [66]. These findings may be attributed to the ability of AR and its derivatives to suppress IL-4, IL-5 and IL-13 release through inhibition of the phosphoinositide 3-kinase/Akt pathway [66]. The TEM findings confirmed these results as the intestine of TR

group showed diffuse enterocytic necrosis with pyknotic nuclei as the nuclear chromatin were condensed along with marked leukocytic aggregation consisted of Lymphocytes, macrophages and eosinophils. This result was in agreement with the TEM findings confirmed these results as the intestine of TR group showed diffuse enterocytic necrosis with pyknotic nuclei as the nuclear chromatin were condensed along with marked leukocytic aggregation consisted of Lymphocytes, macrophages and eosinophils. . These findings were in agreement with [44] who recorded reduction in the intensity of the inflammatory infiltrate in AR treated group along with marked improvement of the other histopathological changes of the intestine.

In this study, the improvement of the intestinal histopathological changes in AR+TR group may be attributed to AR ability to enhance the Th-2 immune responses and suppress Th-1 and Th-17 responses in addition to the increase in the serum level of IL10 that promoted the adult *T. spiralis* expulsion and regulated the cellular immune responses led to decrease the tissue destruction [65, 67, 68]

Concerning the AR anti-parasitic effect during the muscular phase, the existing finding revealed a significant reduction in the muscles larval count in AR+ TR group compared to the untreated TR group. This finding was in accordance with [44] who recorded a significant reduction in the larval count by 72% associated with marked reduction in the intensity of inflammatory infiltrates in the skeletal muscles. In addition, [61] recorded significant reduction in the number of encysted larvae and their surrounding cellular inflammatory infiltrates.

In this study the decreased muscles larval count may be attributed to the harmful effect of AR on the fertility of *Trichinella* adult parasite during the intestinal phase and enhancement the worm expulsion [69]. In addition, it had the ability to induce oxidative and metabolic stress to the worm that led to deterioration of the male and female reproductive organs [70-72] along with disruption the mitochondrial electron transport chain, suppression of Na⁺/K⁺-ATPase and Mg²⁺-ATPase that led to disruption of the worm osmoregulatory system [73, 74]. The histopathological examination of the sections from TR group were in accordance with [44, 62, 63, 75] who noticed multiple encysted *T. spiralis* larvae surrounded by nurse cells and thick collagen capsule.

Skeletal muscle fibers of AR+TR group showed similar histopathological findings as TR group except the histopathological examination of the thigh muscles showed mild inflammatory reaction and the diaphragm showed some trichinosis larvae in a nurse cell complexes followed by collagen sheath without evidence of inflammatory reaction. These findings partially agreed with [44, 61] who recorded significant improvement of the muscle histopathological findings with decreased the surrounding cellular infiltrates and increased the muscles regeneration. Similar findings were noticed during TEM examination. The skeletal muscle of TR group showed *T. spiralis* larva

surrounded by a nurse cell and ensheathed by a collagen sheath. The neighbouring muscle cells showed mild separation of myofibrils in addition to loss in the continuity of the plasmalemma or sarcolemma also the intercellular spaces were widened because of the inflammatory edema and mild leukocytic reaction that consisted mainly of lymphocytes and mild necrotic debris. In addition, the exposed muscles showed moderate to marked degenerative changes. The myofibrils showed sever damage loss the striation, mitochondrial dilation and damage. These findings were in accordance with [76, 77] who stated that the invaded skeletal muscles lost their striation due to disturbance and damage of their contractile filaments. In addition the nuclei of affected myocytes were severely affected and exhibited many alterations in positions, numbers, shapes and took central positions instead of normal peripheral sites [78]. Almost all organelles showed remarkable changes; smooth, rough sarcoplasmic reticulum with widening T- tubules and free ribosomes were massively proliferated. Moreover the mitochondrial size, number and enzymatic environment were greatly altered [79].

The muscles of AR+TR group showed partial cuticular damage with obvious blunting of epicuticle of the muscle larva. These results were partially agreed with [44]. Who noticed great morphological variations after AR treatment such as swellings, blebbing, sloughing of the cuticle along with losing some of normal body structures. The destructive activity of AR against parasites may be attributed to its unusual peroxide bridge which is a known source of oxygen free radicals [80]. These free radicals played important role in the parasites destruction and host immunity activation during different stages of *T. spiralis* infection [81].

In this investigation, detailed comparative image analysis of the skeletal muscle sections of TR and AR+TR groups showed that AR treatment did not affect the area of ensheathing nurse cell complex, thickness of collagen sheath, the encapsulated larval minor and major axis length and the size of larval surrounding area of inflammatory reaction. AR treatment had minimal destructive effect on encysted *T. spiralis* larvae during the muscular phase. This result partially conflicted with [44] who reported potent destructive action of AR during the muscular phase and [61] who reported moderate destructive action of AR during the muscular phase.

The minimal destructive action of AR in this study could be attributed to the time of drug administration where AR was administered on day 21 PI after larval encapsulation and nurse cell formation so the nurse cells act as a barrier against the drug and reducing their efficacy against these larvae. However the previous investigation applied the AR treatment 2 weeks post infection before larval encystation and nurse cell formation [44]. In addition [61] applied AR treatment 10-12 days PI for targeting the migrating larvae before encystation so the larval count decrease led to decrease the muscle inflammatory reaction and the tissue

destruction also gave other doses 28-30 days PI to affect the encysted larvae. As well as the low bioavailability of AR after oral administration that may be due to the low transepithelial transport across the intestinal mucosa or to its poor dissolution properties in the intestinal fluids that decrease its absorption [82]

In this investigation, the eosinophils percentage showed significant increase in TR group only in the muscular phase when compared to other experimental groups. These results were in accordance with [83-86] who stated that the eosinophils count in *T. spiralis* infected groups showed extremely significant higher values in comparison with control group throughout the experimental period ranging from 10% to 23% of the total leukocytic count. In addition, it was noticed that the eosinophilia reached the peak at 3th to 4th weeks PI then became constant. In this study eosinophils, lymphocytes and PMN percentage in AR+TR group did not show significant variation in comparison with TR group during the intestinal and muscular phases. This result was in accordance with [87] who reported non-significant alternation in the white blood cell count after Artesunate and dihydroartemisinin (AR derivatives) administration.

In the present study, the assessment of CK and LDH concentration in the serum as biomarkers of muscular tissues injury during the intestinal phase showed significant increase in the levels of CK and LDH in AR+TR group when compared to control group. In addition, assessment of CK and LDH concentration in the serum during the muscular phase on the day 35 PI showed no significant variation across all experimental groups. These results did not agree with the previous investigations that recorded highly significant increase in CK concentration in *T. spiralis* infected group in comparison with control group on days 15 and 30 PI [46]. Moreover, remarkable increases in CK and LDH were reported in horses infested with *T. spiralis* on the fifth week PI [88] and in guinea pigs infected with *T. spiralis*,

LDH was continued to increase until day 42 PI [89]. The significant increase in serum CK and LDH concentrations in AR+TR group during the intestinal phase may be attributed to the variation in arrival and invasion of *T. spiralis* larvae to the muscular tissue and subsequent large scale myopathy [89].

Abbreviations

(ADP): Adenosine di-phosphate, (AR): Artemisinin, (AR+TR): Artemisinin+ Trichinella, (ATP): Adenosine tri-phosphate, (CK): Creatine kinase, (kg): Kilo gram, (LDH): lactate dehydrogenase, (mg): Milligram, (NADP+): Nicotinamide adenine dinucleotide phosphate, (NBL):newborn larvae, (PI): post infection, (PMN): polymorphnuclear, TEM: Transmission electron microscope, *T. spiralis* : Trichinella spiralis, (TR) Trichinella, TSL:Trichinella spiralis larvae, (Th2):Type 2 helper T lymphocyte.

Acknowledgment

Great thanks are represented to **Dr. Azza Abd El-baky El-baiomy**, Professor of Clinical Pathology, Faculty of Medicine, Mansoura University, for her great help in finishing the biochemical part.

Conflict of interest statement

No conflict of interest.

Research Ethics Committee Permission

The current research work is permitted to be executed according to standards of Research Ethics committee, Faculty of Veterinary Medicine, Mansoura University.

Author's contribution

The study is part of a Master thesis presented to the Department of Pathology, Faculty of Veterinary Medicine, Mansoura University by ZD, where HAM and AFE acted as thesis supervisors.

6. REFERENCES

- [1] Murrell K, Pozio E. Trichinellosis: the zoonosis that won't go quietly. International Journal for Parasitology. 2000;30:1339-49. [https://doi.org/10.1016/S0020-7519\(00\)00132-6](https://doi.org/10.1016/S0020-7519(00)00132-6)
- [2] Jansen A, Schöneberg I, Stark K, Nöckler K. Epidemiology of trichinellosis in Germany, 1996-2006. Vector-borne and zoonotic diseases. 2008;8:189-96. <https://doi.org/10.1089/vbz.2007.0183>
- [3] Sotiraki S, Athanasiou L, Himonas C, Kontos V, Kyriopoulos I. Trichinellosis in Greece: a review. Parasite. 2001;8:S83-S5. <https://doi.org/10.1051/parasite/200108s2083>
- [4] Yadav A. Temjenmongla. Anthelmintic activity of Gynura angulosa against Trichinella spiralis infections in mice Pharmacologyonline. 2006;2:299-306.
- [5] Sturchler D. Trichinella. Exposure: A Guide to Sources of Infections: ASM Press USA.; 2006. p. 582-3. <https://doi.org/10.1128/9781555817510>
- [6] Gottstein B, Pozio E, Nöckler K. Epidemiology, diagnosis, treatment, and control of trichinellosis. Clinical microbiology reviews. 2009;22:127-45. <https://doi.org/10.1128/CMR.00026-08>
- [7] Cui J, Wang Z. An epidemiological overview of swine trichinellosis in China. The Veterinary Journal. 2011;190:323-8. <https://doi.org/10.1016/j.tvjl.2010.12.025>
- [8] Murrell KD, Pozio E. Worldwide occurrence and impact of human trichinellosis, 1986-2009. Emerging infectious diseases. 2011;17:2194. <https://doi.org/10.3201/eid1712.110896>
- [9] Chen Y, Huang B, Huang S, Yu X, Li Y, Song W, et al. Coinfection with Clonorchis sinensis modulates murine host response against Trichinella spiralis infection. Parasitology research. 2013;112:3167-79. <https://doi.org/10.1007/s00436-013-3493-1>
- [10] Ding J, Bai X, Wang X, Wang Y, Shi H, Rosenthal B, et al. Developmental profile of select immune cells in mice infected with Trichinella spiralis during the intestinal phase. Veterinary parasitology. 2016;231:77-82. <https://doi.org/10.1016/j.vetpar.2016.07.019>
- [11] Despommier D. How does Trichinella spiralis make itself at home? Parasitology Today. 1998;14:318-23. [https://doi.org/10.1016/S0169-4758\(98\)01287-3](https://doi.org/10.1016/S0169-4758(98)01287-3)

- [12] Pozio E, Marucci G. Trichinella-infected pork products: a dangerous gift. *Trends in parasitology*. 2003;19:338. [https://doi.org/10.1016/S1471-4922\(03\)00138-7](https://doi.org/10.1016/S1471-4922(03)00138-7)
- [13] Maizels RM, Bundy DA, Selkirk ME, Smith DF, Anderson RM. Immunological modulation and evasion by helminth parasites in human populations. *Nature*. 1993;365:797-805. <https://doi.org/10.1038/365797a0>
- [14] Roitt I, Brostoff J, Male D. *Immunology* 4th edition [Z]. Mosby, UK. 1996.
- [15] Khan W, Collins S. Immune-mediated alteration in gut physiology and its role in host defence in nematode infection. *Parasite immunology*. 2004;26:319-26. <https://doi.org/10.1111/j.0141-9838.2004.00715.x>
- [16] Vallance BA, Blennerhassett PA, Deng Y, Matthaei KI, Young IG, Collins SM. IL-5 contributes to worm expulsion and muscle hypercontractility in a primary *T. spiralis* infection. *American Journal of Physiology-Gastrointestinal and Liver Physiology*. 1999;277:G400-G8. <https://doi.org/10.1152/ajpgi.1999.277.2.G400>
- [17] Capron M. Eosinophils and parasites. *Annales de parasitologie humaine et comparee*. 1991;66:41-5.
- [18] Fallon PG, Jolin HE, Smith P, Emson CL, Townsend MJ, Fallon R, et al. IL-4 induces characteristic Th2 responses even in the combined absence of IL-5, IL-9, and IL-13. *Immunity*. 2002;17:7-17. [https://doi.org/10.1016/S1074-7613\(02\)00332-1](https://doi.org/10.1016/S1074-7613(02)00332-1)
- [19] Kuperman DA, Huang X, Nguyen L, Hölscher C, Brombacher F, Erle DJ. IL-4 receptor signaling in Clara cells is required for allergen-induced mucus production. *The Journal of Immunology*. 2005;175:3746-52. <https://doi.org/10.4049/jimmunol.175.6.3746>
- [20] Liu Y-X, Wu W, Liang Y-J, Jie Z-L, Wang H, Wang W, et al. New uses for old drugs: the tale of artemisinin derivatives in the elimination of schistosomiasis japonica in China. *Molecules*. 2014;19:15058-74. <https://doi.org/10.3390/molecules190915058>
- [21] Shalaby H, Abdel-Shafy S, Abdel-Rahman K, Derbala A. Comparative in vitro effect of artemether and albendazole on adult *Toxocara canis*. *Parasitology research*. 2009;105:967-76. <https://doi.org/10.1007/s00436-009-1479-9>
- [22] Derda M, Hadaś E, Cholewiński M, Skrzypczak Ł, Grzondziel A, Wojtkowiak-Giera A. *Artemisia annua* L. as a plant with potential use in the treatment of acanthamoebiasis. *Parasitology Research*. 2016;115:1635-9. <https://doi.org/10.1007/s00436-016-4902-z>
- [23] Lam NS, Long X, Su X-z, Lu F. Artemisinin and its derivatives in treating helminthic infections beyond schistosomiasis. *Pharmacological research*. 2018;133:77-100. <https://doi.org/10.1016/j.phrs.2018.04.025>
- [24] Appalasaamy S, Lo KY, Ch'ng SJ, Nornadia K, Othman AS, Chan L-K. Antimicrobial activity of artemisinin and precursor derived from in vitro plantlets of *Artemisia annua* L. *BioMed research international*. 2014;2014. <https://doi.org/10.1155/2014/215872>
- [25] Roy S, He R, Kapoor A, Forman M, Mazzone JR, Posner GH, et al. Inhibition of human cytomegalovirus replication by artemisinins: effects mediated through cell cycle modulation. *Antimicrobial agents and chemotherapy*. 2015;59:3870-9. <https://doi.org/10.1128/AAC.00262-15>
- [26] Qian R, Li Z, Yu J, Ma D. The immunologic and antiviral effect of qinghaosu. *Journal of traditional Chinese medicine= Chung i tsa chih ying wen pan*. 1982;2:271-6.
- [27] Efferth T, Marschall M, Wang X, Huong S-M, Hauber I, Olbrich A, et al. Antiviral activity of artesunate towards wild-type, recombinant, and ganciclovir-resistant human cytomegaloviruses. *Journal of molecular medicine*. 2002;80:233-42. <https://doi.org/10.1007/s00109-001-0300-8>
- [28] Naesens L, Bonnafous P, Agut H, De Clercq E. Antiviral activity of diverse classes of broad-acting agents and natural compounds in HHV-6-infected lymphoblasts. *Journal of clinical virology*. 2006;37:569-575. [https://doi.org/10.1016/S1386-6532\(06\)70015-4](https://doi.org/10.1016/S1386-6532(06)70015-4)
- [29] Romero MR, Efferth T, Serrano MA, Castaño B, Macias RI, Briz O, et al. Effect of artemisinin/artesunate as inhibitors of hepatitis B virus production in an "in vitro" replicative system. *Antiviral research*. 2005;68:75-83. <https://doi.org/10.1016/j.antiviral.2005.07.005>
- [30] Paeshuyse J, Coelmont L, Vliegen I, Vandenkerckhove J, Peys E, Sas B, et al. Hemin potentiates the anti-hepatitis C virus activity of the antimalarial drug artemisinin. *Biochemical and biophysical research communications*. 2006;348:139-44. <https://doi.org/10.1016/j.bbrc.2006.07.014>
- [31] Romero MR, Serrano MA, Vallejo M, Efferth T, Alvarez M, Marin JJ. Antiviral effect of artemisinin from *Artemisia annua* against a model member of the Flaviviridae family, the bovine viral diarrhoea virus (BVDV). *Planta medica*. 2006;72:1169-74. <https://doi.org/10.1055/s-2006-947198>
- [32] Merali S, Meshnick SR. Susceptibility of *Pneumocystis carinii* to artemisinin in vitro. *Antimicrobial agents and chemotherapy*. 1991;35:1225-7. <https://doi.org/10.1128/AAC.35.6.1225>
- [33] Ni X, Chen Y. In vitro study of the anti-pneumocystis carinii effect of artemisinin derivatives. *Zhonghua jie he he hu xi za zhi= Zhonghua jiehe he huxi zazhi= Chinese journal of tuberculosis and respiratory diseases*. 2001;24:164-7.
- [34] Razavi A, Nouri HR, Mehrabian F, Mirshafiey A. Treatment of experimental nephrotic syndrome with artesunate. *International journal of toxicology*. 2007;26:373-80. <https://doi.org/10.1080/10915810701493293>
- [35] Xu H, He Y, Yang X, Liang L, Zhan Z, Ye Y, et al. Anti-malarial agent artesunate inhibits TNF- α -induced production of proinflammatory cytokines via inhibition of NF- κ B and PI3 kinase/Akt signal pathway in human rheumatoid arthritis fibroblast-like synoviocytes. 2007. <https://doi.org/10.1093/rheumatology/kem014>
- [36] Cuzzocrea S, Saadat F, Di Paola R, Mirshafiey A. Artemether: a new therapeutic strategy in experimental rheumatoid arthritis. *Immunopharmacology and immunotoxicology*. 2005;27:615-30. <https://doi.org/10.1080/08923970500418786>
- [37] Zhao M, Xue D-B, Zheng B, Zhang W-H, Pan S-H, Sun B. Induction of apoptosis by artemisinin relieving the severity of inflammation in caerulein-induced acute pancreatitis. *World journal of gastroenterology: WJG*. 2007;13:5612. <https://doi.org/10.3748/wjg.v13.i42.5612>
- [38] Lan L. Study on effect of *Cordyceps sinensis* and artemisinin in preventing recurrence of lupus nephritis. *Chinese Journal of Integrated Traditional and Western Medicine*. 2002;8:89-. <https://doi.org/10.1007/BF02934427>
- [39] Dong Y, Li W, Tu Y. Effect of dihydro-qinghaosu on auto-antibody production, TNF alpha secretion and pathologic change of lupus nephritis in BXS mice. *Zhongguo Zhong xi yi jie he za zhi Zhongguo Zhongxiyi jiehe zazhi= Chinese journal of integrated traditional and Western medicine*. 2003;23:676-9.
- [40] Li W-d, Dong Y-j, Tu Y-y, Lin Z-b. Dihydroartemisinin ameliorates lupus symptom of BXS mice by inhibiting production of TNF-alpha and blocking the signaling pathway NF-kappa B translocation. *International immunopharmacology*. 2006;6:1243-50. <https://doi.org/10.1016/j.intimp.2006.03.004>
- [41] Ho WE, Peh HY, Chan TK, Wong WF. Artemisinins: pharmacological actions beyond anti-malarial. *Pharmacology & therapeutics*. 2014;142:126-39. <https://doi.org/10.1016/j.pharmthera.2013.12.001>
- [42] Li H, Wang W, Tao Y, Qu G, Xing Y, Li Y, et al. Dihydroartemisinin-praziquantel combinations and multiple doses of dihydroartemisinin in the treatment of *Schistosoma japonicum* in experimentally infected mice. 2011;105:329-33. <https://doi.org/10.1179/136485911X13018982159979>

- [43] El-Beshbishi SN, Taman A, El-Malky M, Azab MS, El-Hawary AK, El-Tantawy DAJEp. In vivo effect of single oral dose of artemether against early juvenile stages of *Schistosoma mansoni* Egyptian strain. 2013;135:240-5. <https://doi.org/10.1016/j.exppara.2013.07.006>
- [44] Abou Rayia DM, Saad AE, Ashour DS, Oreiby RMJPI. Implication of artemisinin nematocidal activity on experimental trichinellosis: in vitro and in vivo studies. 2017;66:56-63. <https://doi.org/10.1016/j.parint.2016.11.012>
- [45] El-Shaieb A. Experimental pathologic studies on *Fasciola gigantica* and *Trichinella spiralis* in guinea pigs. 1995.
- [46] Shalaby MA, Moghazy FM, Shalaby HA, Nasr SMJPr. Effect of methanolic extract of *Balanites aegyptiaca* fruits on enteral and parenteral stages of *Trichinella spiralis* in rats. 2010;107:17-25. <https://doi.org/10.1007/s00436-010-1827-9>
- [47] Basyoni MM, El-Sabaa A-AAJTKjop. Therapeutic potential of myrrh and ivermectin against experimental *Trichinella spiralis* infection in mice. 2013;51:297. <https://doi.org/10.3347/kjp.2013.51.3.297>
- [48] Xu F, Hou B, Zhu X, Liu Y, Shi X, Li S, et al. Vaccaria n-butanol extract lower the production of proinflammatory cytokines and the infection risk of *T. spiralis* in vivo. 2019;64:520-7. <https://doi.org/10.2478/s11686-019-00064-6>
- [49] Young DS. Effects of drugs on clinical laboratory tests: AACC press; 2000.
- [50] Zimmerman HJ, Henry JBJCd, methods mbl. Clinical enzymology. 1979;16:365-8.
- [51] Bais R, Philcox M. Approved recommendation on IFCC methods for the measurement of catalytic concentration of enzymes. Part 8. IFCC Method for Lactate Dehydrogenase (L-Lactate: NAD⁺ Oxidoreductase, EC 1.1. 1.27). International Federation of Clinical Chemistry (IFCC). European journal of clinical chemistry and clinical biochemistry: journal of the Forum of European Clinical Chemistry Societies 1994. p. 639-55. <https://doi.org/10.1155/S1463924694000210>
- [52] Field J, Le Fleming HJTotRSotM, Hygiene. The Morphology of Malarial Parasites in Thick Blood Films. Part II. *Plasmodium falciparum*. 1940;33:507-20. [https://doi.org/10.1016/S0035-9203\(40\)90033-5](https://doi.org/10.1016/S0035-9203(40)90033-5)
- [53] Gulati G, Song J, Florea AD, Gong JJAolm. Purpose and criteria for blood smear scan, blood smear examination, and blood smear review. 2013;33:1-7. <https://doi.org/10.3343/alm.2013.33.1.1>
- [54] Slaoui M, Fiette L. Histopathology procedures: from tissue sampling to histopathological evaluation. Drug safety evaluation: Springer; 2011. p. 69-82. https://doi.org/10.1007/978-1-60761-849-2_4
- [55] Bancroft J, Stevens AJT, Practice of Histopathological Techniques. 2nd ed. CL, Edinburgh, UK. p. 134. 1982.
- [56] Toothaker LE, Newman DJJoES. Nonparametric competitors to the two-way ANOVA. 1994;19:237-73. <https://doi.org/10.3102/10769986019003237>
- [57] Sotiraki S, Athanasiou L, Himonas C, Kontos V, Kyriopoulos IJP. Trichinellosis in Greece: a review. 2001;8:S83-S5. <https://doi.org/10.1051/parasite/200108s2083>
- [58] Yadav A, Temjenmongla AJATsimmP. Antihelmintic Activity of *Gynura angulosa* DC. 2006;2:299-306.
- [59] Tagboto S, Townson S. Antiparasitic properties of medicinal plants and other naturally occurring products. 2001. [https://doi.org/10.1016/S0065-308X\(01\)50032-9](https://doi.org/10.1016/S0065-308X(01)50032-9)
- [60] Caner A, Döşkaya M, Değirmenci A, Can H, Baykan Ş, Üner A, et al. Comparison of the effects of *Artemisia vulgaris* and *Artemisia absinthium* growing in western Anatolia against trichinellosis (*Trichinella spiralis*) in rats. 2008;119:173-9. <https://doi.org/10.1016/j.exppara.2008.01.012>
- [61] Allam AF, Mostafa RA, Lotfy W, Farag HF, Fathi N, Moneer EA, et al. Therapeutic efficacy of mebendazole and artemisinin in different phases of trichinellosis: a comparative experimental study. 2021;148:630-5. <https://doi.org/10.1017/S0031182021000056>
- [62] Othman AA, Abou Rayia DM, Ashour DS, Saied EM, Zineldeen DH, El-Ebiary AAJPI. Atorvastatin and metformin administration modulates experimental *Trichinella spiralis* infection. 2016;65:105-12. <https://doi.org/10.1016/j.parint.2015.11.001>
- [63] Elgendy DI, Othman AA, Hasby Saad MA, Soliman NA, Mwafy SE. Resveratrol reduces oxidative damage and inflammation in mice infected with *Trichinella spiralis*. Journal of helminthology. 2020;94:e140. <https://doi.org/10.1017/S0022149X20000206>
- [64] Huang H, Yao J, Liu K, Yang W, Wang G, Shi C, et al. Sanguinarine has anthelmintic activity against the enteral and parenteral phases of trichinella infection in experimentally infected mice. Acta tropica. 2020;201:105226. <https://doi.org/10.1016/j.actatropica.2019.105226>
- [65] Ho WE, Cheng C, Peh HY, Xu F, Tannenbaum SR, Ong CN, et al. Antimalarial drug artesunate ameliorates oxidative lung damage in experimental allergic asthma. 2012;53:498-507. <https://doi.org/10.1016/j.freeradbiomed.2012.05.021>
- [66] Cheng C, Ho WE, Goh FY, Guan SP, Kong LR, Lai W-Q, et al. Antimalarial drug artesunate attenuates experimental allergic asthma via inhibition of the phosphoinositide 3-kinase/Akt pathway. 2011;6:e20932. <https://doi.org/10.1371/journal.pone.0020932>
- [67] Hou LF, He SJ, Li X, Yang Y, He PL, Zhou Y, et al. Oral administration of artemisinin analog SM934 ameliorates lupus syndromes in MRL/lpr mice by inhibiting Th1 and Th17 cell responses. 2011;63:2445-55. <https://doi.org/10.1002/art.30392>
- [68] Finkelman FD, Shea-Donohue T, Morris SC, Gildea L, Strait R, Madden KB, et al. Interleukin-4-and interleukin-13-mediated host protection against intestinal nematode parasites. 2004;201:139-55. <https://doi.org/10.1111/j.0105-2896.2004.00192.x>
- [69] Saeed ME, Krishna S, Greten HJ, Kreamsner PG, Efferth TJPr. Antischistosomal activity of artemisinin derivatives in vivo and in patients. 2016;110:216-26. <https://doi.org/10.1016/j.phrs.2016.02.017>
- [70] Araújo N, Kohn A, Katz NJMdlOC. Activity of the artemether in experimental schistosomiasis mansoni. 1991;86:185-8. <https://doi.org/10.1590/S0074-02761991000600042>
- [71] Yin J, Yang Y-Q, Xiao S, Li Y, Jiang H-JZylxbAPS. Comparative studies on histological and histochemical alterations of *Schistosoma japonicum* induced by arteether and artemether. 1991;12:478-80.
- [72] Zhai Z, Zhang Y, Liu H, Feng T, Xiao SJZjxcyjsbczzCjop, diseases p. Effect of artemether on enzymes involved in carbohydrate metabolism of *Schistosoma japonicum*. 2000;18:162-4.
- [73] O'Neill PM, Barton VE, Ward SA. The molecular mechanism of action of artemisinin--the debate continues. Molecules (Basel, Switzerland). 2010;15:1705-21. <https://doi.org/10.3390/molecules15031705>
- [74] Souza JG, Lopes Torres EJ, Garcia JS, Gomes AP, Rodrigues-Silva R, Maldonado A, Jr., et al. Light and scanning electron microscopy study of in vitro effects of artesunate in newly excysted metacercariae of *Echinostoma paraensei* (Trematoda: Digenea). Experimental parasitology. 2017;174:10-6. <https://doi.org/10.1016/j.exppara.2017.01.003>

- [75] Salama M, Mostafa N, El-Aal N, Moawad H, Hammad S, Adel R, et al. Efficacy of *Zingiber officinale* and *Cinnamomum zeylanicum* extracts against experimental *Trichinella spiralis* infection. *Journal of Parasitic Diseases*. 2021. <https://doi.org/10.21203/rs.3.rs-187770/v1>
- [76] Gabryel P, Gustowska L, Blotna-Filipiak MJBAM. The unique and specific transformation of muscle cell infected with *Trichinella spiralis*. 1995;5:231-8.
- [77] Kocięcka WJVp. Trichinellosis: human disease, diagnosis and treatment. 2000;93:365-83. [https://doi.org/10.1016/S0304-4017\(00\)00352-6](https://doi.org/10.1016/S0304-4017(00)00352-6)
- [78] Blotna-Filipiak M, Gabryel P, Gustowska L, Kucharska E, Wranicz MJPR. *Trichinella spiralis*: induction of the basophilic transformation of muscle cells by synchronous newborn larvae II. Electron microscopy study. 1998;84:823-7. <https://doi.org/10.1007/s004360050494>
- [79] Matsuo A, Wu Z, Nagano I, Takahashi YJP. Five types of nuclei present in the capsule of *Trichinella spiralis*. 2000;121:203-10. <https://doi.org/10.1017/S0031182099006198>
- [80] Derda M, Hadaś E, Cholewiński M, Skrzypczak Ł, Grzondziel A, Wojtkowiak-Giera AJPR. *Artemisia annua* L. as a plant with potential use in the treatment of acanthamoebiasis. 2016;115:1635-9. <https://doi.org/10.1007/s00436-016-4902-z>
- [81] Kołodziej-Sobocińska MJWp. Influence of free radicals on *Trichinella spiralis* infection in mice. 2006;52:239-41. <https://doi.org/10.1016/j.exppara.2005.09.004>
- [82] Ashton M, Sy ND, Van Huong N, Gordi T, Hai TN, Huong DX, et al. Artemisinin kinetics and dynamics during oral and rectal treatment of uncomplicated malaria. 1998;63:482-93. [https://doi.org/10.1016/S0009-9236\(98\)90044-3](https://doi.org/10.1016/S0009-9236(98)90044-3)
- [83] Sohn W-M, Kim H-M, Chung D-I, Yee STJKJoP. The first human case of *Trichinella spiralis* infection in Korea. 2000;38:111. <https://doi.org/10.3347/kjp.2000.38.2.111>
- [84] Bruschi F, Dupouy-Camet J, Kocięcka W, Pozio E, Bolas-Fernandez FJEoop. Opinion on the diagnosis and treatment of human trichinellosis. 2002;3:1117-30. <https://doi.org/10.1517/14656566.3.8.1117>
- [85] Long SS, Pickering LK, Prober CG. Principles and practice of pediatric infectious diseases. LWW; 2003. <https://doi.org/10.1097/00024382-200307000-00020>
- [86] Ashour DS, Elbakary RHJEp. Pathogenesis of restricted movements in trichinellosis: an experimental study. 2011;128:414-8. <https://doi.org/10.1016/j.exppara.2011.05.020>
- [87] Okafor UE, Helen AC, Nwankwo ODJAJoB. Haematological and Histopathological Effects of Artemisinin-Based Combination Therapy in Healthy Mice. 2020;29-37. <https://doi.org/10.9734/ajob/2020/v10i130097>
- [88] Soule C, Dupouy-Camet J, Georges P, Ancelle T, Gillet J, Vaissaire J, et al. Experimental trichinellosis in horses: biological and parasitological evaluation. 1989;31:19-36. [https://doi.org/10.1016/0304-4017\(89\)90005-8](https://doi.org/10.1016/0304-4017(89)90005-8)
- [89] Koudela B, Schanzel HJAVB. Activity of lactate dehydrogenase in the course of experimental trichinellosis in guinea pigs. 1980;49:85-9. <https://doi.org/10.2754/avb198049010085>