

# Case Report: A patient with severe peritonitis

J C Samuel<sup>1\*</sup>, E K Ludzu<sup>2</sup>, B A Cairns<sup>1</sup>,

C Varela<sup>2</sup>, and A G Charles<sup>1</sup>

<sup>1</sup> Department of Surgery, University of North Carolina, Chapel Hill NC USA

<sup>2</sup> Department of Surgery, Kamuzu Central Hospital, Lilongwe Malawi

Corresponding author: jcsamuel@med.unc.edu 4011 Burnett Womack Bldg CB 7228, Chapel Hill NC 27599

*What is the likely diagnosis?*

*What may explain the small white nodules on the transverse mesocolon?*

## Presentation of the case

A 42 year-old male presented to Kamuzu Central Hospital for evaluation of worsening abdominal pain, nausea and vomiting starting 3 days prior to presentation. On admission, his history was remarkable for four similar prior episodes over the previous five years that lasted between 3 and 5 days. He denied any constipation, obstipation or associated hematemesis, fevers, chills or urinary symptoms. During the first episode five years ago, he was evaluated at an outlying health centre and diagnosed with peptic ulcer disease and was managed with omeprazole intermittently. His past medical and surgical history was non contributory and he had no allergies and he denied alcohol intake or tobacco use. His HIV serostatus was negative approximately one year prior to presentation.

On examination he was afebrile, with a heart rate of 120 beats/min, blood pressure 135/78 mmHg and respiratory rate of 22/min. Abdominal examination revealed mild distension with generalized guarding and marked rebound tenderness in the epigastrium. There were no palpable masses and bowel sounds were absent. Full blood count and serum chemistry was unavailable. Erect and supine abdominal and chest radiographs were normal however, abdominal ultrasonography revealed free fluid throughout the abdomen and pelvis.

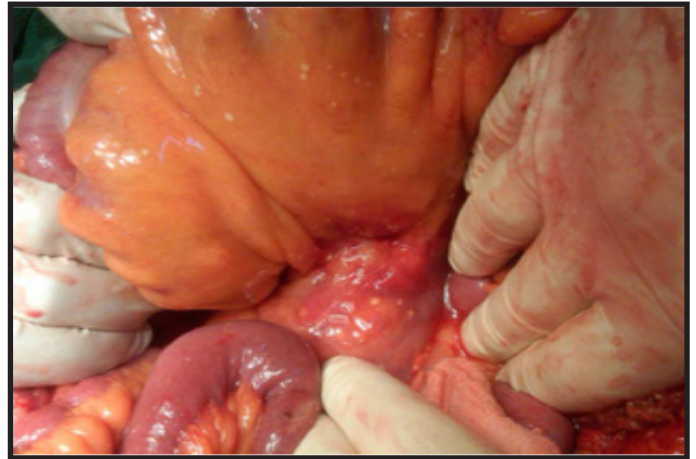Based on his vital signs and physical examination, he was resuscitated with intravenous fluids and taken urgently to theatre for an exploratory laparotomy with a provisional diagnosis of a perforated peptic ulcer and differential diagnoses of ruptured appendicitis, midgut volvulus, pancreatitis and typhoid perforation. The peritoneum was accessed via a vertical midline incision. Upon entering the peritoneal cavity, approximately 2 litres of clear reddish brown fluid was encountered and evacuated. The anterior stomach, duodenum, gallbladder, liver, small bowel, colon and appendix were normal.

Palpation through the stomach and transverse mesocolon noted a firm midline mass-like structure.

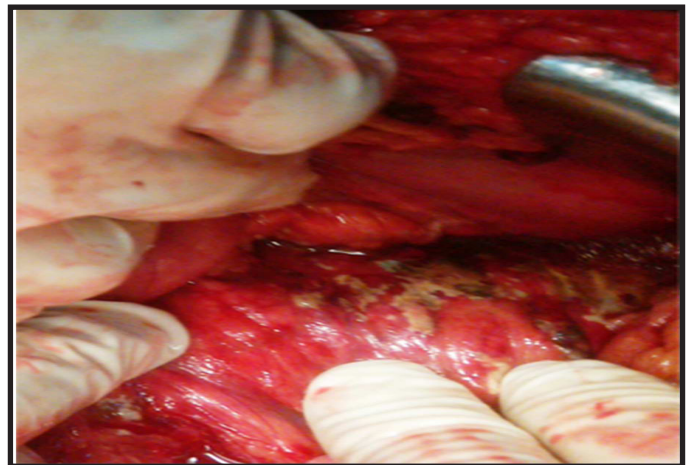
There were no obvious gallstones on palpation. There were multiple sub-centimetre white nodules on the transverse mesocolon (Figure 1A).

As the source of his pathology was not yet diagnosed, the lesser sac was entered between the transverse colon and stomach to evaluate for posterior gastric or pancreatic pathology. There was significant inflammation between the stomach, transverse mesocolon and pancreas making this exposure challenging. However upon releasing the scarred inflamed tissue planes the likely diagnosis became clear (Figure 1B).

*Figure 1. Intraoperative photograph showing the transverse mesocolon (1a) and the pancreas (1b).*



*(Fig 1B)*



## Discussion of the case

The appearances are those of acute pancreatitis. The small white nodules on the transverse mesocolon are likely to be areas of fat necrosis, which complicates this syndrome. A differential or additional diagnosis to consider in this case is tuberculous peritonitis.

A large drain (24 french) was inserted through the right mid abdomen overlying the pancreas and placed to gravity drainage. Biopsies of both the whitish nodules and the inflamed pancreatic tissue were obtained for tuberculosis testing which was negative by acidfast bacillus smear and nucleic acid amplification<sup>1,2</sup>. After irrigation, the abdomen was closed and he was transferred to the surgical high dependency unit and managed with a regimen of nil per os, intravenous fluids, nasogastric decompression and intravenous antibiotics (ceftriaxone and metronidazole). He recovered uneventfully and was discharged on post op day

#5 with a 10 day course day of oral antibiotics (cephalexin and metronidazole) and instructions to empty and record his drain output daily. He was also asked to obtain a fasting lipid profile including triglycerides. He returned one week later for review with a normal lipid profile. His drain initially put out 100mL per day of serosanguinous fluid but the output tapered down to 5mL per day of serous yellow fluid for two days prior and was hence removed. He denied any fevers, chills, nausea, vomiting or abdominal pain.

His abdominal skin sutures were removed. He finished his course of antibiotics and remained asymptomatic. He was counseled to take smaller more frequent meals, stay hydrated, and return to the hospital should his symptoms return. He was also counseled that if he developed early satiety or abdominal pain he may require a CT scan to evaluate for a pancreatic pseudocyst and endoscopic retrograde cholangiopancreatography (ERCP).

Pancreatitis is an inflammation of the pancreas that can be acute or chronic. Typical findings include nausea, vomiting and abdominal pain that often radiates to the back<sup>3</sup>. The most common etiologies in developed countries are alcohol consumption, gallstones and idiopathic<sup>4</sup>. Other etiologies include auto-immune, anatomic (pancreas divisum) and drug-induced. In Malawi gallstones are rare and more common etiologies include alcohol consumption and medications (such as isoniazid and stavudine)<sup>5,6</sup>. A distinct entity, tropical pancreatitis, is seen among young individuals during prolonged periods of decreased food intake particularly in warm climates<sup>7</sup>. Acute pancreatitis can be recurrent as in this case. An occasional treatable cause of recurrent pancreatitis is hydatid disease in the liver (cysts can be discharged into the biliary system and hence into the pancreatic duct). It is therefore wise to obtain an ultrasound scan of the liver in a patient like this, to look for hydatid cyst/s. Typically chronic pancreatitis is more indolent course that occurs after multiple attacks of acute pancreatitis, and often leads to pancreatic insufficiency.

Necrotizing pancreatitis is a severe form of acute pancreatitis that results from tissue ischemia and necrosis, often leads to serious infections and has a high mortality (up to 25%)<sup>8</sup>.

This case is a typical presentation of recurrent acute pancreatitis with a severe attack leading to pancreatic necrosis. The diagnosis of pancreatitis is confirmed by an elevated lipase (greater than three times normal)<sup>9</sup>. In the acute setting, a computed tomography scan will often assist in evaluating for pancreatic necrosis by revealing nonperfused pancreatic tissue and peri-pancreatic gas. Necrotizing pancreatitis requires intervention either with percutaneous drainage (often by ultrasound or computed tomography guidance) or surgery if there is evidence of peripancreatic gas or infection. When available percutaneous intervention is preferred as an initial step<sup>10</sup>. However at KCH this is not available therefore the treatment was surgical with irrigation of the abdomen, debridement and drainage.

Complications of acute pancreatitis, aside from necrotizing pancreatitis, include pancreatic pseudocysts and pancreatic insufficiency. Small pancreatic pseudocysts will often resolve with supportive care. However larger pseudocysts often result in continued abdominal pain, early satiety and/or gastric outlet obstruction and require interventions such as endoscopic cyst-gastrostomy or surgical treatment such as cyst-jejunostomy or open cyst-gastrostomy<sup>11</sup>.

In conclusion pancreatitis ranges from mild acute attacks

to fulminate pancreatic necrosis. Prompt diagnosis and appropriate treatment is necessary to achieve better outcomes for these patients. This case provides an example and brief overview of the topic, which should help guide clinicians caring for these patients.

## Acknowledgements

We thank the College of Surgeons of East, Central, and Southern Africa, the Malawi College of Medicine and the Department of Surgery at Queen Elizabeth Central Hospital for technical support and advice regarding development of the General Surgery training programme at Kamuzu Central Hospital.

We also thank Johnson and Johnson, the NC Jaycee Burn Center and the University of North Carolina Department of Surgery for supporting the partnership between the University of North Carolina and Kamuzu Central Hospital Departments of Surgery, and UNC Project for administrative support and providing the Tuberculosis testing.

This work was supported by the Fogarty International Center of the National Institutes of Health under Award Number K01TW009486. The content is solely the responsibility of the authors and does not necessarily represent the official views of the National Institutes of Health.

## References

1. Marlowe EM, Novak-Weekley SM, Cumpio J, Sharp SE, Momeny MA, Babst A, et al. Evaluation of the Cepheid Xpert MTB/RIF assay for direct detection of Mycobacterium tuberculosis complex in respiratory specimens. *J Clin Microbiol*. 2011 Apr;49(4):1621-3.
2. Yajko DM, Nassos PS, Sanders CA, Madej JJ, Hadley WK. High predictive value of the acid-fast smear for Mycobacterium tuberculosis despite the high prevalence of Mycobacterium avium complex in respiratory specimens. *Clin Infect Dis*. 1994 Aug;19(2):334-6.
3. Bradley EL, 3rd. A clinically based classification system for acute pancreatitis. Summary of the International Symposium on Acute Pancreatitis, Atlanta, Ga, September 11 through 13, 1992. *Arch Surg*. 1993 May;128(5):586-90.
4. Wang GJ, Gao CF, Wei D, Wang C, Ding SQ. Acute pancreatitis: etiology and common pathogenesis. *World J Gastroenterol*. 2009 Mar 28;15(12):1427-30.
5. Pandey AS, Surana A. Isoniazid-induced recurrent acute pancreatitis. *Trop Doct*. 2011 Oct;41(4):249-50.
6. van Oosterhout JJ, Mallewa J, Kaunda S, Chagoma N, Njalale Y, Kampira E, et al. Stavudinotoxicity in adult longer-term ART patients in Blantyre, Malawi. *PLoS One*. 2012;7(7):e42029.
7. Nwokolo C, Oli J. Pathogenesis of juvenile tropical pancreatitis syndrome. *Lancet*. 1980 Mar 1;1(8166):456-9.
8. Buchler MW, Gloor B, Muller CA, Friess H, Seiler CA, Uhl W. Acute necrotizing pancreatitis: treatment strategy according to the status of infection. *Ann Surg*. 2000 Nov;232(5):619-26.
9. Gumaste VV, Roditis N, Mehta D, Dave PB. Serum lipase levels in nonpancreatic abdominal pain versus acute pancreatitis. *Am J Gastroenterol*. 1993 Dec;88(12):2051-5.
10. Besselink MG, van Santvoort HC, Nieuwenhuijs VB, Boermeester MA, Bollen TL, Buskens E, et al. Minimally invasive 'step-up approach' versus maximal necrosectomy in patients with acute necrotising pancreatitis (PANTER trial): design and rationale of a randomised controlled multicenter trial [ISRCTN13975868]. *BMC Surg*. 2006;6:6.
11. Lerch MM, Stier A, Wahnschaffe U, Mayerle J. Pancreatic pseudocysts: observation, endoscopic drainage, or resection? *Dtsch Arztebl Int*. 2009 Sep;106(38):614-21.