

Teaching Corner: Regional anaesthesia for ophthalmic surgery

R.Tighe¹, P. I. Burgess², G. Msukwa

1. CURE International Hospital
2. Malawi-Liverpool-Wellcome Trust Clinical Research Programme
3. Lions First Sight Eye Unit, Queen Elizabeth Central Hospital, Blantyre, Malawi

Abstract

Performing safe and effective regional anaesthesia for ophthalmic surgery is an important skill for anaesthetic and ophthalmologic practitioners. Akinetic sharp-needle blocks are generally safe but rare, sight and life threatening complications occur. Sub-Tenon's block using a blunt canula provides akinesia and is a safer alternative but serious complications have been reported. This review provides an introduction to the relevant anatomy, local anaesthetic drugs and commonly used techniques and a practical guide to their safe performance.

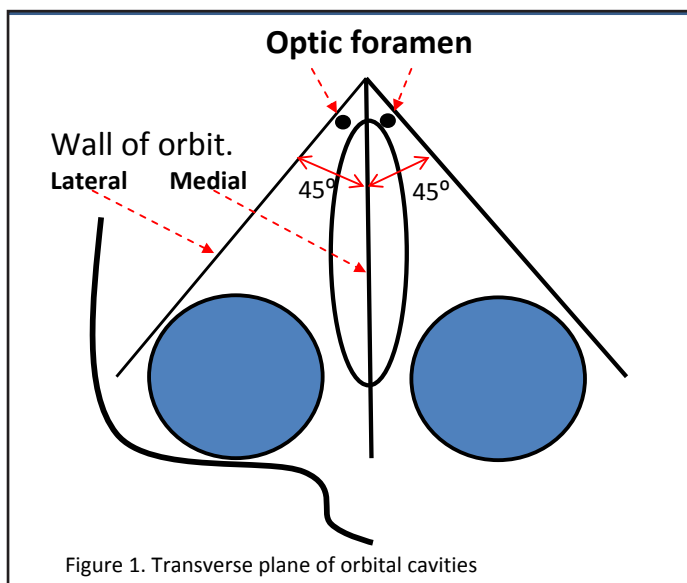
Introduction

The majority of ophthalmic surgical procedures in adults are performed under local anaesthesia. Children normally require general anaesthetic due to lack of cooperation for local anaesthetic blocks and unable to tolerate procedures awake.

Optimal surgical conditions (analgesia and akinesia) can be obtained with block techniques avoiding the risks of general anaesthesia for a population of patients who are often elderly with concurrent co-morbidities. These techniques also benefit a resource poor environment, with limitations to anaesthetic personnel and equipment, hospital beds, recovery staff and overall allow a quicker turnover of patients at less cost. This article will describe the anatomy of the eye, the local anaesthetic drugs used and the techniques in current use.

Anatomy

The orbit is shaped like a bony pyramid with the apex posterior measuring 42-54mm to the base (cornea and lids). Figure 1 shows the alignment of the medial and lateral orbital walls relative to the sagittal plane.



The globe measures approximately 24mm from cornea to retinal surface (the 'axial length') and lies in front half of orbit.

There are 3 entrances to the orbital cavity at the apex of the pyramid.

The optic canal contains the optic nerve and the ophthalmic artery.

The superior orbital fissure contains cranial nerves III (oculomotor), IV (trochlear), V1 (trigeminal, ophthalmic branch), VI (abducens), and the superior ophthalmic vein. The inferior orbital fissure permits the V2 (trigeminal, infraorbital nerve from maxillary branch) and the inferior ophthalmic vein. Figure 2 illustrates the position of structures entering the orbit. Figure 3 shows the position of important structures at 3 cross sections in the orbit.

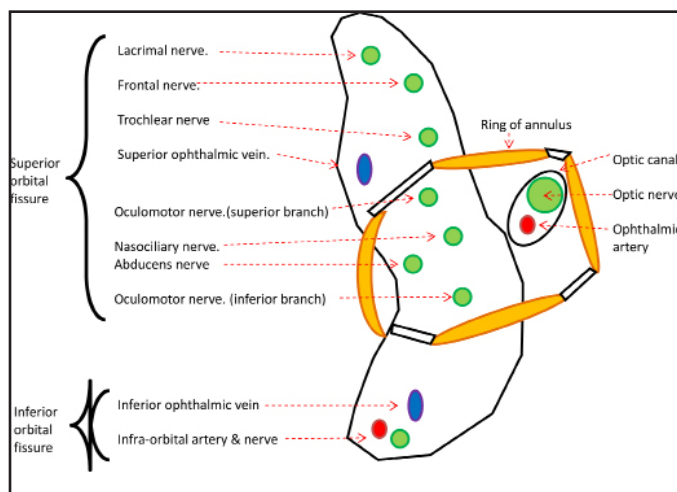


Figure 2. Structures entering the apex of orbital cavity.

EXTRA-OCULAR MUSCLES

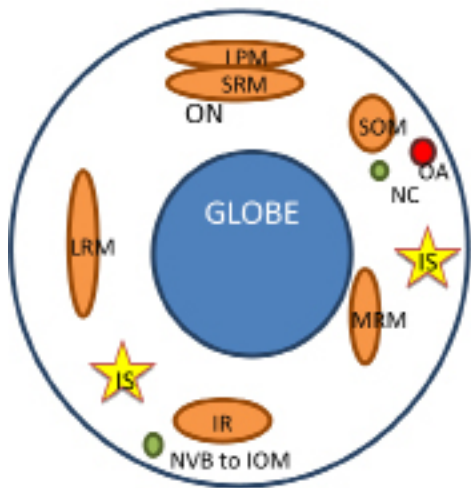
There are six extra-ocular muscles that control orbit movement (4 recti and 2 oblique).

The four recti muscles insert into the globe, extending anteriorly in the orbit, originating from the annulus of Zinn, that encircles the optic canal, superior and inferior orbital fissures (this forms the 'cone'). In the cone, and between the muscles lies fatty connective tissue that supports the structures and through which this nerves and vessels run.

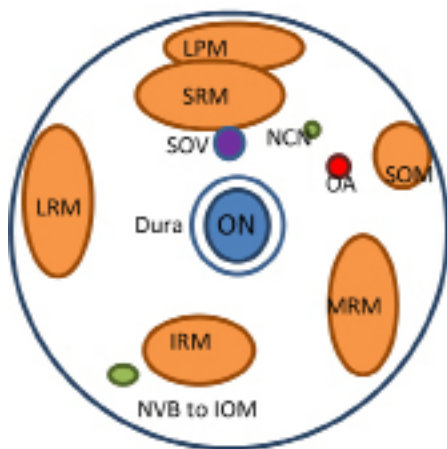
The medial rectus diverts from the medial wall which permits a larger fat-filled space between the muscle and the medial orbital wall. There are no anatomically important structures in this cavity providing a good area for infiltration.

The superior oblique originates from just above the annulus of Zinn, tracks forward to its pulley at supero-nasal corner of orbit before doubling back to insert on superior posterior globe.

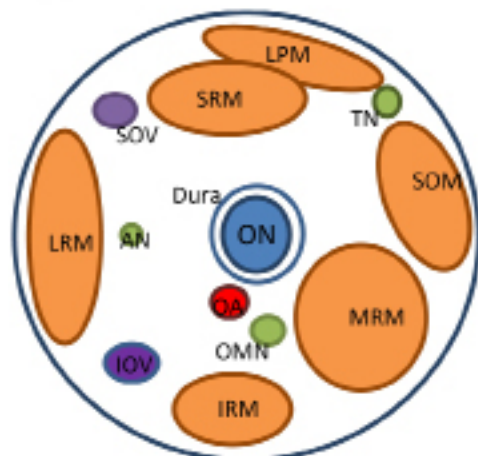
The inferior oblique originates from maxilla, lateral to lacrimal groove and runs posterolaterally between inferior rectus and globe to its insertion onto sclera adjacent to lateral rectus.



1.



2.



3.

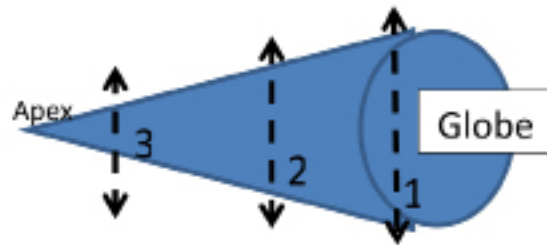


Figure 3 (Important structures highlighted)

Cross sections of orbit

1. posterior globe
2. 5mm behind globe
3. 20mm behind globe

LPM – levator palpebrae muscle

SRM – Superior rectus muscle

SOM – Superior oblique muscle

MRM – Medial rectus muscle

LRM – Lateral rectus muscle

IRM – Inferior rectus muscle

NVB – neurovascular bundle

IOM – inferior oblique muscle

NCN - Nasociliary nerve

OA – ophthalmic artery

ON – Optic nerve (CN II)

SOV – superior ophthalmic vein

IOV – inferior ophthalmic vein

OMN – Oculomotor nerve (CN III)

TN – trochlear nerve (CN IV)

AN – Abducens nerve (CN VI)

IS - Injection sites

Nerve Supply

Motor - Cranial nerve III supplies all muscles that control globe movement except for superior oblique (Cranial nerve IV – trochlear - which runs outside the annulus along muscle surface, therefore often remains unaffected by infero-temporal blocks) and lateral rectus (cranial nerve VI - abducens).

Sensory – Major contributions are from Cranial nerve V1 whose divisions are frontal, lacrimal and nasociliary nerves. There are minor contributions only from CN V2 from infra-orbital nerve.

Blood supply

The ophthalmic artery enters the orbit in the optic canal and supplies the extra-ocular muscles and the globe, the distribution is skewed to the superior nasal quadrant, therefore this area should not be used for local anaesthetic filtration.

Connective tissue

Tenon's capsule is a thin membrane that forms a socket for the globe, separating it from the orbital fat. The episcleral

space ('sub-Tenon's') is between Tenon's capsule and the sclera which ends anteriorly by their fusion, 3-5mm posterior to the junction of the cornea and sclera. Posteriorly this thin membrane is not consistent around the fusion of optic nerve and globe (which allows spread of local anaesthetic injected into this potential space to flow to the posterior orbit).

Approaches for regional anaesthesia

Anatomical considerations dictate that infero-temporal and medial approaches are safest for sharp needle anaesthesia (Figure 3). In these areas there is less risk of damage to local structures including vessels, muscles and nerves.

Local anaesthetic drugs

Local anaesthetics (LAs), which are weak bases, act by crossing the nerve membrane as unionised molecules, becoming ionised intracellularly and binding to intracellular sodium channels thereby blocking propagation of the action potential. Lignocaine and bupivacaine are most commonly used for injection. Choice of agent is made depending on requirements for speed of onset (dependent on the pKa of the agent, describing the pH at which the unionised and ionised molecules are 50:50), duration of block (protein binding capacity) and desired potency (lipid solubility).

Table 1. Characteristics of two commonly used local anaesthetic agents

	Lignocaine	Bupivacaine
Onset of action	1 minute	15 minutes
Concentration for analgesia (C-fibres)	0.5 %	0.125-0.25%
Concentration for sensory/motor block (A α , β fibres)	1-2%	0.5-0.75%
Duration of action	30-45mins	2-6 hours
pKa	7.8	8.1
Maximum safe dose	3mg/kg	2mg/kg

Hyaluronidase is an enzyme that breaks down hyaluronic acid, part of the normal extracellular matrix. This is commonly added to aid spread and therefore reduce total dose required of the infiltrated local anaesthetic¹¹. It is used at a concentration of 15 i.u./ml of local anaesthetic and has minimal side effects.

Problems with regional eye blocks

As with general anaesthesia, any eye surgery can evoke the oculo-cardiac reflex. This is vagal overstimulation that can manifest with profound bradycardia and hypotension (especially in children). Atropine/glycopyrolate (anti-muscarinics) should be available during all ophthalmological procedures, and prophylactic pre-medication should be considered if previous reaction described by patient (NB atropine causes marked pupillary dilation, surgeon should be informed of administration).

Very rarely patients can have sensitivity /allergy to local anaesthetic agents (though this is more common with the ester group, as opposed to the amide group that lignocaine/bupivacaine belong to) or to the hyaluronidase used as an adjunct¹³.

Toxicity of local anaesthetic can be life threatening and occurs with intravascular injection or overdose. (Table 2)

Even at normal doses, if the local anaesthetic is injected into Optic nerve sheath (via retrobulbar injection technique), it can track, via the subarachnoid space to the brainstem - apnoea and loss of consciousness can occur ('brain stem anaesthesia'). Once recognised, infiltration must be stopped

and vital signs monitored/supported as required.

Any medical personnel using local anaesthetics should be aware of the manifestations of toxicity or subarachnoid spread, and be able to manage them. It is for this reason that it is advised that an anaesthetist be available when blocks are administered.

Table 2. Manifestations and treatment of local anaesthetic toxicity

	Central nervous system	Cardiovascular system
Mild	Talkativeness, metallic taste, excitability, dysarthria, tremor, twitching	Tachycardia, tachypnoea, hypertension
Severe	Tonic clonic seizures, decreased level of consciousness.	Hypotension, bradycardia, arrhythmias leading to cardiovascular collapse and arrest.
Treatment of severe reaction	Sedation (benzodiazepines) with airway protection +/- ventilation as required.	Volume expansion, vasopressors/ionotropes/antiarrhythmics +/- defibrillation/cardiopulmonary resuscitation if needed. Intralipid infusion (specialist use only) ¹²

Regional blocks

Regional anaesthesia is suitable for the majority of patients. There are some contra-indications (most are relative) which the practitioner should consider, and request support of an anaesthetist for consideration of general anaesthetic or other methods).

- Children,
 - Patient refusal,
 - Language barrier,
 - dementia,
 - GCS<14,
 - not-starved,
 - unable to lie flat and still,
 - ASA 3-4 (anaesthetic grading scale that identifies patients with chronic co-morbidities that affect their daily functioning, eg heart failure, COPD),
 - last eye,
 - previous oculo-cardiac reflex,
 - long operation planned,
 - difficult predicted airway (if problem arose mid-operation).
 - Bleeding disorders (antiplatelet drugs are not a contra-indication and although anti-coagulants have higher risk, consultation with physician should be sought before ceasing).
 - Localised infection
 - Long axial length need extra caution - >26mm and high myopes (greater incidence of staphylomas - out-pouchings of sclera therefore subject to trauma from needle).
- All regional blocks should be done with the following precautions as standard:
- patient monitored (BP/ECG/SATs),
 - iv access established
 - with trained assistance,
 - an anaesthetist available,
 - oxygen and suction,
 - anaesthetic machine and intubation equipment
 - emergency drugs (adrenalin, atropine, suxamethonium).

There are optimal sites for local anaesthetic infiltration that reduce risk of structure damage (globe/nerve/muscle insertion/vessels) and provide anaesthesia and akinesia. The

operation dictates which approach is ideal given the need for anaesthesia, paralysis of ocular movements and occasionally the necessity for paralysis of orbicularis oculi (CN VII – facial nerve).

The regional blocks can be performed via transconjunctival or percutaneous routes. Initial preparation of the conjunctiva with low dose local anaesthetic drops improves comfort for the patient. For sharp needle blocks the patient should be instructed to look straight ahead ('primary gaze' position). This protects the posterior optic nerve and ophthalmic artery from the needle.

Before any local anaesthetic is injected a negative aspiration must be demonstrated to prevent intravascular injection. Injection of LA should be slow to avoid the oculo-cardiac vagal reflex that can occur with increased intra-orbital pressure.

Signs of a successful block are inability to open the eye fully, inability to close the eye and inability to move the globe. If slight movement remains, top up should be considered according to remaining function (if down and lateral, use infero-temporal top-up, if up and medial use nasal approach).

RETROBULBAR (INTRACONAL)

This was the primary technique until 15 years ago when newer blocks (sub-Tenon's and now topical and intracameral anaesthesia - described later) have superseded the retrobulbar approach due to much safer side effect profile.

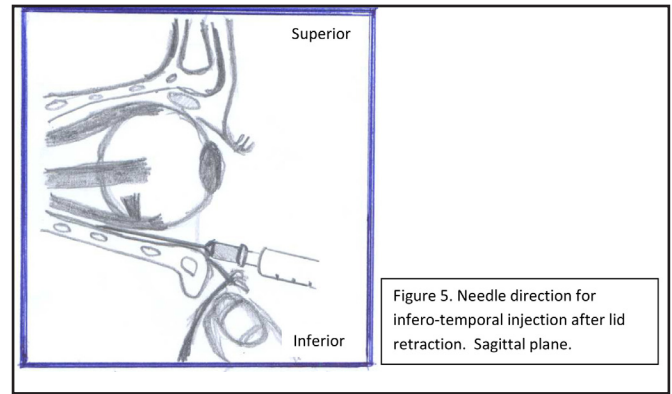
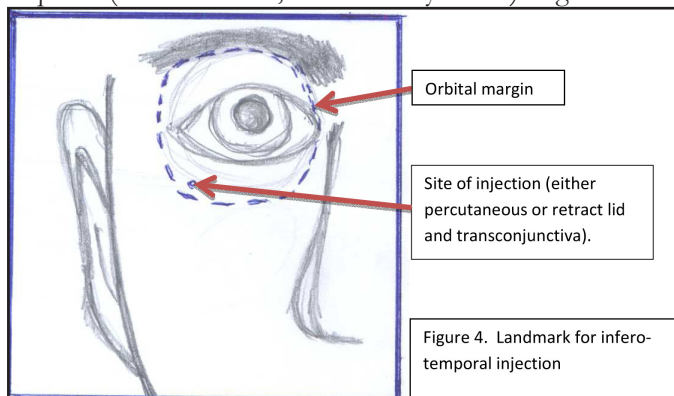
Indications:

Complete anaesthesia and akinesia required.

Patient or procedure unsuitable for less invasive block.

Technique:

- Establish baseline monitoring and venous access. Topical tetracaine to conjunctiva.
- Prepare skin and/or conjunctiva with povidone iodine.
- Find landmarks – lateral to the junction of the lateral third and middle third of inferior orbital rim. If using percutaneous route use finger pressure above the rim to push globe up and feel for gap between orbit and infraorbital bone, to improve tract for needle and reduce risk of globe perforation. If using transconjunctival route, use finger pressure to pull lower lid down (Fig 4 & 5).
- Introduce 25-27g needle, no longer than 31mm and avoid blunt or semi blunt needles due to increased risk of trauma. Insert needle under the globe. Once past it, aim inwards and upwards to reach space behind globe, aiming for the back of the occiput. Minimal amounts of local anaesthetic are required (as little as 2ml, but normally 3-5ml). Fig 5.



Complications:

Retro-bulbar block has relatively high risk of damage to local structures and systemic complications compared to peribulbar and sub-Tenon's blocks. Principle risks are:

- Subarachnoid spread of local anaesthetic, described in previous section (as the dura of the optic nerve can be breached by needle),
- Retrobulbar haemorrhage (this is a sight threatening complication and should be anticipated, recognised and treated promptly).
- Globe perforation (<0.1% normally, but 0.7% if axial length greater than 26mm).
- Diplopia.
- oculo-cardiac reflex.
- injury to medial wall.
- optic nerve compression and central artery closure due to raised intraorbital pressure from LA infiltration.

PERIBULBAR (EXTRACONAL)

Indications:

Relatively complete anaesthesia and akinesia required.

Procedure or patient unsuitable for sub-Tenon's block.

Technique:

- Establish baseline monitoring. Tetracaine to conjunctiva.
- Apply povidone iodine to similar to skin or conjunctiva according to approach.
- There are 2 main approaches (Figure 6) –
- Infero-temporal** (landmarks described as for retro-bulbar). This aims to block nasociliary, lacrimal, frontal, supraorbital and supra-trochlear (of CN V1) and infra-orbital (of CN V2) nerves. As this avoids aiming directly behind the globe it avoids the three principle risks of retro-bulbar blocks and conveniently blocks the orbicularis oculi as well. However a bigger volume of local anaesthetic is needed to reach desired nerves (6-8ml). (See Figure 5)

Medial peribulbar block (often supplementary to infero-temporal peribulbar block). This aims to block medial branches of nasociliary, supra trochlear and supraorbital nerves, the infra-trochlear and the long ciliary nerves. A safe injection site, due to the 4-10mm distance between globe equator and medial orbital wall and the fat pad (see diagram). A 27g needle, no longer than 22mm is pushed straight back through medial caruncle. It penetrates the medial canthal tendon and lacrimal sac (though no complications arise from

this). There is a subtle give in resistance to signify correct

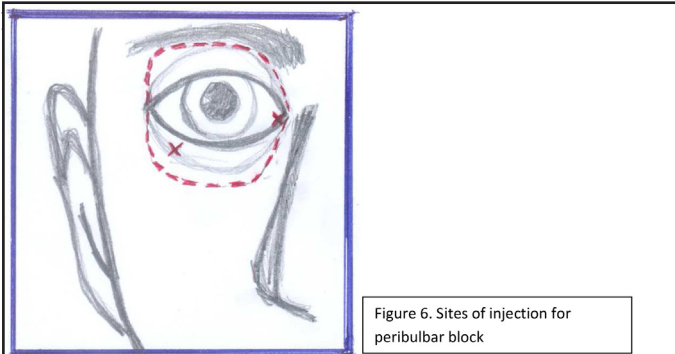


Figure 6. Sites of injection for peribulbar block

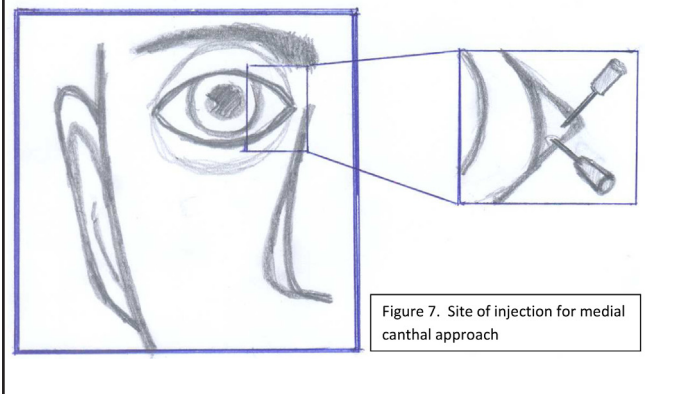


Figure 7. Site of injection for medial canthal approach

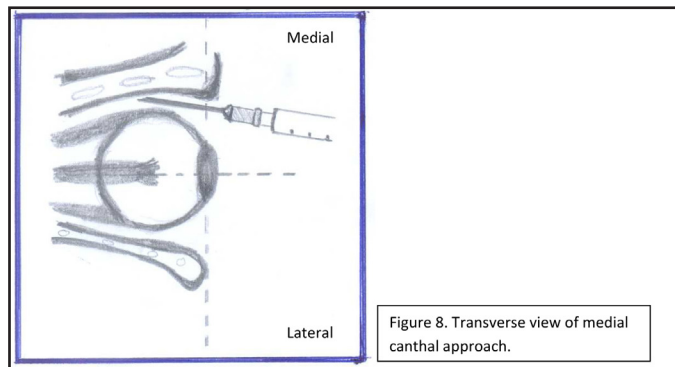


Figure 8. Transverse view of medial canthal approach.

Complications:

Recent studies indicate that the distinction between the two techniques is blurred. Computed tomography studies reveal multiple communications between intra-conal and extra-conal compartments allowing free diffusion of local anaesthetics⁶. Comparison of clinicians' descriptions and technique analysis shows a broad range between the two defined options⁷.

Therefore see retrobulbar block section for complications.

Due to increased volumes of local anaesthetic agents infiltrated with peribulbar blocks there is a risk of increased ocular pressure (can increase intraoperative complications). These are reduced by allowing a period of diffusion (10-15mins) before starting the operation, and/or use of decompression devices such as Honan's balloon (30-40mmHg for 5 minutes).

SUB-TENON'S BLOCK

Indications:

Sub-Tenon's block provides excellent anaesthesia and akinesia without requiring a sharp needle. Particularly

appropriate for patients at higher risk of complications from sharp needle blocks for example high myopes, patients with scleral explants and those taking anti-coagulants. Sub-Tenon's blocks are unsuitable for surgery requiring intact conjunctiva such as most glaucoma procedures.

Technique:

- Establish baseline monitoring. Tetracaine to conjunctiva.
- Sterilise field with iodine.
- The patient holds the eye in primary position or away from designated approach (up and out for inferonasal approach, which is preferred to inferotemporal as it avoids the inferior oblique muscle insertion – though studies have shown equal efficacy in inferotemporal approaches with no added complications⁸.
- The conjunctiva and Tenon's capsule are gripped 5-8mm from limbus with forceps and blunt dissection to sclera performed with blunt curved scissors. A blunt canula (19-gauge, 25mm, curved) is advanced through hole and abutting the globe, past the equator (loss of resistance felt as there are folds in the capsule at this point). Local anaesthetic is injected (3- 5ml). Sensory block occurs rapidly as all nerves to globe cross the sub-Tenon's space, with akinesia occurring later as the local anaesthetic diffuses posteriorly into the intraconal space (as the Tenon's capsule is incomplete posteriorly). Figure 9&10.

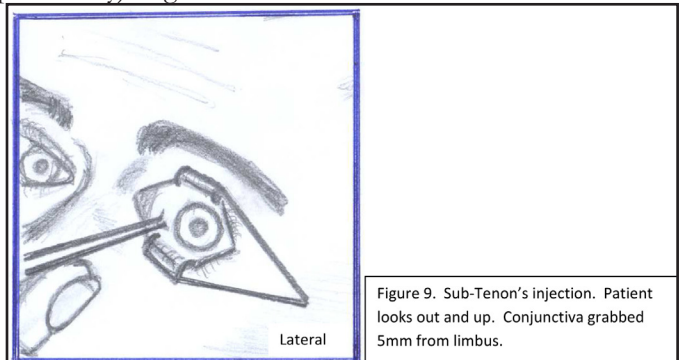


Figure 9. Sub-Tenon's injection. Patient looks out and up. Conjunctiva grabbed 5mm from limbus.

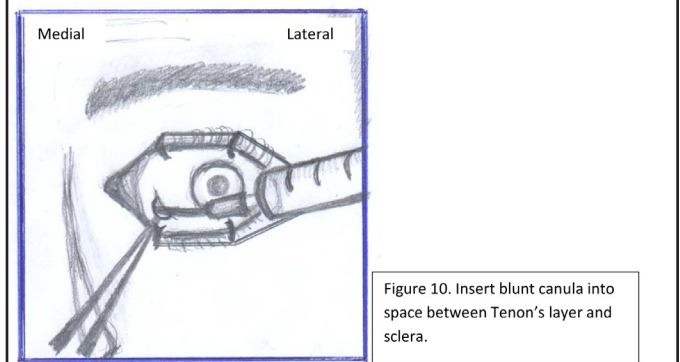


Figure 10. Insert blunt canula into space between Tenon's layer and sclera.

Complications

- Failure (due to back flow of LA).
- sub-conjunctival haemorrhage
- raised intra-orbital pressure.
- globe trauma (particularly if previous vitreo-retinal surgery,
- retrobulbar haemorrhage.
- Deep posterior dissection risks central spread of LA.

4. Topical anaesthesia

Topical agents such as tetracaine (known as amethocaine in UK) can be used for modern phacoemulsification cataract surgery. In this scenario it must be a routine operation with a cooperative patient and an experienced surgeon. The use of topical anaesthesia alone is not appropriate for extra-capsular cataract surgery or non-phacoemulsification small incision cataract surgeries, which are performed widely in developing countries as both require a trans-scleral incision.

Also intracameral infiltration (irrigation fluids containing local anaesthetic) is used intra-operatively during modern phacoemulsification cataract surgery by many ophthalmologists (as well as topical drops), meaning most cases are done without invasive block.

Risk factors predisposing to complications with sharp needle anaesthesia

- Long globe (> 26mm carries 1/140 risk of globe perforation)¹. Thus axial length must be documented before any blocks are performed.
- Enophthalmos and other structural abnormalities.
- Poor technique – practitioners should review orbital anatomy, current guidelines, and local anaesthetic pharmacology regularly.
- Uncooperative patient – good communications and consent are essential.
- Use of long needles (needles shorter than 31mm should be used to avoid major structures⁴ and in medial canthal area no more than 22mm).
- Inferior injections – need to be extreme infero-temporal corner of eye to avoid neurovascular bundle of inferior oblique and inferior rectus muscle.

Conclusions

Regional anaesthesia for ophthalmic surgery is highly effective. Both sharp needle and sub-Tenon's blocks provide anaesthesia and akinesia. The latter carries fewer risks and if a purely topical/intra-cameral route is not adequate then sub-Tenon's block is the technique of choice. No technique is entirely risk free. Knowledge of the relevant anatomy, characteristics of local anaesthetic agents and appropriate

training in block techniques will allow the practitioner to perform effective and safe orbital anaesthesia.

Competing interests

PB is funded by the Wellcome Trust via a Clinical PhD Fellowship. The authors have no relevant conflict of interest to disclose.

References

1. Duker JS, Belmont JB, Benson WE, Brooks HL, Brown GC, Federman JL et al. Inadvertent globe perforation during retrobulbar and peribulbar anaesthesia. Patient characteristics, surgical management and visual outcome. *Ophthalmology* 1991;98:510-26
2. Konstantatos A. Anticoagulation and cataract surgery: a review of the current literature. *Anaesth Intensive Care* 2001; 292: 11-8
3. Katz J, Petty BG et al. Study of Medical testing for cataract surgery team. Risks and benefits of anticoagulant and antiplatelet medication use before cataract surgery *Ophthalmology* 2003;110:1784-8
4. Katsev DA, Drews RC, Rose BT. An anatomical study of retrobulbar needle path length. *Ophthalmology*. 1989;98:1221-1224
5. Grizzard, W, Kirk NM, Pavan PR et al (1991). Perforating ocular injuries cause by anaesthesia personnel. *Ophthalmology*, 98, 1011-16
6. Ripart J, Lefrant JUY, Lalourcey L, et al. 1996;83:1234-1238
7. Thind GS, Rubin AP: Local anaesthesia for eye surgery: no room for complacency, *Br J Anaesth* 2001;86: 473-476
8. H McLure, S Ahmed et al. 2006 A comparison of infero-nasal and infero-temporal sub-Tenon's block. *European Journal of Anaesthesiology*; 23: 282-284
9. www.frca.co.uk Viewed 8-12/03/2012
10. Alexander JE Foss. *Essential Ophthalmic Surgery* 2001. Butterworth Heinemann Publishing. Chapter 2.
11. Schulenburg HE, Sri-Chandana C, Lyons G, Columb MO, McLure HA. Hyaluronidase reduces local anaesthetic volumes for sub-Tenon's anaesthesia. *Br J Anaesth*. 2007 Nov;99(5):717-20. Epub 2007 Sep 24.
12. http://www.aagbi.org/sites/default/files/la_toxicity_2010_0.pdf Viewed 8-12/3/2012
13. Escolano, F.1; Parés, N.1; Gonzalez, I.1; Castillo, J.1; Valero, A.2; Bartolomé, B. Allergic reaction to hyaluronidase in cataract surgery. *European Journal of Anaesthesiology*: September 2005 - Volume 22 - Issue 9 - p 729-730