

Case Report-The 46 year old man with a 5 month history of vomiting

Dalitso Segula^{1,2} Victoria Mwandambira³, Will Howson¹, Theresa J Allain¹

1. Department of Medicine, University of Malawi College of Medicine, Blantyre, Malawi

2. Malawi-Liverpool-Wellcome (MLW) Trust Clinical Research Programme, Blantyre, Malawi

3. Queen Elizabeth Central Hospital, Ministry of Health, Blantyre, Malawi

On the 23rd of January 2011, we admitted a 46-year-old man to Queen Elizabeth Central Hospital (QECH) with a 5-month history of recurrent vomiting. This was associated with nausea. He would vomit at least 5 times per day. The vomitus was non-projectile, would usually take the colour of the food eaten and was never bilious. There was no history of abdominal pain, dysphagia, fever or headache. The colour of stools was normal but he had complained of constipation for 6 days prior to admission. He also admitted to weight loss, which could not be quantified.

Prior to attending QECH he had been seen in several health facilities and had been treated with promethazine, but had had no relief of his symptoms. An endoscopy done at another hospital was documented as follows: 'endoscopy shows reflux oesophagitis and lax lower oesophageal sphincter' There was no comment on whether there were structural abnormalities at the level of the pylorus or duodenum.

He had been diagnosed with type 2 diabetes mellitus in December 2010 on the basis of high random blood glucose readings. He had been prescribed glibenclamide but stopped as he felt it was making him vomit more, and was now only taking metformin. Blood glucose measurements since the start of treatment were not available so we do not know how well the diabetes had been controlled.

He had a history of moderate alcohol consumption (< 20 units per week) but had not taken alcohol since the symptoms started. He had no history of smoking. He was HIV negative. He used to work as a foreman for a construction company but had stopped work owing to the severity of his symptoms. He was married with 3 children. There was no family history of diabetes.

On examination, he was moderately cachexic and dehydrated. His blood pressure (BP) was 130/80 mmHg, temperature 37°C, pulse 92/minute, respiratory rate 28/minute. His conjunctivae were pink, there were no oral lesions and he had no lymphadenopathy, including Virchow's node. Chest examination was normal. Abdominal examination was normal except there were hard stools in the rectum. His fundoscopy showed dot and blot haemorrhages, consistent with background diabetic retinopathy.

His random blood glucose concentration was 252mg/dl and there were no ketones in his urine. Blood potassium and sodium were 3.1 mmol/L (3.6 – 5.0) and 127 mmol/L (135 – 145) respectively. He had a normal blood creatinine and no proteinuria.

Questions

- 1) *What is the differential diagnosis of his vomiting?*
- 2) *What further investigations are indicated for the vomiting?*
- 3) *What further assessments are indicated for his diabetes?*

Discussion

1) Causes of vomiting can be divided into gastrointestinal causes, central causes and metabolic causes. In this case the causes of vomiting that should be considered include gastrointestinal causes such as achalasia, gastric malignancy, pyloric stenosis, gastric or duodenal ulcer, gastroparesis and generalized motility disorders such as intestinal myopathies and neuropathies. Central causes include migraine, cyclical vomiting, psychogenic vomiting, space occupying lesions and labyrinthitis. Metabolic causes such as drugs, hypercalcaemia and hyponatraemia should also be considered.

2) A careful history and examination are crucial for obtaining a diagnosis. Tests should include bloods tests: urea, sodium and potassium to look for evidence of electrolyte imbalance - either causing vomiting or a consequence of the vomiting - and a full blood count to look for a microcytic anaemia related to possible gastrointestinal blood loss. Ideally a serum calcium level would also be performed to exclude hypercalcaemia. An abdominal X-ray is important to exclude small bowel or large bowel obstruction. Endoscopy is preferable to barium meal in investigating the stomach as it enables more pathology to be seen and biopsies to be taken. Where available final investigations would be scintigraphy, (described below) to look for evidence of delayed gastric emptying, and CT of the brain to exclude space-occupying lesions.

An endoscopy was repeated and the findings were of a normal oesophagus and a long tubular stomach with normal mucosal appearance. There was no food residue seen. The duodenum was normal to the second part. The endoscopy showed no evidence of obstruction to that level.

3) Further assessment of his diabetes should focus on screening for complications of diabetes. Although he had only been diagnosed with diabetes one month previously it is not uncommon for type 2 diabetics to have evidence of complications at the time of presentation. The finding of background retinopathy (a microvascular complication) implies duration of undiagnosed diabetes of at least 5 years in our patient. Significant nephropathy was unlikely with the absence of proteinuria although a dipstick test for microalbuminuria or a urine albumin/creatinine ratio would have been more sensitive screening tests for nephropathy. A glycosylated haemoglobin level (HbA1C), if available, would have been a useful indication of his glycaemic control.

On further inquiry, he admitted to having numb feet, erectile impotence and dizziness on standing. Monofilament sensory testing revealed sensory loss in both feet. He had marked postural hypotension with a lying BP of 160/100mmHg and standing BP of 120/80mmHg. This finding, together with the erectile impotence, was highly suggestive of diabetic sensory and autonomic neuropathy. Because we suspected

autonomic neuropathy we went on to carry out an autonomic function test using an ECG strip to demonstrate loss of respiratory sinus arrhythmia. If there is autonomic neuropathy the distance between R waves remains constant throughout the respiratory cycle. This was seen clearly in our patient, even on deep breathing (see figure 1 below).

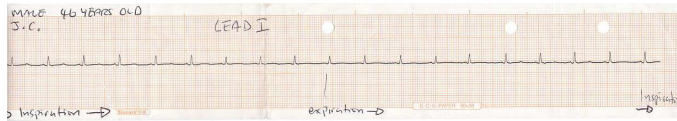


Figure 1: Lead I ECG of J.C. demonstrating loss of respiratory sinus rhythm as shown by constant R-R intervals in inspiration and expiration.

The combination of typical, intractable symptoms of vomiting, with a normal endoscopy and the presence of diabetic complications, including autonomic neuropathy, makes diabetic gastroparesis the most likely diagnosis.

Gastroparesis is the symptomatic delay in gastric emptying of solid or liquid meals secondary to impaired gastric motility in the absence of a mechanical obstruction. The common symptoms of gastroparesis include vomiting, nausea and bloating. There may also be constipation. Diabetes is implicated in the majority of cases of gastroparesis. Other causes include gastric surgery and neurological diseases e.g. multiple sclerosis, brainstem tumour/cerebral vascular accident, stress and Parkinson's disease^{1,2} and rheumatologic disorders e.g. in systemic sclerosis (scleroderma)³. Many cases are idiopathic⁴. In fact, in one highly referenced study by Soykan et al published in 1998 in the *Digestive Diseases and Sciences* journal, no specific cause could be identified in approximately one-half of patients with delayed gastric emptying in various reports.⁴

Diabetic gastroparesis may occur in people with type 1 or 2 diabetes. Studies, mostly surveys, among Caucasians with diabetes showed that 5–12% of patients had symptoms that were attributable to gastroparesis.^{5,6,7,8} There are no published data on the prevalence of gastroparesis among black patients with diabetes. Patients with diabetes in whom gastroparesis develops have often had diabetes for at least 5 years and typically have retinopathy, neuropathy, and nephropathy. Diabetic autonomic neuropathy may also lead to erectile dysfunction. This may occur in the absence of other signs of diabetic autonomic neuropathy and may be the clue that indicates that autonomic neuropathy is present. It should be remembered, however, that commonly used antihypertensive drugs, such as thiazide diuretics and β blockers, can also cause impotence. The mechanism of gastroparesis is thought to be neuropathy affecting the vagus nerve, with reduction in the numbers of inhibitory neurons that are important for motor coordination and the number of pacemaker cells (interstitial cells of Cajal).⁹

Diabetic gastroparesis may result in nutritional compromise, and impaired glucose control. The quality of life invariably becomes poor and such patients become frequent attendees at hospital.

Diagnostic testing

In cases of suspected diabetic gastroparesis, gastric outflow obstruction should first be ruled out with the use of esophagogastroduodenoscopy or a barium study of the stomach. Food retained in the stomach after a 12-

hour fast is suggestive of gastroparesis. Measurement of gastric emptying of digestible solids is the mainstay of the diagnosis of gastroparesis. Scintiscanning using a nuclear labelled meal and measuring gastric emptying using a gamma camera at 15-minute intervals for 4 hours after food intake is considered the gold standard for measuring gastric emptying in detail. However, a simplified approach involving hourly scans to quantify residual gastric content is often used in practice; retention of over 10% of the meal after 4 hours is abnormal.

Management

Key principles in the management of diabetic gastroparesis are the correction of exacerbating factors, including optimization of glucose and electrolyte levels, the provision of nutritional support, the use of prokinetic and symptomatic therapies and counselling. Improved glycaemic control is important as in some cases the neuropathy and gastric function may improve. It is advisable that these patients take small, more frequent meals that are easier to digest, especially liquids and food low in fat and fibre content. These have been shown to minimize symptoms of gastroparesis. Metoclopramide, domperidone and erythromycin are the commonest prokinetic drugs used in gastroparesis. Erythromycin interacts with the motilin receptor and may promote gastric emptying. Studies have shown these agents to increase gastric emptying by 25 to 75% and reduce the severity of symptoms by 25 to 68%.^{10,11,12} When pain relief is required, tramadol and opiates should be avoided. These have inhibiting effects on motility. Nonsteroidal agents should also be avoided as these have the potential for renal damage in patients with diabetes.

Outcome and recommendation

In this patient control of the vomiting was difficult but eventually he responded to domperidone 10 mg tds and was discharged. Perhaps predictably, he presented again after only 2 weeks when he ran out of domperidone.

This case represents a typical example of diabetic gastroparesis. It is likely that there are many diabetic patients who have this problem and the diagnosis is being missed. The case serves to remind us to always consider diabetic gastroparesis as a differential diagnosis in diabetic patients who present with chronic gastrointestinal symptoms.

References

1. Jost, WH. Gastrointestinal dysfunction in Parkinson's disease. *J NeurolSci* 2010; 289:69.
2. Camilleri, M, Prather, CM. In: Sleisenger and Fordtran's *Gastrointestinal Disease*, 6th ed, Feldman, M, Scharschmidt, BF, Sleisenger, MH (Eds), W.B. Saunders, Philadelphia 1998. p. 572.
3. Maddern, GJ, Horowitz, M, Jamieson, CG, et al. Abnormalities of esophageal and gastric emptying in progressive systemic sclerosis. *Gastroenterology* 1984; 80:887.
4. Soykan I, Sivri B, Sarosiek I, Kiernan B, McCallum RW. Demography, clinical characteristics, psychological and abuse profiles, treatment, and long-term follow-up of patients with gastroparesis. *Dig Dis Sci* 1998;43:2398-2404
5. Enck P, Rathmann W, Spiekermann M, et al. Prevalence of gastrointestinal symptoms
6. Janatuinen E, Pikkarainen P, Laakso M, Pyorala K. Gastrointestinal symptoms in middle-aged diabetic patients. *Scand J Gastroenterol* 1993;28:427-32.

7. Maleki D, Locke GR III, Camilleri M, et al. Gastrointestinal tract symptoms among persons with diabetes mellitus in the community. *Arch Intern Med* 2000;160:2808-16.
8. Bytzer P, Talley NJ, Leemon M, Young LJ, Jones MP, Horowitz M. Prevalence of gastrointestinal symptoms associated with diabetes: a population-based survey of 15,000 adults. *Arch Intern Med* 2001;161:1989-96.
9. He CL, Soffer EE, Ferris CD, Walsh RM, Szurszewski JH, Farrugia G. Loss of interstitial cells of Cajal and inhibitory innervation in insulin-dependent diabetes. *Gastroenterology* 2001;121:427-434
10. McCallum RW, Ricci DA, Rakatansky H, et al. A multicenter placebo-controlled clinical trial of oral metoclopramide in diabetic gastroparesis. *Diabetes Care* 1983;6:463-467
11. Richards RD, Davenport K, McCallum RW. The treatment of idiopathic and diabetic gastroparesis with acute intravenous and chronic oral erythromycin. *Am J Gastroenterol* 1993;88:203-207
12. Park MI, Camilleri M. Gastroparesis: clinical update. *Am J Gastroenterol* 2006;101:1129-1139