

# Ward Round - Non-resolving pleural effusion in a patient with HIV infection

Mulinda Nyirenda<sup>1</sup>, Katherine J Gray<sup>2</sup>, Theresa J Allain<sup>3</sup>, Joep J van Oosterhout<sup>3</sup>

1. Department of Medicine, Queen Elizabeth Central Hospital, Ministry of Health, Blantyre

2. Department of Microbiology, College of Medicine University of Malawi, Blantyre

3. Department of Medicine, College of Medicine University of Malawi, Blantyre

Corresponding author: Dr. M Nyirenda, C/O Dept of Medicine, College of Medicine, P/Bag 360, Blantyre, Malawi Email: mleenyirenda@yahoo.co.uk

A 33-year-old man was admitted to the medical ward at Queen Elizabeth Central Hospital for evaluation of a pleural effusion that had progressed despite anti-bacterial and tuberculosis treatment. Eight months earlier he was diagnosed with sputum smear alcohol and acid-fast bacilli [AAFB] negative pulmonary tuberculosis. At that time his symptoms were fever, night sweats, cough and shortness of breath. The results of his initial chest X-ray are not known. He received standard tuberculosis treatment (rifampicin, isoniazid, pyrazinamide and ethambutol for 2 months followed by rifampicin and isoniazid for four months). He stated that his symptoms improved during the first two months of tuberculosis treatment, but he then developed a pleural effusion that was tapped three times over the course of the four months prior to admission. Straw colored fluid was obtained twice but results of microbiological and biochemical analysis of the pleural fluid samples were not available. The last time a dry pleural tap was recorded. Courses of amoxicillin and chloramphenicol were given without improvement. Five days before admission he developed progressive complaints of productive cough with brownish sputum and shortness of breath on exertion. He had no constitutional symptoms. He was a lifetime non-smoker and had no exposure to asbestos or significant amounts of particulate matter. He was HIV positive with World Health Organization (WHO) clinical stage 3 disease (pulmonary TB) and a CD4 count of 187 cells/ $\mu$ L. He had started antiretroviral therapy with stavudine/lamivudine- nevirapine 14 weeks before admission along with cotrimoxazole prophylaxis.

On examination he was well nourished and not in respiratory distress. Discrete, firm, non-tender lymph nodes, 1-2cm in diameter were found in the sub-mandibular area. His blood pressure was 120/80 mmHg, pulse rate 100/min, respiratory rate 26/min and temperature 37.5°C. The trachea was deviated to the right side. He had reduced chest expansion, stony dull percussion and reduced breath sounds as well as a few crepitations on the right side of the chest. The rest of the examination was normal. In particular, there were no signs of heart failure, ascites or Kaposi's sarcoma. Full blood count results were as follows: WBC = 9,300/ $\mu$ L (with normal differential count), Hb = 11.7 g/dL and platelet count of 346,000/ $\mu$ L. A chest X-ray (figure 1) taken shortly after admission, showed opacification of most of the right lung with mild apical sparing, suggestive of massive pleural effusion or extensive dense consolidation. The volume of the right hemithorax appeared to be reduced. A CT scan of the chest (figure 2) was made which was reported as follows: Right pleural fluid collection of 8 by 3cm with concentric pleural

thickening in the upper right chest. Infiltrates throughout the right lung with basal bronchiectasis. No discrete mass was noted. A diagnostic pleural aspiration obtained pus-like fluid; the white blood cell count was 263,000/ $\text{mm}^3$  with 10% neutrophils and 90% lymphocytes. The protein content was 12.1g/dL and no AAFB's or bacteria were seen on Ziehl-Neelsen and gram stain respectively.

## 1. What is your differential diagnosis?

## 2. Which additional investigations would you plan?

Figure 1. Chest X-ray on admission

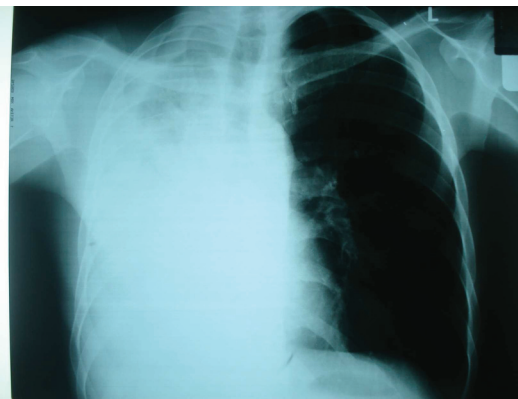
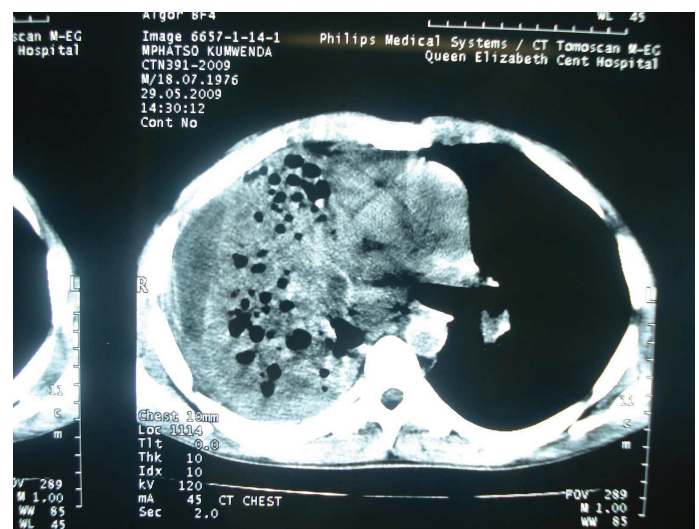


Figure 2. Detail of CT scan of the thorax. The arrow indicates the pleural empyema



## Differential diagnosis and investigations

The findings on physical examination and chest x-ray initially made us think of a massive pleural effusion. After confirmation of an empyema by pleurocentesis, we considered the following differential diagnosis: insufficiently treated bacterial empyema due to *Streptococcus pneumoniae*, *Staphylococcus aureus*, gram-negative rods or anaerobic micro-organisms<sup>1</sup> iatrogenic bacterial empyema introduced by repeated pleurocentesis (caused by *S. aureus*) and drug-resistant pleural tuberculosis. However the trachea deviation to the right and the reduced right lung volume were not consistent with right sided pleural effusion alone and the CT scan provided insight into the true nature of the abnormalities, namely a fluid collection AND diffuse consolidation with bronchiectasis or cavities in the right lung. We now favored diagnoses of drug-resistant tuberculosis, bacterial infection in a bronchiectatic lung, uncommon bacterial lung infections associated with HIV infection such as *Nocardiosis* and *Rhodococcus*, and super-infection of pre-existent structural lung abnormalities with an *Aspergillus* species.

Malignancies, such as Kaposi's sarcoma, primary serous lymphoma, mesothelioma and lung cancer seemed unlikely due to the appearance on the CT scan. The pleural fluid finding of an abundance of lymphocytes was suggestive of tuberculosis or partially treated bacterial infections.

The additional investigations we then ordered were: sputum and pleural pus for gram and Ziehl-Neelsen stains, as well as bacterial and mycobacterial cultures; blood culture; bronchoscopy (to allow visualization of possible bronchial tree abnormalities such as Kaposi's sarcoma) and broncho-alveolar lavage for microscopy and culture. We deferred pleural biopsy for histological examination.

Subsequently the culture of the pleural pus grew *Rhodococcus equi*, sensitive to tetracycline and ceftriaxone and resistant to ciprofloxacin, chloramphenicol, penicillin, cotrimoxazole and erythromycin. The patient was treated with ceftriaxone intravenously for two weeks and doxycycline for two months, with good response. The empyema was drained using an intercostal chest drain for 7 days. When seen two months after discharge from hospital he had stopped producing sputum and the shortness of breath had improved remarkably. Radiological changes in the right hemithorax were still extensively present.

## Discussion

This is the first case of *Rhodococcus equi* infection described in Malawi. *R. equi* is an aerobic, intracellular, gram-positive coccobacillus, with a worldwide distribution that causes infections in grazing animals, such as horses and foals (hence the name equi). Humans acquire the infection by inhalation or ingestion of contaminated soil or direct inoculation due to trauma. It predominantly causes disease in immunocompromised patients, in particular those with advanced HIV infection<sup>2</sup>.

The most common manifestation is a slowly progressive necrotizing pneumonia, with symptoms similar to tuberculosis. Complications such as abscess, empyema, hemoptysis, and pneumothorax can occur. Multiple nodular infiltrates with predilection for the upper lobes, cavitary pulmonary lesions and lung consolidation can be seen on chest X-ray<sup>3</sup>. As was clearly shown in our patient, CT scanning of the thorax is more sensitive to detect nodules

and cavities than a plain radiograph. Extra-pulmonary manifestations include brain abscess, lymphadenitis, peritonitis, osteomyelitis, septic arthritis, and fever of unknown origin. The characteristic histological feature is a necrotizing granulomatous inflammation dominated by macrophages containing large numbers of coccobacilli. The optimal drug regimen and duration of treatment of this severe infection have not been established. Because drug resistance may occur during therapy, it has been suggested that two active antibiotics are used, which should have good intracellular penetration. The recommended choices are imipenem, aminoglycosides, erythromycin or azithromycin, vancomycin, rifampin, and levofloxacin. However, drug sensitivity patterns from the isolated organism should be obtained. Unfortunately we were not able to use combination therapy due to limited antibiotic availability. Eradication of *R. equi* is challenging and requires long-term treatment, two months is advised for pulmonary disease<sup>3</sup>. In HIV co-infection, antiretroviral therapy may be beneficial to cure *R. equi* infection. The high mortality rate of around 25% associated with *R. equi* infections is due to several factors: missed and late diagnosis, inappropriate antibiotic therapy, and coexistent opportunistic infections<sup>4</sup>.

This case highlights the need for continued clinical vigilance after a diagnosis of smear negative pulmonary- or pleural tuberculosis in HIV-infected persons. If the response to TB treatment does not follow the expected course, vigorous diagnostic efforts should be made and a full microbiological work-up should be pursued. A microbiological diagnosis and sensitivity pattern are particularly important when long-term antibiotic treatment is indicated.

Communication with microbiology staff was essential in the diagnostic process of our case. *R. equi* could have easily been discarded as a contaminant because of the morphological similarity it has with diphtheroid bacteria on the culture medium<sup>2</sup>, but knowledge of the clinical context aided the correct identification in the laboratory.

## Conclusion

*Rhodococcus equi* pneumonia is an uncommon but not unexpected finding in patients with HIV. It has to be considered in patients with a presentation of smear-negative pulmonary tuberculosis and/or pleural effusion. A high index of suspicion facilitates the correct laboratory identification of the microorganism, which is essential for the treatment success of this severe condition.

## References

1. UpToDate. Online version 17.2. Parapneumonic pleural effusions. [www.utdol.com](http://www.utdol.com)
2. Gray KJ, French N, Lugada E, Watera C, Gilks CF. *Rhodococcus equi* and HIV-1 infection in Uganda. *Journal of Infection* 2000. 41:227-231.
3. *Rhodococcus equi* Pneumonia in Patients Infected with the Human-Immunodeficiency Virus. Report of 2 cases and review of the literature. Josep A. Capdevila; Segundo Buján; Joan Gavalda; Adelaida Ferrer; Albert Pahissa. *Scand J Infect Dis* 1997. 29:535-541
4. Donisi A, Suardi MG, Casari S, Longo M, Cadeo GP, Carosi G. *Rhodococcus equi* infection in HIV-infected patients. *AIDS* 1996. 10:359-62.