

## CASE REPORT



# An exceptional cause of acute respiratory failure in an infant: negative pressure pulmonary edema

Göktuğ Özdemir, Zeynelabidin Ozturk

Department of Pediatric Intensive Care, University of Health Sciences, Dr. Sami Ulus Obstetrics and Gynecology, Pediatric Health and Disease Training and Research Hospital, Ankara, Turkey

\*Corresponding Author: Göktuğ Özdemir; E-mail: gktg.ozd@gmail.com

## Abstract

Acute respiratory failure is an important reason for pediatric intensive care admissions. Lung parenchymal disease, airway obstruction, or neuromuscular dysfunction are the most common causes. Negative pressure pulmonary edema, characterized by pulmonary edema associated with upper airway obstruction, can rarely cause sudden onset respiratory failure. Herein, we describe an infant who suffered sudden onset respiratory failure and pulmonary hemorrhage while being held facedown for a bath, was admitted to the pediatric intensive care unit, intubated and mechanically ventilated for three days, and was diagnosed with negative pressure pulmonary edema, and discharged without any sequelae. Negative pressure pulmonary edema is a rare entity. Its true frequency is not known due to the lack of awareness. This report aimed to increase clinician familiarity with negative pressure pulmonary edema in patients with sudden onset respiratory failure and/or pulmonary hemorrhage

**Key words:** Acute respiratory failure, negative pressure pulmonary edema, pulmonary hemorrhage, upper airway obstruction

## Introduction

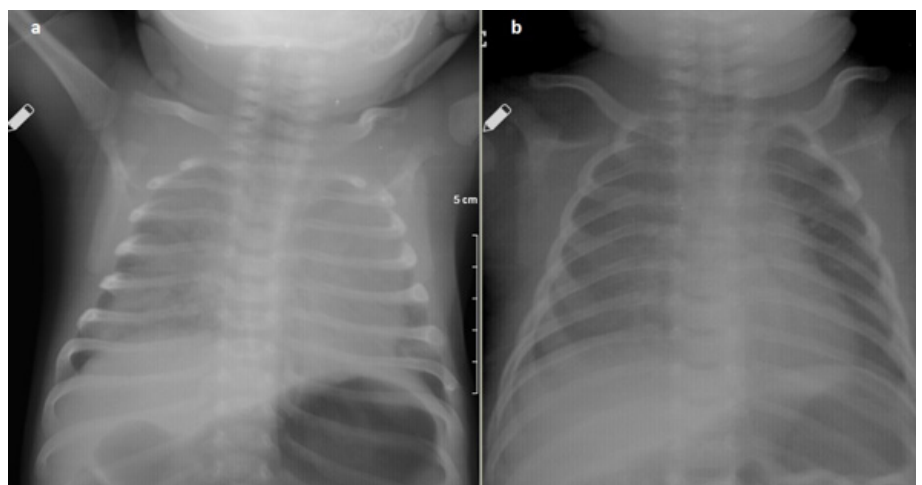
Acute respiratory failure is an important cause of pediatric intensive care admissions<sup>1</sup>. Parenchymal lung disease, airway obstruction, or neuromuscular dysfunction are the possible underlying conditions<sup>2</sup>. Medical history and physical examination play a key role in determining the possible etiology. Upper or lower respiratory tract infections (such as croup, bronchiolitis, and pneumonia), asthma, and foreign-body aspiration are the most common causes<sup>1</sup>. Pulmonary edema is one of the most likely causes in a patient with congestive heart failure. The sudden onset of respiratory failure in a healthy child can suggest acute airway obstruction, such as foreign body aspiration<sup>1</sup>. There is usually a symptomatic period before the development of respiratory failure in parenchymal diseases<sup>1</sup>. Pulmonary edema is not typical in a patient with sudden clinical deterioration. However, pulmonary edema can occur associated with upper

airway obstruction in an entity called negative pressure pulmonary edema (NPPE)<sup>3,4</sup>. The diagnosis cannot usually be made due to the lack of awareness<sup>5</sup>. Herein, we presented a case with acute respiratory failure and diagnosed with NPPE.

## Case Presentation

A 5-week-old male infant presented to the emergency room with rapid onset hemoptysis and floppiness while being held facedown for a bath. He was mottled, cyanotic, and grunting. Blood pressure was 80/60 mm Hg, heart rate was 160 beats/min, respiratory rate was 58/min, and bilateral rales were noted. Complete blood count, C-reactive protein, electrolytes, and renal function tests were normal. Arterial

blood gas analysis showed respiratory acidosis with a pH of 7.23, partial carbon dioxide pressure of 56 mm Hg, lactate level of 0.8 mmol/L and hypoxia with an oxygen saturation of 85%. The chest X-ray showed bilateral diffuse ground-glass opacification indicating pulmonary edema (Fig. 1a). The echocardiogram was normal. The patient was transferred to the pediatric intensive care unit and was intubated. High amounts of blood-tinged secretions and frank blood were suctioned from the endotracheal tube. The patient received respiratory support with 8 cm H<sub>2</sub>O of positive end-expiratory pressure, 20 cm H<sub>2</sub>O of peak inspiratory pressure, and 60% of FiO<sub>2</sub>. Sulbactam-ampicillin was started empirically. No diuretics or inotropes were required. On the 3rd day of hospitalization, the patient was extubated after confirming the resolution of the pulmonary edema by a chest X-ray (Fig. 1b). Non-invasive ventilation or oxygen supply was not required after extubation. The antibiotic treatment was stopped. Sudden onset of respiratory failure findings,



**Figure 1. Chest X-rays on admission (a) and after extubation (b): Bilateral diffuse ground-glass opacification suggesting pulmonary edema on initial chest x-ray (a), and resolution of the pulmonary edema after positive pressure ventilation (b).**

possible history of asphyxia, pulmonary edema on X-ray, exclusion of cardiogenic causes, and rapid improvement with mechanical ventilation suggested a diagnosis of NPPE. The patient was discharged on the 9th day of hospitalization with no sequelae. He remains well and the neurological examination was normal at the 4th month of follow-up. Consent for publication has been obtained from the parents.

## Discussion

NPPE manifests with rapid onset pulmonary edema after inspiratory efforts against an obstructed airway<sup>3,4,5</sup>. The relation between upper airway obstruction and pulmonary edema development was radiologically demonstrated in 1973 and was first described in a report of 3 cases in 1977<sup>6,7</sup>. During this condition, the more negative intrathoracic pressure facilitates the return of venous blood to the heart resulting in transvascular fluid filtration and pulmonary edema<sup>3,6,7</sup>. The most common causes are upper airway infections, tumors, and laryngospasm<sup>3</sup>. Asphyxiation by choking/strangulation and biting the endotracheal tube in anesthetized postoperative patients can also cause NPPE<sup>3,8</sup>. A 12-year-old boy has been reported to develop NPPE shortly after a short choking episode with a cookie<sup>5</sup>. In our patient, water aspiration causing laryngospasm and/or excessive neck flexion during bathing were suspected of causing upper airway obstruction.

As in the presented case, NPPE is usually a benign condition. Although it is initially life-threatening, it usually resolves in 24-48 hours<sup>3</sup>. Non-invasive or invasive positive pressure ventilation, oxygen, and diuretics are generally required for NPPE<sup>2,3,8</sup>. Our patient had a rapid clinical response under mechanical ventilation without forced diuresis.

One of the problems in the presented patient was pulmonary hemorrhage. It is not a frequently expected manifestation in NPPE. It is a rare manifestation in NPPE<sup>9,10</sup>. Many conditions cause pulmonary hemorrhage in children. Many require multiple diagnostic tests and imaging studies<sup>11</sup>. Missing diagnosis of a benign disease like NPPE due to unfamiliarity with this entity can cause many diagnostic procedures to be performed unnecessarily. In the presented patient, infections and foreign body aspiration, the most common

causes, were excluded by history and physical examination, and cardiogenic causes were excluded by echocardiography. Suspicion of asphyxia during the bath and pulmonary edema on the chest X-ray suggested the diagnosis of NPPE.

NPPE is a rare entity. Its true frequency is not known due to the lack of awareness. To our knowledge, it has not been previously reported in infants. This report aimed to increase clinician familiarity with NPPE in patients with sudden onset respiratory failure and/or pulmonary hemorrhage.

## References

1. Hammer J. Acute respiratory failure in children. *Paediatr Respir Rev*. 2013;14(2):64-9.
2. Friedman ML, Nitu ME. Acute Respiratory Failure in Children. *Pediatr Ann*. 2018;47(7):e268-73.
3. Bhattacharya M, Kallet RH, Ware LB, Matthay MA. Negative-Pressure Pulmonary Edema. *Chest*. 2016;150(4):927-33.
4. Lemyze M, Mallat J. Understanding negative pressure pulmonary edema. *Intensive Care Med*. 2014;40(8):1140-3.
5. Toukan Y, Gur M, Bentur L. Negative pressure pulmonary edema following choking on a cookie. *Pediatr Pulmonol*. 2016;51(7):E25-7.
6. Capitanio MA, Kirkpatrick JA. Obstructions of the upper airway in children as reflected on the chest radiograph. *Radiology*. 1973;107(1):159-61.
7. Oswalt CE, Gates GA, Holmstrom MG. Pulmonary edema as a complication of acute airway obstruction. *JAMA*. 1977;238(17):1833-5.
8. Bhaskar B, Fraser JF. Negative pressure pulmonary edema revisited: Pathophysiology and review of management. *Saudi J Anaesth*. 2011;5(3):308-13.
9. Schwartz DR, Maroo A, Malhotra A, Kesselman H. Negative pressure pulmonary hemorrhage. *Chest*. 1999;115(4):1194-7.
10. Menon A, Kavaliunaite E. Infant presenting with pulmonary hemorrhage as a sequelae of accidental asphyxiation. *Pediatr Pulmonol*. 2021;56(10):3445-6.
11. Godfrey S. Pulmonary hemorrhage/hemoptysis in children. *Pediatr Pulmonol*. 2004;37(6):476-84.