

# A rare case of Odontogenic Keratocyst in the Maxillary Sinus: diagnosis and management

Sindhusha Reddy Palem\*, Visalakshi Devarakonda, Prasad Navakoti, Karuna Sree Pendyala

Government Dental College & Hospital, Hyderabad

\*Corresponding Author: Sindhusha Reddy Palem; E-mail: [sindhushareddy2@gmail.com](mailto:sindhushareddy2@gmail.com)

## Abstract

Odontogenic keratocyst is a benign intraosseous lesion of odontogenic origin which is characterized by its aggressive nature. It is usually present in the mandibular posterior area, although it can also be found in the maxilla, particularly in the canine region. We discuss a unique example of OKC in the maxillary sinus involving the 27&28 region. Due to comparable clinical signs, this lesion is more prone to be mistaken for other lesions of the maxillary sinus, such as sinusitis or polyps. On the other side, this benign disease has the potential to develop into Ameloblastoma or squamous cell carcinoma. A favorable prognosis thus depends on early identification, precise diagnosis, appropriate treatment, and follow-ups.

**Keywords:** Cyst, Diagnosis, Maxilla, Odontogenic, Rare, Sinus.

## Introduction

Philipsen's 1956 description of Odontogenic keratocyst was the first<sup>1</sup>. They are categorized as benign lesions with aggressive behavior and a high recurrence rate that have an intraosseous odontogenic origin<sup>2</sup>. Their genesis comes from the dental lamina histologically, and they are made up of a cystic area that is walled by para keratinized squamous epithelium that is about 5 - 10 cell layers thick and has palisaded columnar or cuboidal cells with vertically orientated nuclei forming the basal layer<sup>3</sup>. Odontogenic keratocysts represent about 10-12 % of odontogenic cysts of jaws with a peak incidence in the 2nd to 3rd decade of life<sup>4-6</sup> with a slight predilection for males<sup>7</sup>.

Mandible is the most common site of occurrence with about 65 - 78 % of cases occurring in the lower jaw<sup>8,9</sup> in the ramus and molar region<sup>10</sup>. Only 22% of instances of OKC in the maxilla<sup>8,9</sup> and only 1% of cases of OKC in the maxillary sinus have been documented in the literature<sup>11</sup>. One of the four Paranasal sinuses, the Maxillary sinus is susceptible to odontogenic tumours, cysts, and infections of odontogenic origin. In this report, we describe a case of OKC involving the left maxillary sinus region in a 28-year-old male patient.

## Case Presentation

A male patient aged 28 years reported to the Department of Oral and Maxillofacial Surgery, Government Dental College and Hospital, Hyderabad with a chief complaint of foul odor and dull pain that had been present for the previous three months in the left maxillary posterior teeth region. The discomfort was dull, sporadic, and occasionally accompanied with pus discharge. Intraoral soft tissue examination revealed a diffuse unnoticeable swelling in the 27,28 region associated with tenderness on palpation with respect to mucobuccal fold of that region. Intraoral hard tissue examination revealed dull sound on percussion in the 28. OPG and CT scans revealed a well-defined radiolucent lesion associated with root apices of 27,28 extending and involving the left maxillary sinus. (Figure 1,2). On aspiration, a dirty, creamy white fluid was drawn and the FNAC study showed the presence of squamous and an abundance of

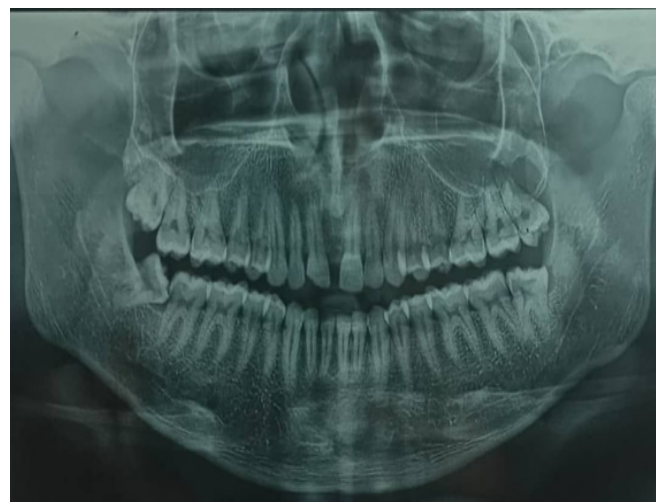

Figure 1: Orthopantomograph showing the extent of the lesion

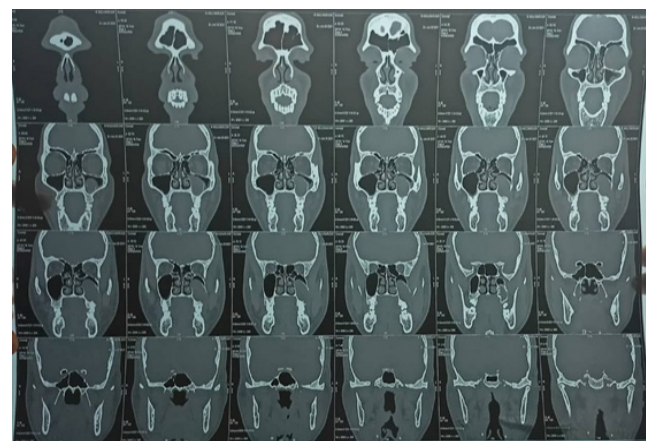
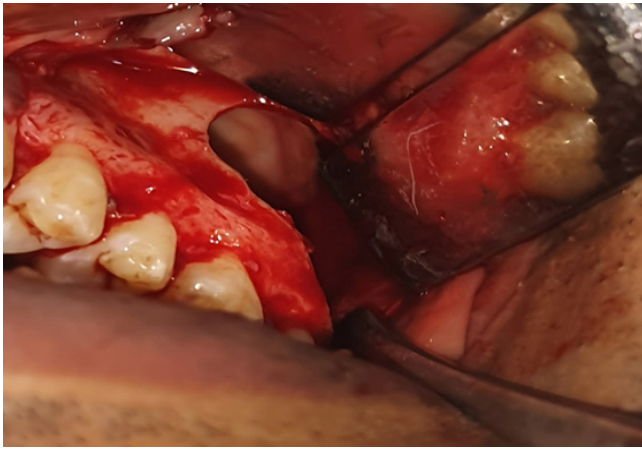
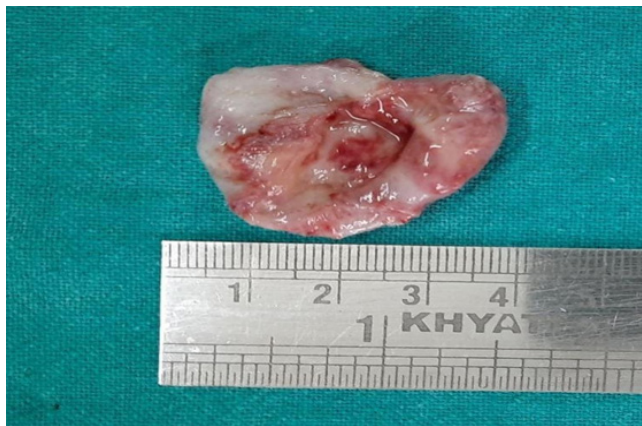
Figure 2: CBCT showing involvement of left maxillary sinus by the lesion

eosinophilic material along with cholesterol crystals, which was suggestive of OKC. After careful examination of all the clinical symptoms, radiographic evidences and laboratory results, excision was planned under local anesthesia. Using 2% lignocaine in 1:80,000 dilution of adrenaline, Posterior superior alveolar, Middle superior alveolar and Greater



**Figure 3:** Figure showing residual cavity after enucleation of the cyst



**Figure 4:** Figure showing excised lesion

palatine nerve blocks were given. After ensuring complete anesthesia, crevicular incision was given from 24 to 28 region with a relieving incision distal to canine. Mucoperiosteal flap was reflected. There was thinned out bone at the apical third of 27,28 region, which was trimmed, explored and complete excision of the cyst was done, followed by careful application of Carnoy's solution (Figure 3,4). Suturing was done after thorough irrigation.

The microscopic examination of the specimen revealed para-keratinized stratified squamous epithelium of 6-8 layers of thickness. It also revealed nuclear hyperchromatism and palisading of the basal cells. A fibrous cystic wall with dense infiltration of inflammatory cells was observed and the focal portions were bordered with pseudostratified ciliated columnar epithelium, which is typical of the maxillary sinus. Suture removal was done after 1 week and the healing was uneventful.

## Discussion

OKC accounts for 10–12% of all the odontogenic cysts, and it was thought to be a cyst generated from the dental lamina or its remnants along with the basal cells of the underlying epithelium<sup>12</sup>. The origin of Odontogenic keratocyst in the maxillary sinus was always a debatable topic, it is assumed to be arising from the entrapment of odontogenic epithelium within the maxillary sinus due to close anatomical association between dental laminal remnants and the developing maxillary sinus<sup>13</sup>.

About 11- 12 % of maxillary sinusitis cases are a result of odontogenic infections and pathology<sup>14</sup>. OKC usually manifests as a single, isolated lesion. But multiple lesions are often found in some syndromes like Gorlin Goltz. It often

manifests as a periapical lesion. In this report, we described a maxillary sinus case resembling those described by Silva et al. and Sheetal et al.<sup>11,15</sup>

On a radiographic image, OKC manifests as a well-defined, multilocular or unilocular radiolucency<sup>12</sup>. The radiographic assessment in the current case report utilized a CT scan and OPG, which revealed an obliteration of left maxillary sinus and the involvement of the periapical surface of 27,28.

With a characteristic histological picture of OKC, the surgical examination revealed the true pathological condition. Due to its potentially aggressive character and high recurrence rate, it is crucial for the clinician to identify OKC even in uncommon places and to administer the appropriate therapy as soon as possible.

## Conclusions

It is quite uncommon to have OKC in the maxillary sinus. To add to the body of knowledge, we describe the potential for OKC in the maxillary sinus and place emphasis on its early diagnosis given that it typically lacks recognizable clinical and radiographic signs and is incredibly aggressive and recurring in nature.

## References

1. Philipsen HP, Om keratocyster (kolestentomer) in the jaws. *Tandlaegebladet*. 1956;60(1):963-81. [https://scholar.google.com/scholar\\_lookup?journal=Tandlaegebladet&title=Om+keratocyster+\(kolesteratomer\)+i+kaeberne&author=HP+Philipsen&volume=60&publication\\_year=1956&pages=963-971&](https://scholar.google.com/scholar_lookup?journal=Tandlaegebladet&title=Om+keratocyster+(kolesteratomer)+i+kaeberne&author=HP+Philipsen&volume=60&publication_year=1956&pages=963-971&)
2. Antonoglou GN, Sándor GK, Koidou VP, Papageorgiou SN. Non-syndromic and syndromic keratocystic odontogenic tumors: systematic review and meta-analysis of recurrences. *Journal of cranio-maxillofacial surgery*. 2014 Oct 1;42(7):e364-71. <https://doi.org/10.1016/j.jcms.2014.03.020>
3. Andrea B, Cosimo N, Caterina G. Odontogenic keratocyst: imaging features of a benign lesion with an aggressive behavior. *Insights Imaging*. 2018;9(5):883-97. <https://doi.org/10.1007/s13244-018-0644-z>
4. Bilodeau EA, Collins BM. Odontogenic cysts and neoplasms. *Surgical pathology clinics*. 2017 Mar 1;10(1):177-222. <https://doi.org/10.1016/j.path.2016.10.006>
5. Johnson NR, Gannon OM, Savage NW, Batstone MD. Frequency of odontogenic cysts and tumors: a systematic review. *Journal of investigative and clinical dentistry*. 2014 Feb;5(1):9- 14. <https://doi.org/10.1111/jicd.12044>
6. Chirapathomsakul D, Sastravaha P, Jansisanont P. A review of odontogenic keratocysts and the behavior of recurrences. *Oral surgery, oral medicine, oral pathology, oral radiology, and endodontology*. 2006 Jan 1;101(1):5-9. <https://doi.org/10.1016/j.tripleo.2005.03.023>
7. Avril L, Lombardi T, Ailianou A, Burkhardt K, Varoquaux A, Scolozzi P, Becker M. Radiolucent lesions of the mandible: a pattern-based approach to diagnosis. *Insights into imaging*. 2014 Feb;5:85-101. <https://doi.org/10.1007/s13244-013-0298-9>
8. Brannon RB. The odontogenic keratocyst: A clinicopathologic study of 312 cases. Part I. Clinical features. *Oral Surgery, Oral Medicine, Oral Pathology*. 1976 Jul 1;42(1):54-72. [https://doi.org/10.1016/0030-4220\(76\)90031-1](https://doi.org/10.1016/0030-4220(76)90031-1)
9. Forssell K, Forssell H, Kahnberg KE. Recurrence of keratocysts: a long-term follow-up study. *International journal of oral and maxillofacial surgery*. 1988 Jan 1;17(1):25-8. [https://doi.org/10.1016/s0901-5027\(88\)80224-8](https://doi.org/10.1016/s0901-5027(88)80224-8)
10. Ogunsalu C, Daisley H, Kamta A, Kanhai D, Mankee M, Maharaj A. Odontogenic keratocyst in Jamaica: a review of five new cases and

five instances of recurrence together with comparative analyses of four treatment modalities. *West Indian Med J.* 2007 Jan1;56(1):90-5. <https://doi.org/10.1590/s0043-31442007000100017>

11. Silva GC, Silva EC, Gomez RS, Vieira TC. Odontogenic keratocyst in the maxillary sinus: Report of two cases. *Oral Oncology Extra.* 2006 Jul 1;42(6):231-4. <https://doi.org/10.1016/j.ooe.2006.01.002>

12. Shear M, Speight PM. *Cysts of the oral and maxillofacial regions.* John Wiley & Sons; 2008 Apr 15. <https://onlinelibrary.wiley.com/doi/book/10.1002/9781119354963>

13. Cioffi GA, Terezhalmay GT, Del Balso AM. Odontogenic keratocyst of the maxillary sinus. *Oral Surgery, Oral Medicine, Oral Pathology.* 1987 Nov 1;64(5):648-51. [https://doi.org/10.1016/0030-4220\(87\)90077-6](https://doi.org/10.1016/0030-4220(87)90077-6)

14. Çakur B, Miloglu Ö, Yolcu Ü, Göregen M, Gürsan N. Keratocystic odontogenic tumor invading the right maxillary sinus: a case report. *Journal of oral science.* 2008;50(3):345-9. <https://doi.org/10.2334/josnusd.50.345>

15. Sheethal HS, Rao K, Umadevi HS, Chauhan K. Odontogenic keratocyst arising in the maxillary sinus: A rare case report. *Journal of Oral and Maxillofacial Pathology: JOMFP.* 2019 Feb;23(Suppl 1):74. [https://doi.org/10.4103/jomfp.JOMFP\\_319\\_18](https://doi.org/10.4103/jomfp.JOMFP_319_18)