

# A complicated pregnancy: Eclampsia or COVID-19?

Ayşe Özcan<sup>1</sup>, Yusuf Harun İren<sup>1</sup>, Cigdem Kizilay<sup>1</sup>, Yusuf Ustun<sup>2</sup>, Cetin Kaymak<sup>1</sup>, Hulya Basar<sup>1</sup>

<sup>1</sup> University of Health Sciences, Ankara Training and Research Hospital, Department of Anesthesiology and Reanimation, Ankara, Turkey

<sup>2</sup> University of Health Sciences, Ankara Training and Research Hospital, Department of Obstetrics and Gynecology, Ankara, Turkey

Corresponding Author; Ayşe OZCAN; Email address: ayseongun@gmail.com

## Abstract

Pregnant women may be infected with SARS-CoV-2 virus and develop serious complications of the disease. Covid-19 causes primarily a respiratory system infection but can also affect cardiovascular, renal, gastrointestinal, and neurological systems. Cardiovascular involvement includes new onset hypertension, myocarditis, cardiomyopathy, pulmonary embolism, and pre-eclampsia like syndrome.

We report a confirmed Covid-19 pregnant case presented with eclampsia to the emergency department and undergone emergent cesarean section. Following surgery, she was admitted to the intensive care unit due to hypoxemia and hypertension. After observing lymphopenia and high CRP level with hypoxemia, radiological imaging revealed typical findings for viral pneumonia and nasopharyngeal swab, which was not carried out at admission, was positive for Covid-19. On the 20th hour of follow-up, she became hypotensive requiring noradrenalin infusion. Echocardiography diagnosed cardiomyopathy with left ventricular ejection fraction of 35-40 % with high levels of NT pro-BNP, hs-troponin, and CK-MB in the patient.

Covid-19 should be considered in complicated pregnancies. In complicated cases, a chest CT scan upon admission may aid in quickly detecting the presence of infection and preventing nosocomial spread of the virus. Cardiomyopathy could be found in pregnant patients with Covid-19 infection. Since cardiomyopathy can be seen in late pregnancy and early postpartum period, it is difficult to distinguish between viral and postpartum cardiomyopathy in these patients. Recognizing the infection earlier will help to anticipate the complications that might contribute to deterioration of the patients, perioperatively.

Keywords: Cardiomyopathy, Covid-19, cesarean section, eclampsia, pregnancy

## Introduction

The coronavirus disease-19 (Covid-19) was declared as a pandemic in March 2020 by World Health Organization and data concerning the risks of the disease in pregnancy is still limited<sup>1</sup>.

Pregnancy is partially an immune suppressive state and susceptibility to viral infections is increased<sup>2</sup>. There is evidence that pregnant women have increased risk of morbidity and mortality from viral infections. Lam et al showed that mortality, intensive care unit admission and organ failure rates were higher in pregnant population compared to non-pregnant with Severe Acute Respiratory Syndrome (SARS) infection<sup>3</sup>.

Physiological changes occurring in pregnancy may interfere with the pathophysiology of Covid-19 and may increase the severity of the viral disease<sup>4</sup>. Covid-19 causes primarily a respiratory system infection but also affects cardiovascular, renal, gastrointestinal, and neurological systems. Cardiovascular involvement appears as new onset hypertension, acute myocardial infarction, myocarditis, cardiomyopathy, arrhythmias, thromboembolic events, and pre-eclampsia like syndrome<sup>2,5</sup>.

The prevalence of cardiovascular disease in COVID-19 patients is still unclear. The hyperinflammatory state, increased metabolic demand, hypoxemia and high rates of thromboembolic events increase the risk of cardiovascular complications in Covid-19 patients<sup>6</sup>.

Additionally, Angiotensin Converting Enzyme 2 (ACE2) has an important role in cardiovascular complications in

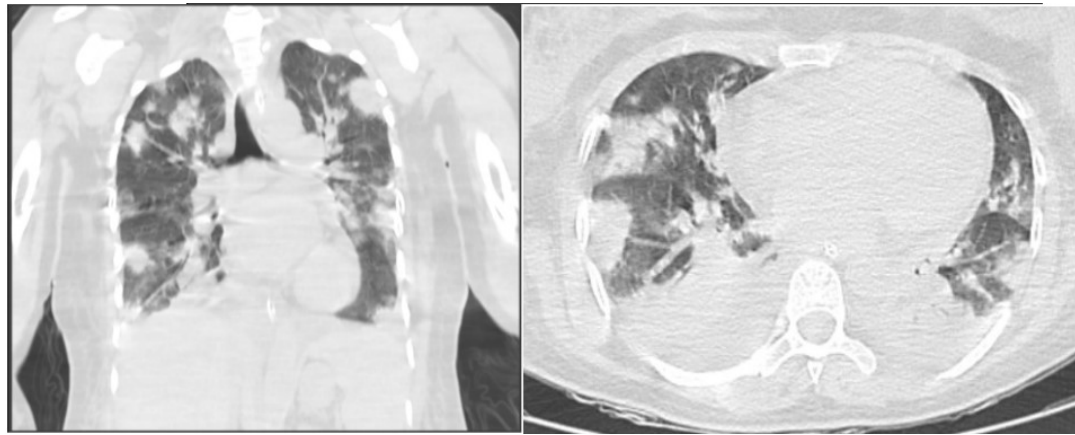
Covid-19 as the virus can directly affect the heart via ACE2 receptors found in the cardiac tissue<sup>7</sup>.

We discussed a confirmed Covid-19 pregnant case presented with hypertension and convulsions to the emergency service and later complicated with cardiomyopathy related with pregnancy or Covid-19.

## Case Report

A 30-year-old Caucasian housewife, gravida five, para four, healthy pregnant woman at 38 weeks of gestation presented to the emergency department with hypertension and seizures. She had no history of smoking, comorbidity, or medication previously. Her estimated body weight was 75 kilograms. She had four full-term vaginal deliveries without any complications. During her recent pregnancy, she had regular antenatal visits and no comorbidities or medications. She'd been suffering from headache and dizziness since the previous day. Her body temperature was 36,2°C, her blood pressure was 187/116 mmHg, and she was having convulsions when she was admitted to the emergency department. Her physical exam was described as unremarkable. She was consulted by an obstetrician and had a cesarean section immediately after being diagnosed with eclampsia. Except for a high D-dimer level of 2520 µg/L (0-500 µg/L) and mild thrombocytopenia of 119 x10<sup>9</sup>/L (150-450 x10<sup>9</sup>/L), all blood tests were normal. 2+ proteinuria was found in the urine.

Prior to the induction of general anesthesia, her heart rate was 120/min, her blood pressure was 178/109 mmHg, and her SpO<sub>2</sub> was 84%.



**Figure 1. Chest computerized tomography of the patient showing ground-glass opacities and pleural effusion on both sides of the lungs**

The anesthetist did not extubate the patient at the end of the surgery due to persistent hypoxemia and hypertension. Hypoxemia was thought to be linked to aspiration of the gastric contents as a result of eclamptic convulsions. Following surgery, she was admitted to the intensive care unit (ICU). When she was admitted to the ICU, she was sedated and had a blood pressure of 137/88 mmHg, tachycardia with a heart rate of 128/min, an oxygen saturation of 88%, and a temperature of 36,8°C. She was mechanically ventilated with a pressure support of 18 cmH<sub>2</sub>O, providing a tidal volume of approximately 450 ml, PEEP: 14 cmH<sub>2</sub>O, FiO<sub>2</sub>: 80%, frequency: 18/min, and parameters were adjusted on a regular basis based on blood gas analysis. The arterial blood gas analysis revealed both respiratory and metabolic acidosis, with the following values: pH: 7,12, pCO<sub>2</sub>: 63,8, pO<sub>2</sub>: 92, SpO<sub>2</sub> 91,8 %, HCO<sub>3</sub>: 16, BE: -8. Laboratory findings revealed lymphopenia of 670/mm<sup>3</sup>, platelets of 107,000 x10<sup>9</sup> /L, AST 50 IU/L, ALT 19 IU/L, high C-Reactive Protein (23mg/L) and NT pro-BNP (12,556 ng/L). In the repeated urine test, she had 2+ protein. Ceftriaxone 2 gr, metronidazole 500 mg three times a day, enoxaparin 0,4 ml twice daily, magnesium infusion at a rate of 1,5 gr/hour and paracetamol 1 g were administered as initial therapy. Antihypertensive medication was not required. Blood, urine, and tracheal cultures were performed and found to be negative. After observing lymphopenia and high CRP level with hypoxemia, a chest X-ray and computerized tomography (CT) were performed, revealing typical findings for viral pneumonia and pleural effusion (21 mm) on both sides. Findings were classified as CO-RADS 5 (Figure 1). A nasopharyngeal swab was collected for Covid-19 rt-PCR, which was positive 6 hours after admission. Favipiravir and dexamethasone 6 mg were added to the treatment and antibiotic therapy was changed to meropenem by the infectious disease consultant specialist. She had no known contact with any Covid-19 case. On the 20th hour of follow-up, she became hypotensive, noradrenalin infusion was started at a dose of 0,1 µg/kg/min and was continued for 24 hours. Echocardiography was performed, and cardiomyopathy was diagnosed, with a left ventricular ejection fraction of 35-40%, 1st-2nd degree mitral insufficiency, 1st degree tricuspid insufficiency, and basal hypokinesia. The magnesium infusion was stopped. Furosemide was added to the treatment regimen. Troponin levels of 316 ng/L (<14 ng/L) and CK-MB levels of 18,06 g/L (<2,88 g/L) were found to be high. The next day, troponin increased to 518,8 ng/L, while CK-MB increased to 30,18 µg/L. There was no change in the electrocardiogram. The trachea was

extubated 30 hours after admission following successful weaning from mechanical ventilation. After extubation, she unexpectedly became dyspneic and tachypneic and was ventilated non-invasively with Continuous Positive Airway Pressure (CPAP) mode via face mask for 6 days. The level of NT pro-BNP was decreased to 3506 ng/L (<177,6 ng/L). She was transferred to the ward after her respiratory and hemodynamic conditions had stabilized.

### Discussion

Pregnant women may be infected with SARS-CoV-2 virus. However, there is still insufficient data on the course of Covid-19 in pregnancy. Pregnant patients with Covid-19 may become critically ill at any time during the disease, with an increased risk of hospitalization, ICU admission, and need for mechanical ventilation compared to non-pregnant women, and majority of the critically ill are in the third trimester<sup>8</sup>.

The recent eclamptic pregnant patient was later confirmed as Covid-19 with low oxygen saturation and laboratory findings. The initial high blood pressure levels lowered unexpectedly, raising clinical concerns about cardiac involvement of the viral disease or pregnancy. This case report represents the challenging discrimination between eclampsia and complicated pregnancy in Covid-19.

The patient was undergone emergent cesarean section due to hypertension and convulsions. Covid-19 can cause hypertension, thrombocytopenia and changes in transaminase levels and induce pre-eclampsia-like syndrome<sup>9</sup>. In a meta-analysis Covid-19 was found to be associated with a higher rate of pre-eclampsia<sup>10</sup>. Proinflammatory mediators such as interleukin-2, interleukin-6 and tumor necrosis factor alpha are increased in both Covid-19 and preeclampsia. Maternal ferritin levels were also found to be elevated in preeclampsia and Covid-19, indicating a hyperinflammatory state<sup>11</sup>. The release of proinflammatory cytokines stimulates the production of tissue factor and activates clot formation<sup>2</sup>. Shanes et al reported placental pathologies in 16 Covid-19 patients, revealing decidual arteriopathy with an increase in intervillous thrombi, resulting in maternal vascular malperfusion<sup>12</sup>. Another mechanism that may play a role in the development of preeclampsia may be via angiotensin converting enzyme 2 (ACE2) expression. ACE2 converts Angiotensin 2 to Angiotensin 1-7 to regulate blood pressure. SARS-CoV-2 binds to ACE2 receptor to enter the cell. ACE2 is expressed through human placenta, in the syncytiotrophoblast, endothelium and smooth muscle of the vessels. ACE2 expression may change in Covid-19 infection

and Angiotensin 2 level rises in the placental villi causing vasoconstriction and reduced fetal blood flow<sup>11</sup>. Khan et al. reported 29,1% of preterm birth and 16,4% low birth weight among babies of pregnant women with Covid-19<sup>13</sup>.

Symptoms of pre-eclampsia or eclampsia can overlap with Covid-19 and it is important to differentiate them to manage the diseases. Patients with Covid-19 may also experience neurological symptoms such as headaches, seizures, and loss of consciousness. Proteinuria can also be seen in correlation with the severity of the disease<sup>14,15</sup>. Several studies have found a link between Covid-19 and an increased risk of preeclampsia, eclampsia, and HELLP syndrome. However, it is unclear whether Covid-19 causes preeclampsia-like syndrome or increases the risk of preeclampsia directly<sup>16</sup>. Ultrasonography and laboratory biomarkers should also be used to diagnose true preeclampsia. Mendoza et al discovered preeclampsia in 12% of 42 consecutive Covid-19 pregnant patients in a prospective observational study. Uterine artery pulsatility and abnormal angiogenic markers were determined in only one case. They concluded that severe Covid-19 may induce preeclampsia-like syndrome in pregnant women<sup>9</sup>. In these patients, the symptoms associated with the viral infection resolve through clinical improvement rather than emergency delivery<sup>17</sup>.

Cardiac injury caused by Covid-19 has not been evaluated in pregnant population. Case reports will reveal details about the disease's progression. Bradycardia, acute coronary syndrome, myocarditis, and cardiomyopathy can all be complications of Covid-19-related cardiac injury<sup>18</sup>. Cardiac biomarkers may reveal myocardial injury. Mercedes et al reported that 15 of 154 pregnant patients with Covid-19 infection who became critically ill had a decreased ejection fraction and elevated pro-BNP and troponin-I levels<sup>19</sup>. In our patient h-troponin and myoglobin levels were found to be elevated, indicating myocardial injury. The level of NT pro-BNP was also elevated, which could indicate cardiomyopathy or acute heart failure. According to Guo et al, cardiomyopathy can be found in up to 33% of non-pregnant Covid-19 patients admitted to ICU<sup>7</sup>. However, the prevalence of cardiomyopathy in pregnant Covid-19 patients is unknown. Two of the seven pregnant women with Covid-19 in a case series had cardiomyopathy with ejection fractions of 40-45% and global hypokinesia<sup>20</sup>. Hyperinflammation in Covid-19 causes myocarditis and ventricular dysfunction. Also, peripartum cardiomyopathy should be considered if cardiac decompensation occurs after delivery<sup>21</sup>. A delayed diagnosis of cardiac decompensation may result in a poor prognosis. In our patient left ventricular ejection fraction was moderately reduced, and basal hypokinesia was observed. Since cardiomyopathy can be seen in late pregnancy and early postpartum period, it is difficult to distinguish between viral and postpartum cardiomyopathy in these patients.

Cao et al examined 10 pregnant women with confirmed Covid-19; all had lung abnormalities on chest CT, and the clinical manifestations were similar to those seen in the non-pregnant population. Five of them had pleural effusion different from typical findings, such as a patch or ground glass opacity. None of them developed severe Covid-19 pneumonia or died<sup>1</sup>. In our patient's chest CT scan, we also observed pleural effusion. Effusions could be a sign of severe preeclampsia, Covid-19 pneumonia, or cardiomyopathy, which can be associated with both. Echocardiography should be performed on clinically deteriorating Covid-19 patients to

rule out any cardiac disorder.

Covid-19 is associated to systemic coagulopathy, which could be caused by systemic hyperinflammation, endothelial dysfunction, hypoxemia, and stasis<sup>22</sup>. The risk of thromboembolism in Covid-19 increases with the hypercoagulable state of pregnancy. High D-dimer, IL-6, ferritin, and fibrinogen levels indicate hyperinflammation and disease severity. D-dimer is a prothrombotic biomarker. However, because the D-dimer levels rise during pregnancy and peak in the third trimester, it is not a reliable marker for thromboembolism. Echocardiography and venous duplex ultrasound could be used for diagnosis of thromboembolism and cardiac events. Pulmonary computed tomography angiography is recommended in cases where there is high suspicion of thromboembolism with care radiation exposure<sup>4,6</sup>.

In conclusion, this case report highlights that COVID-19 infection appears to increase the risk of pregnancy complications. In complicated pregnancies, a chest CT scan upon admission may aid in quickly detecting the presence of infection and preventing nosocomial spread of the virus. Pathologies underlying Covid-19 infection, such as cardiomyopathy, myocarditis, and pneumonia, can complicate anesthesia and surgery. Recognizing the infection earlier will help to anticipate the complications in high-risk groups. To avoid a poor prognosis, clinically deteriorating pregnant patients with Covid-19 should be evaluated with echocardiography. We hope further studies will help us to manage Covid-19 in complicated pregnancies.

## References

1. Cao D, Yin H, Chen J, et al. Clinical analysis of ten pregnant women with COVID-19 in Wuhan, China: A retrospective study. *Int J Infect Dis* 2020; 95: 294-300
2. Herrey AS, Osman A, Soma-Pillay P, Sliwa K, Ntusi NAB. COVID-19 and the cardiovascular system in pregnancy. *SA Heart* 2020; 17(3): 288-95
3. Lam CM, Wong SF, Leung N, et al. A case-controlled study comparing clinical course and outcomes of pregnant and non-pregnant women with severe acute respiratory syndrome. *BJOG* 2004; 111(8): 771-774
4. Avila WS, de Carvalho RC. Covid-19: A new challenge in pregnancy and heart disease. *Arq Bras Cardiol* 2020; 115(1): 1-4
5. Clerkin KJ, Fried JA, Raikhelkar J, et al. COVID-19 and Cardiovascular Disease. *Circulation* 2020; 141(20): 1648-1655
6. Marques-Santos C, Avila WS, de Carvalho RCM, et al. Position Statement on COVID-19 and Pregnancy in Women with Heart Disease Department of Women Cardiology of the Brazilian Society of Cardiology -2020. *Arq Bras Cardiol* 2020; 115(5): 975-986
7. Guo T, Fan Y, Chen M, et al. Cardiovascular implications of fatal outcomes of patients with coronavirus disease 2019 (COVID-19). *JAMA Cardiol* 2020; 5(7): 811-818
8. Coronavirus (Covid-19) infection and pregnancy. Royal College of Obstetricians and Gynecologists Guidelines Version 14: updated 25 August 2021.
9. Mendoza M, Garcia-Ruiz I, Maiz N, et al. Pre-eclampsia-like syndrome induced by severe COVID-19: A prospective observational study. *BJOG* 2020; 127(11): 1374-1380
10. Arentz M, Yim E, Klaff L, et al. Characteristics and outcomes of 21 critically ill patients with COVID-19 in Washington State. *JAMA* 2020; 323(16): 1612-1614
11. Abbas AM, Ahmed OA, Shaltout AS. COVID-19 and maternal pre-  
<https://dx.doi.org/10.4314/mmj.v34i4.10>

eclampsia: A synopsis. *Scand J Immunol* 2020; 92(3): e12918

12. Shanes FD, Mithal LB, Otero S, Azad AH, Miller ES, Goldstein JA. Placental pathology in COVID-19. *Am J Clin Pathol* 2020; 154(1): 23-32

13. Khan MA, Khan N, Mustagir G, Rana J, Haque R, Rahman M. COVID-19 infection during pregnancy: A systematic review to summarize possible symptoms, treatments, and pregnancy outcomes. *medRxiv* 2020

14. Mao L, Jin H, Wang M, et al. Neurologic manifestations of hospitalised patients with COVID-19 in Wuhan, China. *JAMA Neurol* 2020; 77(6): 683-690

15. Liu R, Ma Q, Han H, et al. The value of urine biochemical parameters in the prediction of the severity of coronavirus disease 2019. *Clin Chem Lab Med* 2020; 58(7): 1121-1124

16. Villar J, Ariff S, Gunier RB, et al. Maternal and Neonatal Morbidity and Mortality Among Pregnant Women With and Without COVID-19

Infection The INTERCOVID Multinational Cohort Study. *JAMA Pediatr* 2021; 175(8): 817-826

17. Rolnik DL. Can COVID-19 in pregnancy cause pre-eclampsia? *BJOG* 2020; 127(11): 1381

18. Ghio S, Baldi E, Vicentini A, et al. Cardiac involvement at presentation in patients hospitalized with COVID-19 and their outcome in a tertiary referral hospital in Northern Italy. *Intern Emerg Med* 2020; 15(8): 1457-1465