

# A rare lesion of breast: Hydatid cyst

Sinan Sozutok<sup>1</sup>, Omer Kaya<sup>1</sup>, Huseyin Akkaya<sup>2\*</sup>, Bozkurt Gulek<sup>3</sup>

1. Cukurova University, School of Medicine, Department of Radiology, Adana-Turkey

2. Siverek State Hospital, Department of Radiology, Sanliurfa-Turkey

3. University of Health Sciences, Adana Teaching and Research Hospital, Department of Radiology, Adana-Turkey

\*Corresponding Author: Huseyin Akkaya, Email; dr.hsynakkaya@gmail.com

## Abstract

Hydatid cyst (HC) is a lesion most commonly seen in the liver but can occur in many parts of the body. Breast involvement with HC is extremely rare. It can be isolated or accompanied by other organ involvements. In this report, we present a 46-year-old female with isolated HC located in the right breast. In the ultrasonography and MR images of the patient, the lesion was compatible with the HC, and homogenous dense lesion was shown on mammography. Diagnosis of HC was confirmed pathological. With this study, it was aimed to emphasize the radiological findings of isolated breast HC.

**Keywords:** Hydatid cyst, Breast, Imaging, PAIR

## Introduction

The most common organ of hydatid cyst (HC) disease is the liver, also lungs, soft tissues, kidney, spleen and bone involvement may also be seen, respectively<sup>1,2</sup>. Breast is a rare site for HC and only 0.2% of all HC are located in the breast<sup>3</sup>. Breast HC may be isolated or a part of disseminated hydatidosis. It can mimic tumors and other lesions, because of both this reason and its rarity, HC may be misdiagnosed<sup>4</sup>. Radiological methods are generally sufficient for diagnosis, but serological tests are used for suspicious lesions<sup>5</sup>. Although preoperative diagnosis is usually made radiologically or by aspiration, it can rarely be diagnosed after surgery<sup>4</sup>. In this study, ultrasonography (US), mammography, computed tomography (CT) and magnetic resonance imaging (MRI) features of isolated breast HC that we performed preoperative puncture-aspiration-injection-reaspiration (PAIR) were revealed. The study was carried out in accordance with the provisions of the Declaration of Helsinki and the Good Clinical Practice guidelines. Ethics committee approval was not obtained because the study is a case presentation but oral informed consent was obtained.

## Case Presentation

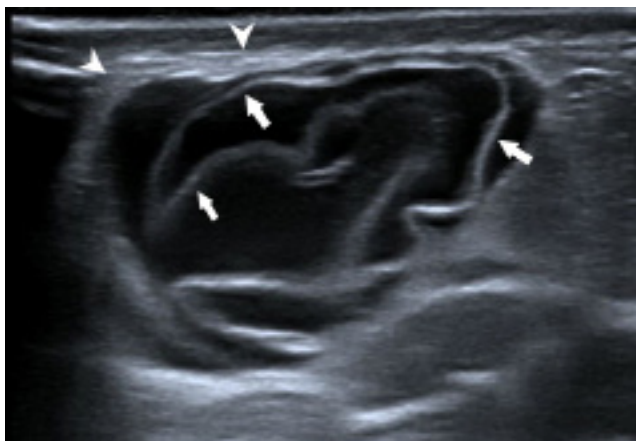
A 46-year-old female patient was admitted to the hospital with a painless mass in the lower inner quadrant of right breast, which showed rapid growth in a short time. In the US examination, a cystic lesion with thick walls and containing detached membranes, 25x25 mm in size, was detected in the peripheral location at the 4–5 o'clock position of the right breast (Fig.1). In mammography, there was an oval-shaped and smoothly bounded radio-opaque lesion, with no clear calcification (Fig.2). There was no family history of malignancy or suspicious animal contact in the patient's story. However, due to rapid growth, aspiration was performed with US guidance for histopathological diagnosis. With the obtaining material in the form of rock water in aspiration and detecting membrane detachment on US, the cyst was diagnosed radiologically as HC. PAIR was applied to the cyst to prevent aspiration related contamination prior to surgery for the purpose of treatment. PAIR procedure was applied with hypertonic saline solution. Albendazole and

antibiotherapy treatment was started for the patient. Breast MRI (Fig.3), thorax and abdominal CTs (not shown) were performed to rule out other possible HCs. The patient's history of contact with pets or farmer history was questioned in detail, but no contact history of the patient could be detected. No other focus was found in the examinations, and the patient was diagnosed as isolated breast HC. It was observed that the cystic contents of the lesion disappeared and the membrane was completely collapsed in the USG performed at the 1st month control before surgery (Fig.4). Since it was not known that the patient's cyst was hydatid, it was determined that the cyst was hydatid as a result of the detection of the membrane when the cyst was entered for needle aspiration and the outflow of rock water. In the meantime, the procedure was terminated with PAIR to prevent the hydatid cyst from spreading to the breast. However, the surgeons wanted to operate on the patient because there was no literature on PAIR application in the breast.

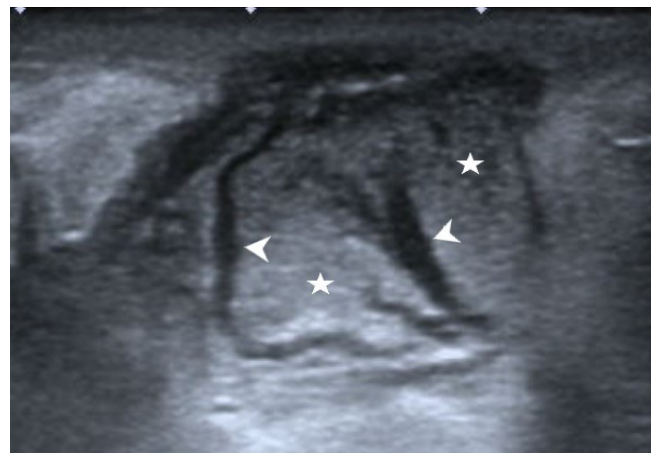In the pathological evaluation of resection material after surgical cystectomy; dead hydatid cyst wall materials, dead vesicles, extensive necrosis, inflammation, and intact breast tissue with preserved surgical margin have been reported.

## Discussion

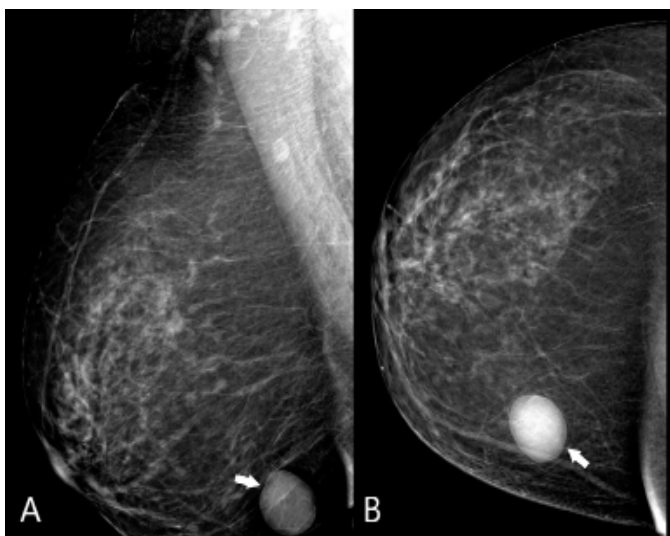
The organs where hydatid cysts are most common are the liver and lungs<sup>2</sup>. HC can occur in any part of the body where the blood circulation reaches, especially in countries where it is endemic such as Turkey<sup>3</sup>. The breast is a rare location for a HC and among all HCs, the rate of those seen in the breast is 0.2%<sup>1</sup>. Clinical presentation varies in relation to especially localization, size and stage of the cyst. HC can mimic every type of cyst since they can be seen as simple or complex cysts, depending on the stage<sup>4</sup>. The preliminary diagnosis is very important in terms of forming a surgical plan and preventing the spillage of daughter cysts during surgery<sup>6</sup>. Diagnosis of hydatid cyst can usually be made radiologically. The lesion is generally seen as a dense well-circumscribed lesion on mammography<sup>7</sup>.



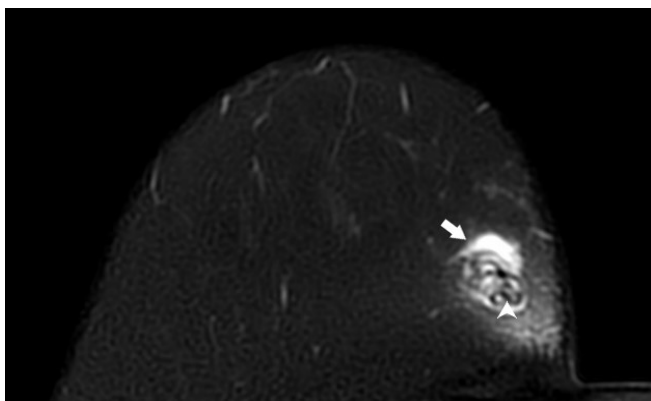
**Fig.1:** On the ultrasound image, a smoothly bounded cystic lesion with thick walls (arrow heads) and containing detached membranes (arrows) is seen



**Fig.4:** In the ultrasonographic examination performed 1 month after the PAIR procedure, isoechoic areas (stars) that are thought to represent the necrotic areas and linear hypoechoic changes compatible with the membranes are seen in the collapsed cyst



**Fig.2:** MLO (A) ve CC (B) mammography images show an oval-shaped and smoothly bounded radio-opaque lesion with no clear calcification (arrows).



**Fig.3:** On the fat-sat T2W axial MRI image, A heterogeneous hyperintense lesion (arrow) with a hypointense linear signal (arrowhead) compatible with the membrane is seen

Hydatid sand, pure fluid collection, fluid collection with a split wall, fluid collection with septa or fluid-levels can be seen according to the types of hydatid disease US.1,7 Lesions are hyperintense on T2 images and hypointense on T1-weighted images. On contrast enhanced MRI, a cystic lesion with peripheral rim enhancement is seen<sup>4,7</sup>. The differential diagnosis includes a simple or complicated cyst, fibroadenoma, phyllodes tumor and carcinoma<sup>1</sup>.

The classical treatment of a breast HC is surgical excision<sup>6</sup>. However, recurrent cysts have been reported postoperatively between 1-11% of patients<sup>8</sup>. Albendazole may decrease the recurrence rate of HC disease<sup>9</sup>. However, as in liver HCs, intermittent PAIR therapy can also be performed in breast HC<sup>10</sup>.

During surgery, the cyst was removed to contain intact breast tissue, so a volume loss and scar was formed in the surgical incision site. However, as stated in the pathology report, PAIR treatment was successful and surgical excision did not contribute to PAIR treatment. If there is no contraindication in the treatment of hydatid cyst in the breast, PAIR may be the best way to heal without leaving any traces. As an alternative to PAIR, catheterization or modified catheterization method, which is frequently used in the liver, can be used.

We also performed PAIR before surgical resection in our case. In addition, the presence of necrosis in the material obtained by surgical resection and the absence of the content of hydatid cyst may be evidence that the procedure eliminates the content related to the echinococcus infection. In the study conducted by Cakır M et al., it was emphasized that the primary treatment should be PAIR especially in early-stage cyst hydatid lesions in unusual regions<sup>10</sup>.

**Conclusion**

Although isolated HC is extremely rare, it should be kept in mind in the differential diagnosis of breast cystic lesions. Radiological methods such as US, mammography, and MRI are helpful in diagnosis, but aspiration and histopathological approach may be required for the diagnosis, especially in fast-growing lesions and suspected patient history. Treatment of breast HC is surgical resection. However, the PAIR procedure may also be an alternative treatment method for HCs in the breast.

**Declarations of Interest**

None.

## Funding

The author(s) received no financial support for the research, authorship, and/or publication of this article.

## References

- 1- Kiresi DA, Karabacakoglu A, Odev K, Karakose S. Uncommon locations of hydatid cysts. *Acta Radiol* 2003;44:622-36.
- 2- Hakverdi S, Sayar H, Yaldiz M, Erdoğan S, Akansu B, Canda MS. Unusual localization of echinococcosis in Cukurova (134 cases). *Turkiye Parazitoloj Derg* 2009;33:77-81.
- 3- Uncu H, Ereku S. Hydatid cyst of the breast. *Acta Chir Belg* 2007;107:570-1.
- 4- Gumus M, Gumus H, Budak H, Teke M. Breast cyst hydatid: a case report. *Ann Clin Cytol Pathol* 2016;2:1017.
- 5- Onder A, Kapan M, Girgin S, Akgül OL, Onder H, Akyuz Y. Isolated primary hydatid cyst of the breast: case report. *J Breast Health* 2012;8:152-4.
- 6- Gumus M, Yagmur Y, Gumus H, Kapan M, Onder A, Boyuk A. Primary hydatid disease of diaphragm with subcutaneous extension. *J Infect Dev Ctries* 2011;5:599-602.
- 7- Dagli AF, Ozercan MR, Kocakoc E. Hydatid cyst of the breast mimicking inflammatory carcinoma and mastitis. *J Ultrasound Med* 2006;25:1353-6.
- 8- Temiz A, Albayrak Y, Akalp SO, Yalcin A, Albayrak A. Breast Recurrent Hydatid Cyst Disease. *Chirurgia* 2017;112:482-5.
- 9- Kumar A, Kumar A, Gaurav K, Chandra G, Tiwary AK, Bhagat S, Sarawgi M. A rare case of isolated hydatid cyst of breast. *Int J Surg Case Rep* 2015;7C:115-8.
- 10- Cakir M, Balasar M, Kucukkartallar T et al. Management of Extra-Hepatopulmonary Hydatid Cysts (157 cases). *Turkiye Parazitoloj Derg* 2016;40:72-6.