

Case Report



A gossypiboma masquerading as a mesenteric cyst

Hilmi Bozkurt¹, Betül Öğüt²

1. Haseki Research and Education Hospital, Istanbul, Turkey

2. Pathology Department, Gazi University Faculty of Medicine, Ankara, Turkey

Correspondence: Hilmi Bozkurt (hilmibozkurt27@gmail.com)

Abstract

Gossypiboma refers to foreign bodies left inside the body during surgery, such as sponges and gauze. These foreign bodies represent a significant cause of morbidity and mortality.

A 57-year-old female presented to us with right upper abdominal pain. Her past history was non-contributory except for an open cholecystectomy 20 years previously. A physical examination revealed tenderness to palpation on the right of the abdomen, while the remaining examination was normal. An abdominal computed tomography (CT) and magnetic resonance imaging (MRI) scan revealed a well-defined calcified mass of 5 cm that was compatible with a mesenteric cyst. During surgery, the mass was found to be adherent to the mesocolon and to have invaded the colon wall. A right hemicolectomy and ileotransverse anastomosis was performed. The pathological mass was considered to be a gossypiboma that had been left behind during the earlier cholecystectomy. The body's reaction to the foreign body was seen to extend beyond the lamina propria and muscularis propria.

Gossypiboma is an undesired and life-threatening but preventable surgical complication. This condition may present with non-specific findings and a clinical scenario that mimics various disorders, even after many years. A diagnosis of gossypiboma should be kept in mind for patients with a history of previous operations and undergoing surgery due to the suspicion of a mesenteric cyst.

Key Words; Gossypiboma, mesenteric cyst, foreign body, cholecystectomy

Introduction

The gossypiboma in the present case was not recognised by the body's defence system and would have continued to exist in a fugitive manner if the patient had not undergone surgery for a suspected mesenteric cyst 20 years later^{1,2}. Gossypiboma (gossypium [cotton], oma [tumour/growth]) refers to foreign bodies left inside the abdomen during surgery (e.g., sponges and gauze), and represents a significant cause of morbidity and mortality². Although symptoms usually present 3–12 weeks after surgery, and serious complications, such as intraabdominal abscesses, may emerge in the early postoperative period, a gossypiboma may remain asymptomatic for years only to be detected incidentally as a pseudotumor. Here, we present a case that involves the invasion of a gossypiboma into the ascending colon.

Case report

A 57-year-old female patient presented to us with right upper abdominal pain. She had an uneventful history of surgery except for an open cholecystectomy 20 years previously. A physical examination revealed tenderness to palpation on the right of the abdomen, while the remaining examination was normal. An abdominal computed tomography (CT) revealed a well-defined calcified mass of 5 cm that was compatible with a mesenteric cyst (Figure 1). In addition, an abdominal magnetic resonance imaging (MRI) also showed a well-defined bilobulated mass of 5 cm that was also compatible with a mesenteric cyst (Figure 1). The patient was taken to the operating room with a presumptive diagnosis of a mesenteric cyst. An open surgery was performed. During the operation, the mass was found to be adherent to the mesocolon and to have invaded the ascending colon wall. A right hemicolectomy and ileotransverse anastomosis were performed.

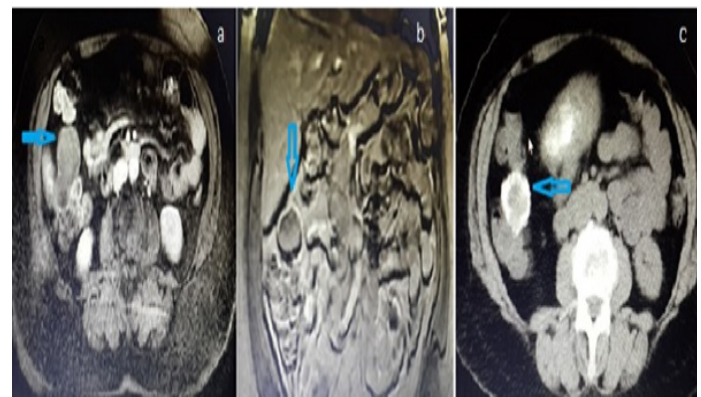


Figure 1: Mesenteric cyst imaging

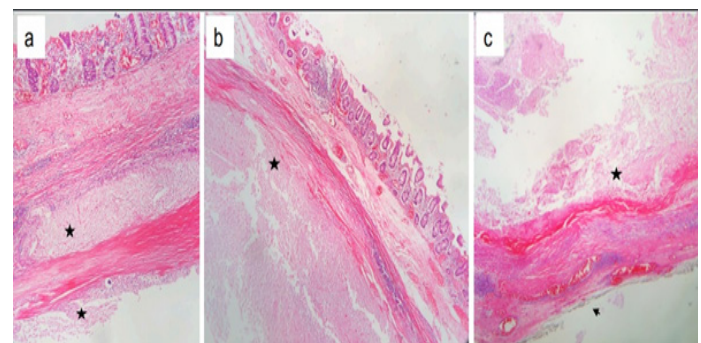


Figure 2: Foreign body pathological image

Upon macroscopic examination, the colonic mucosa was intact. When the colon wall was cut, a piece of surgical sponge was exposed. There was no tumour tissue or inflammatory disease. Samples were taken for histology and the lymph nodes were dissected. These samples were embedded in 10% paraffin wax, cut to 4- μ m slices, and underwent standard haematoxylin and eosin (H&E) staining. After routine histopathological assessment, samples were

examined microscopically. In the microscopic examination, the colon mucosa was found to be autolytic due to a fixation artifact. Despite this artifact, there was no evidence that was suggestive of a tumour or inflammatory infiltrate. Surgical sponge material was evident as “ghost fibres” upon microscopic examination. The pathological mass was considered to be a gossypiboma that had been left behind during the previous cholecystectomy. The reaction to the foreign body was seen to extend over the lamina propria and muscularis propria (Figure 2). The patient was discharged without complications on the fifth postoperative day. Postoperative colonoscopy was also performed but failed to find any evidence of inflammatory disease.

Discussion

Gossypibomas are rare in daily clinical practice. Although the actual incidence is not known, the reported incidences among all surgical interventions and intraabdominal operations are one per 100–3000 and one per 1000–1500, respectively^{3,4}.

Intra-abdominal foreign bodies are most commonly seen after caesarean and cholecystectomy operations. In a literature review, Modrzejewski et al.⁶ identified 10 cases of foreign bodies that had migrated to the colon. Among these cases, four occurred after open cholecystectomy surgery and three occurred after a caesarean birth. Due to their anatomical locations, foreign bodies usually migrate to the ascending and transverse colon after a cholecystectomy, and to the rectum and sigmoid colon after a caesarean operation. The present case had undergone an open cholecystectomy and the foreign body had invaded the ascending colon. The incidence of gossypiboma after cholecystectomies has fallen since laparoscopic operations have become the optimum form of treatment. As the associated symptoms are non-specific and imaging modalities provide inadequate information in most cases, it may be difficult to diagnose most patients with gossypiboma⁶. Occasionally, a combination of the patient's medical history and a physical examination may readily lead to diagnosis. Non-specific gastrointestinal symptoms and permanent surgical wound infections after surgery, and the finding of a palpable mass in the abdomen, should raise suspicions of a gossypiboma⁷. The most obvious indicator of a gossypiboma is the presence of curved or banded radio-opaque lines of textile material on a plain radiograph. Ultrasound (US) generally shows a cystic structure and a strong acoustic shadow, although such findings are frequently misinterpreted due to the rare occurrence of gossypibomas⁸. CTs show a well-defined cystic lesion with a hyperdense internal structure, marked wall calcifications, and a spongiform pattern with air bubbles⁹. MRI when accompanied by an injection of intravenous contrast material can reveal a peripheral wall and a heterogenous signal pattern in T1-weighted sections due to fluid and protein contents¹⁰. In the present case, the previous operation had taken place 20 years previously. There were no pathological findings on a plain radiograph as the use of radio-opaque sponges was rare at that time. As the CT and MRI findings were compatible with a mesenteric cyst, surgery was planned accordingly. Several risk factors have been reported for gossypiboma, including emergency surgery, high body mass index (BMI), intraoperative bleeding, unplanned or unanticipated changes in surgical procedures, prolonged operation time, inexperienced surgical personnel, incorrect sponge counts, a change of shift, or a large number of personnel in the surgical team^{11,12}. As with many

other disorders, prevention is the most effective means of treatment¹³; consequently, only sponges with radio-opaque marks should be used during a laparotomy. A careful count of surgical items before and after a procedure is of paramount importance, and a comprehensive exploration of the surgical field before closure is essential. If there is any doubt in the count of surgical items, the surgical field should be carefully reviewed, and a plain radiograph should be taken¹⁴. Gossypiboma is an undesired and life-threatening but preventable surgical complication. This condition may present with non-specific findings and clinical pictures that mimic various disorders, even after many years. A diagnosis of gossypiboma should be kept in mind in patients with a history of previous surgery and those undergoing surgery with suspicion of a mesenteric cyst.

Conflict of interest

None

Funding

None

Ethics

Informed consent was provided by the patient.

References

- Baert L, De Coninck S, Baertsoen C, Lissens P, Djoa L. Giant peritoneal loose body: a case report and review of the literature. *Acta Gastroenterol Belg.* 2019;82(3):441-3.
- Rajagopal A, Martin J. Gossypiboma—“a surgeon's legacy”: report of a case and review of the literature. *Dis Colon Rectum.* 2002;45(1):119-20.
- Wan YL, Ko SF, Ng KK, Cheung YC, Lui KW, Wong HF. Role of CT-guided core needle biopsy in the diagnosis of a gossypiboma: case report. *Abdom Imaging.* 2004;29(6):713-5.
- Gawande AA, Studdert DM, Orav EJ, Brennan TA, Zinner MJ. Risk factors for retained instruments and sponges after surgery. *N Engl J Med.* 2003;348(3):229-35.
- Düx M, Ganten M, Lubienski A, Grenacher L. Retained surgical sponge with migration into the duodenum and persistent duodenal fistula. *Eur Radiol.* 2002;Suppl 3:S74-7.6. Modrzejewski A, Kiciak A, Sledz M, et al. Migration of a foreign body into the colon and its autonomous excretion. *Med Sci Monit.* 2011;17(3):CS34-8.
- Akbulut S, Arikanoglu Z, Yagmur Y, Basbug M. Gossypibomas mimicking a splenic hydatid cyst and ileal tumor: A case report and literature review. *J Gastrointest Surg.* 2011;15(11):2101-7.
- Sozutek A, Colak T, Reyhan E, Turkmenoglu O, Akpınar E. Intra-abdominal gossypiboma revisited: Various clinical presentations and treatments of this potential complication. *Indian J Surg.* 2015;77(Suppl 3):1295-300.9. Chau WK, Lai KH, Lo KJ. Sonographic findings of intraabdominal foreign bodies due to retained gauze. *Gastrointest Radiol.* 1984;9(1):61-3.
- Patil KK, Patil SK, Gorad KP, Panchal AH, Arora SS, Gautam RP. Intraluminal migration of surgical sponge: gossypiboma. *Saudi J Gastroenterol.* 2010;16(3):221-2.
- Lata I, Kapoor D, Sahu S. Gossypiboma, a rare cause of acute abdomen: A case report and review of literature. *Int J Crit Illn Inj Sci.* 2011;1(2):157-60.
- Moffatt-Bruce SD, Cook CH, Steinberg SM, Stawicki SP. Risk factors for retained surgical items: a meta-analysis and proposed risk stratification system. *J Surg Res.* 2014;190(2):429-36.

13. Stawicki SP, Cook CH, Anderson HL 3rd, et al. Natural history of retained surgical items supports the need for team training, early recognition, and prompt retrieval. *Am J Surg.* 2014;208(1):65-72.
14. Ray S, Das K. Gossypiboma presented as abdominal lump seven years after open cholecystectomy. *J Surg Case Rep.* 2011;2011(8):2.
15. Oran E, Yetkin G, Aygün N, Celayir F, Uludağ M. Intraabdominal gossypiboma: Report of two cases. *Turk J Surg.* 2018;34(1):77-9.
-