

## Case Report



# Grisel syndrome presenting as hemiplegia in a patient with multifocal *staphylococcal* sepsis

Vincent L Mkochi<sup>1</sup>, Nyengo Mkandawire<sup>2</sup>

1. Assistant lecturer and Postgraduate Trainee in Trauma and Orthopaedics, College of Medicine, University of Malawi
2. Consultant Trauma and Orthopaedic Surgeon; Dean of Faculty of Medicine, College of Medicine, University of Malawi

Date Received: 28-Oct-2017  
Revision Received: 19-Nov-2017  
Date Accepted: 08-Dec-2017

Correspondence:  
Nyengo Mkandawire  
(Nmkandawire@medcol.mw)

<https://dx.doi.org/10.4314/mmj.v30i2.13>

## Abstract

### Introduction

Grisel syndrome is a non-traumatic rotary subluxation of C1 on C2 (atlantoaxial subluxation). It is a rare condition predominantly described in paediatric population with previous history of upper respiratory infections or otolaryngeal procedures. The diagnosis is established by the association of clinical and radiologic findings<sup>4,6</sup>.

We report a case of 15-year old boy with Grisel syndrome accompanying multifocal sepsis (pericarditis, septic polyarthritis, pneumonia and pharyngitis), treated surgically – occipital cervical fusion using struts of iliac crest tri-cortical graft wired to the occiput and C3 and C4.

### Objective

To describe a case of non-traumatic atlantoaxial rotary subluxation (Grisel syndrome) and to review clinical and radiologic aspects, pathophysiology, and treatment of this rare condition, which if left untreated can lead to catastrophic outcomes. Authors are trying to demonstrate the significance of early intervention for improved outcomes, and that physicians should examine patients with multifocal sepsis thoroughly so as not to miss foci of infection and have high index of suspicion of the syndrome in patients that present with neck swelling, and develop torticollis and neurological deficit.

### Methods

This is a case presentation of a 15-year-old boy who presented with an acute history of neck swelling, shortness of breath, orthopnoea, pericardial effusion, right hip and knee swelling. He later developed torticollis and left sided hemiplegia. On admission, he was septicemic. There was no history of head or neck trauma. Cervical spine radiograph showed increased atlantodental index (ADI) and prevertebral soft tissue swelling. Consent was sought from guardian and patient to use images and case notes for submission for publication.

### Results

The patient was treated with analgesia, drainage of pericardial effusion and intravenous antibiotics. The right knee sepsis was noted on admission and drained on the day pericardial drain was inserted, while the right hip was missed – only to be noted 59 days later with limb length discrepancy. The C1/C2 subluxation was noted 17 days after admission. Reduction was done soon after diagnosis and maintained with a halo-thoracic immobilizer. A week later, he underwent posterior occipital cervical fusion. The hemiplegia resolved fully.

### Conclusions

Multifocal staphylococcal septicemia can present with unusual foci of infection, which may be missed especially if the patient is very sick. Grisel syndrome with an associated left hemiplegia and septic arthritis of the right hip were diagnosed late in this case. Grisel syndrome patients might end up with catastrophic outcomes if left untreated or mis-diagnosed, but if prompt treatment is initiated, full functional recovery is achievable.

## Introduction

Grisel syndrome is a non-traumatic rotary subluxation of C1 on C2 (atlantoaxial subluxation). It was first described by Bell in 1830 as a consequence of a syphilitic ulceration of the pharynx, but has since assumed the name of Grisel, a French otolaryngologist who described a similar syndrome in patients with prior history of pharyngitis in 1930<sup>1</sup>. It is a rare condition predominantly described in paediatric population with previous history of upper respiratory infections or otolaryngeal procedures<sup>1,2,3</sup>. The diagnosis is established by the association of clinical and radiologic findings<sup>4,6</sup>.

In this case report, we present a paediatric patient with Grisel syndrome accompanying multifocal sepsis (pericarditis, septic polyarthritis, pneumonia and pharyngitis). The significance of early diagnosis and having high index of suspicion is discussed in this case report in view of current literature.

## Case Presentation

A 15-year-old boy was referred from a district hospital with a 2-week history of fever cough, shortness of breath, swollen legs and non-traumatic swelling of the neck. At the referring hospital, he was treated with antibiotics (crystalline penicillin) and furosemide for suspected pericardial effusion picked up on chest X-ray. He was then transferred to our tertiary hospital for further management.

On admission at the tertiary hospital, he weighed 36 Kilograms. He was afebrile with a temperature of 36.7 degrees Celsius, had swollen neck and anterior chest, left sterno-clavicular joint swelling, muffled heart sounds, raised jugular venous pressure, and lung crepitations. He had no neurological symptoms until 17 days-post admission when he developed left hemiplegia with motor power ranging from 1-3 out of 5, using Medical Research Council (MRC) scale, in all muscle groups on the affected side and he was

also noted to have torticollis.

**Investigation findings**

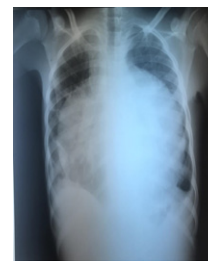His hemoglobin was 5.4g/dl; White cell count was 9.9 x10<sup>3</sup> per microliter with no differential indicated; malaria test was negative, ESR was not done; liver function test showed low albumin level (2.78 normal laboratory range 3.50- 5.00) but other parameters were normal; renal function tests were normal (Creatinine 0.8, range 0.1 -1.4, urea 17 (10-50). Blood culture had significant growth of *Staphylococcus aureus* with antibiotic sensitivity test showing sensitivity to Chloramphenicol, Cloxacillin, Cotrimazole, Erythromycin, Gentamicin, and Tetracycline.

Chest x-ray (fig. 1) showed enlarged cardiac silhouette. X-rays of antero-posterior pelvis revealed features suggestive of septic hip; of note, the same hip was dislocated and this was noted 59 days post admission (fig. 4). Clinically, he had septic right knee but initial x-rays were not suggestive as shown in figure 5. Cervical x-ray (fig. 6), taken after signs of neurological deficit, showed enlarged prevertebral soft tissues, C1/C2 subluxation with a massively increased ADI. He had echocardiography on which it was concluded he had pericardial effusion with internal strands and left ventricular hypertrophy.

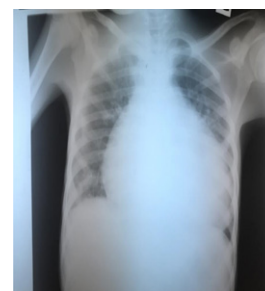
He was initially administered ceftriaxone 2 grams intravenous once daily, Praziquantel 1200milligrams per os stat, Metronidazole 250 milligrams tds, Frusemide 60 milligrams bid at least 10 days, morphine 7 millilitres per os 4 hourly and prednisolone 70 milligrams per os od that was later switched to Dexamethasone 4milligrams intravenous tds. After blood culture, results showed *S. aureus* which was sensitive to Cloxacillin, Gentamycin Cotrimazole, Erythromycin, Gentamicin, and Tetracycline. He was commenced on Flucloxacillin 2 grams intravenous QID and Gentamycin 180 milligrams od for 15 days. This was in accordance with the Malawi standard treatment guidelines which recommend that an antibiotic should be administered for at least 14 days in severe infection<sup>7</sup>. Pericardiocentesis was initially done, drained frank pus and later a pericardial drain was left in situ (fig.2 and fig. 3, showing chest x-rays post pericardial effusion drainage). Pus from pericardiocentesis was sent for microscopy culture and sensitivity but sample got lost. Of note, after pericardiocentesis and drain insertion, he was admitted in ICU for observation for a day. In total, 800 millimeters of pus was drained from pericardial effusion. He was also started on anti-tuberculosis chemotherapy empirically, which was stopped 10 days after pus came negative of Acid Fast Bacilli and blood culture grew *Staphylococcus aureus*. Neck Halo traction was applied in ICU where he was admitted for 5 days after development of torticollis, and left hemiplegia. The traction led to improved neurology. C1/ C2 subluxation was managed definitively by application of a Halo–thoracic immobilizer and posterior occipital cervical fusion. The initial plan was to do a posterior C1/C2 fusion. However, intra-operatively, he was noted to have a deficient or eroded posterior part of C1 which could not be used for fixation. The plan was then changed to occipital cervical fusion using struts of iliac crest tri-cortical graft wired to the occiput and C3 and C4. The Halo was maintained for 3 months until bone union was noted and stability confirmed on doing dynamic flexion extension maneuver (fig. 8 and fig. 9).

In view of polyarthritis, right knee and middle metacarpal phalangeal (MCP) joint on right hand were noted early on admission but the child was too sick to be taken in for arthrotomy. Knee and Metacarpal phalangeal joints were drained in same sitting as drainage of left sternoclavicular abscess and pericardial drain insertion. Hip septic arthritis was missed and noted 59 days post admission. Physiotherapists noted true lower limb length discrepancy (LLD) of 4 centimeters, right shorter than left. A pelvic x-ray confirmed a resolved septic arthritis and hip dislocation as a complication from missed septic arthritis (fig. 4). Dislocation was accepted; he was given a shoe-raise to compensate for LLD and girdle stone procedure to be done later.

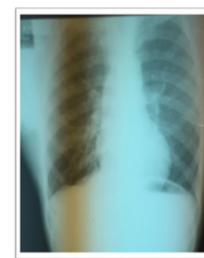The patient's condition improved from being bed-bound to attaining normal neurology, full ambulation without shortness of breath on exertion, and with normal respiratory and cardiovascular examination. The improvement was after high protein diet (fortified peanut butter, chiponde in Chichewa), dressings of sacral pressure sores, physiotherapy, antibiotics and surgery (pericardial drain, arthrotomy, cervical spine fusion). He weighed 35 kilograms on the day of discharge denoting that nutritional status had remarkably improved as compared to 24 kilograms which he weighed in the course of illness. The patient was discharged 5 months post admission at tertiary hospital.



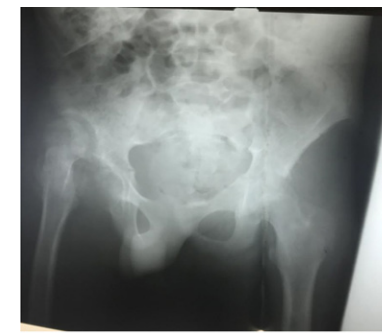**Fig. 1: Chest X-ray on admission showing massively enlarged cardiac shadow, suggestive of pericardial effusion**



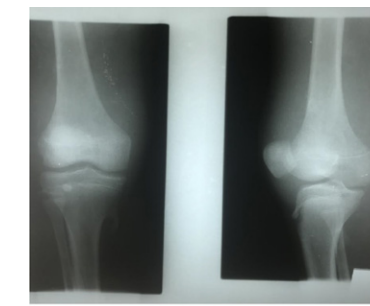
**Fig. 2: Check x-ray of chest post pericardiocentesis and drain insertion**



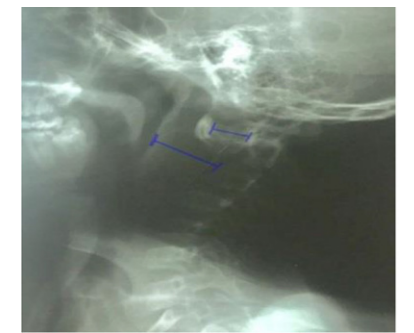**Fig. 3: Check Chest x-ray a week before discharge showing a resolved pericardial effusion which was in keeping with clinical picture**



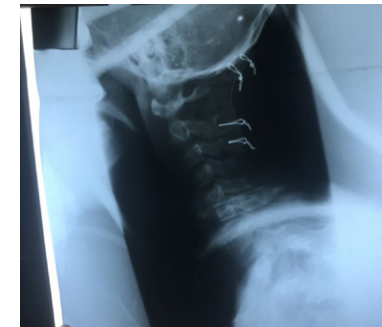**Fig. 4: AP pelvis showing right hip joint dislocation on side of missed septic hip.**



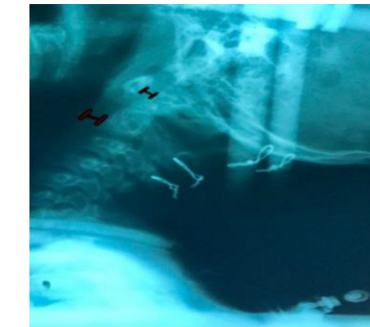
**Fig. 5: Knee x-ray: pre-arthrotomy knee x-ray. No signs of septic arthritis noted on x-ray**



**Fig. 6: Lateral c- spine showing C1 on C2 subluxation; ADI is more than 6mm and massive prevertebral soft tissue swelling]**



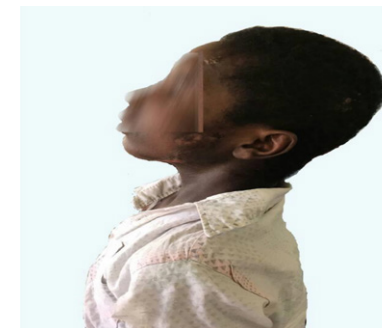**Fig. 7: Lateral C spine xray immediately post-op; normal alignment and normal ADI with some residual prevertebral soft tissue swelling**



**Fig. 8: Stress view of lateral c spine taken while patient was in full extension as tolerated after loosening halo. This gave an impression of stable spine. ADI is within normal range (<2mm) and prevertebral tissue swelling has subsided.**



**Fig. 9: Lateral C-spine stress view, taken when patient was in full flexion as tolerated after loosening halo – further assessment of C spine stability**



**Fig. 10: Neck extension after halo removal**



**Fig. 11: Neck flexion after halo removal**

**Discussion**

Grisel syndrome refers only to non-traumatic atlantoaxial subluxation. It is a rare complication of a head or neck infection or an otolaryngological procedure, including tonsillectomy, adenoidectomy, mastoidectomy, and choanal atresia repair<sup>2</sup>. Epidemiologically, it primarily affects the paediatric population, with no gender predilection, and only rare cases involving adults have been reported<sup>2</sup>. Congenital conditions that predispose to ligamentous laxity such as Down and Marfan syndromes present an increased risk of atlantoaxial subluxation<sup>1,2,3,10</sup>. Kawasaki disease is a very frequent acute febrile vasculitis of childhood that has also been related to Grisel syndrome<sup>1,2,3,10</sup>.

Karkos et al conducted a systematic review of 71 articles published between 1950 and 2006, which included 96 patients with C1–C2 subluxation with no history of previous trauma. Of these, 48% had a recent history of infection

mostly affecting the upper airways and 40% were in the postoperative period after head and neck procedures<sup>9,10,11</sup>. The Karkos et al review demonstrates how rare the condition is. Patients typically present with a painful torticollis, possible history of fever, and other non-specific signs of infection, and history otolaryngology procedure e.g. tonsillectomy<sup>1</sup>. On physical examination, significant muscle spasm is evident, and patients typically have a fixed torticollis. A positive Sudeck's sign is commonly observed<sup>1,5</sup>.

Our patient, had a positive history of fever, neck swelling and pain, eventually developed torticollis with associated left hemiplegia. He also had right hip and ipsilateral knee and ankle joint sepsis and septic pericardial effusion. He grew *Staphylococcus aureus* on blood culture. In view of Cervical radiological findings (increased ADI and prevertebral soft tissue swelling) pointing towards retropharyngeal abscess. The clinical picture of multifocal sepsis, with associated torticollis and neurological deficit and positive cervical x-ray



findings (fig. 6) made the diagnosis of Grisel syndrome most likely.

Blood cultures are mostly negative, since patients usually present with focal retropharyngeal infection, and an ESR is often elevated<sup>2</sup>. Unfortunately, in this case, ESR was not done. Due to the child being too sick on presentation, hip septic arthritis was missed. Still, it begs a question of being vigilant in clinical assessment of the patient especially in a case where multifocal sepsis is a picture of presentation.

Since its first description more than 100 years ago, the pathophysiology of Grisel syndrome is still a subject of debate; several hypotheses have been suggested. George Pazos et al in their case report came up with two hit hypothesis. The first “hit” is a pre-existing cervical ligamentous laxity seen in the paediatric population at baseline, whereas the second “hit” is caused by inflammatory mediators carried to the cervical muscles by the pharyngovertebral plexus, inducing spasm and subsequent subluxation (Refer to fig. 12 illustrating venous drainage of nasopharynx)<sup>1,8</sup>.

Another theory proposed by Tedesco et al suggests that cervical lymphadenitis caused by a nasopharyngeal infection may lead to irritative spastic contraction of sub-occipital and paravertebral muscles, causing torticollis<sup>11</sup>.

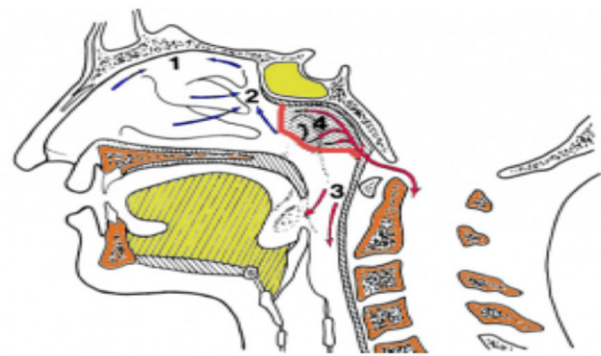


Fig. 12: Number 4 illustrates Pharyngovertebral venous plexus drainage area<sup>8</sup>

Although the majority of patients with Grisel syndrome recover without lasting functional or neurologic deficit, there is the potential for severe, even catastrophic, consequences if patients are misdiagnosed or mistreated<sup>1</sup>.

Despite lack of documented prevalence or incidence of Grisel syndrome in our hospital, there are cases of children who present with retropharyngeal abscess (as a focal infection or in presence of other foci of infection). This should alert our clinicians that Grisel syndrome is a possible sequella as proposed by George Pazos et al’s two hit hypothesis. There is no consensus algorithm on treatment of Grisel syndrome cases. Fielding et al came up with classification that helps with assessing prognosis and also guide in the treatment plan<sup>12</sup>.

One treatment protocol was proposed by Wetzel and La Rocca which was based on the classification of Fielding and Hawkins<sup>12</sup>. According to this protocol: Conservative treatment for type 1 is a soft collar, for type 2 a rigid collar, and a halo-vest for type 3 lesions. For type 4 lesions, they recommend surgical treatment<sup>11,12</sup>. This however poses controversy as far as type 3 pathology is concerned. In type 1 and 2, the transverse and alar ligament is intact; hence it is

managed conservatively as opposed to type 3 and 4 where transverse ligament is disrupted, which warrants stabilization through fusion.

Table 1: The Fielding classification of rotary subluxation 1

Type	Features
Type 1	Rotatory fixation with no anterior displacement, with odontoid acting as the pivot point
Type 2	Rotatory fixation with anterior displacement of 3-5 mm, one lateral articular process acting as pivot
Type 3	Rotatory fixation with anterior displacement of >5 mm
Type 4	Rotatory fixation with posterior displacement

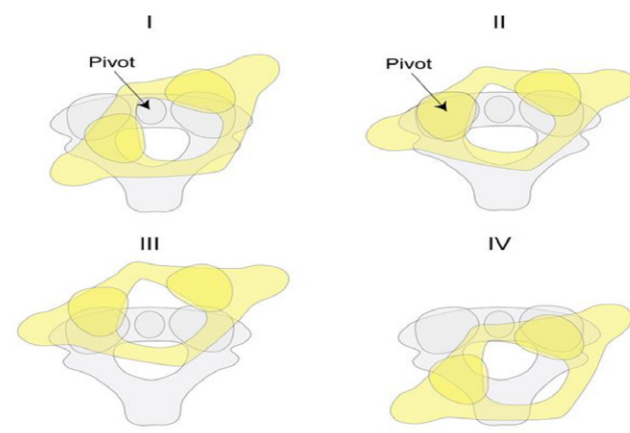


Fig. 13: Diagrammatic presentation of fielding classification (Case courtesy of Dr Behrang Amini , Radiopaedia.org, rID: 42320)

Table 2: Treatment options for stages of Grisel syndrome

Fielding classification	Treatment plan
Type 1	1. bed rest, 2. antibiotics, 3. relaxants, 4. soft immobilization
Type 2	1. rest, 2. antibiotics, 3. relaxants, 4. spinal traction (halter) when appropriate. 5. Philadelphia collar for 4 weeks
Type 3, 4	1. Antibiotics 2. Relaxants 3. halo immobilization,

Our patient was type 3 using Fielding classification. Halter traction was applied awaiting him to be fit for surgery. Later (5 days on Halter traction), halo was applied and had occipital cervical fusion and not C1/C2 fusion because, intra-operatively, he was noted to have a deficient posterior element of C1.

**Conclusion**

Grisel syndrome is a rare condition that can be found in

a variety of clinical settings as pointed out earlier; cases reported so far have been seen by the ear, nose and throat team, neurosurgeons and orthopedic surgeons. Every clinician, especially in fields where the condition has previously been described, should be familiar with the clinical picture, epidemiology and management of the cases. Grisel syndrome patients might end up with catastrophic outcomes if left untreated or mis-diagnosed but if prompt treatment is initiated, full functional recovery is achievable.

**References**

- A.P. Battiata, G. Pazos. Grisel’s syndrome: The two-hit hypothesis case report and literature review Ear Nose Throat J. 83 (8) (2004), pp. 553-555. <http://dx.doi.org/10.1155/2016/6486271>
- Münevver Serdaroğlu Beyazal, Duygu Demirok, Erhan Çapkin, Haydar USUL, Mehmet Tosun, Ahmet Sari. Grisel’s Syndrome-Case. Turk J Rheumatol;26(3): 243-247 doi:10.5152/tjr.2011.038
- Fernández Cornejo V J, Martínez-Lage J F, Piqueras C, Gelabert A, Poza M. Inflammatory atlanto-axial subluxation (Grisel’s syndrome) in children: clinical diagnosis and management. Childs Nerv Syst. 2003;19(5–6):342–347.doi: 10.1007/s00381-003-0749-6
- Alécio C. E. S. Barcelos, Gustavo C. Patriota, Arlindo Ugulino Netto. Nontraumatic Atlantoaxial Rotatory Subluxation: Grisel Syndrome. Case Report and Literature Review. Global Spine J. 2014; 4(3): 179–186. doi: 10.1055/s-0033-1363936
- Tania Cellucci, Shirley ML Tse. Case 2: A pain in the Paediatr Child Health. 2012 May; 17(5): 247, 249-250. <http://doi.org/10.1093/pch/17.5.247a>

- Ismi O, Ozalp H, Hamzaoglu V, Bucioğlu H, Vayısoglu Y, Gorur K.Grisel’s syndrome accompanying a submandibular abscess. Braz J Otorhinolaryngol.. 2016 ;441-444. DOI: 10.1016/j.bjorl.2016.07.004
- MoH, 2009, Malawi Standard Treatment Guidelines, Fourth Edition. Available at [apps.who.int/medicinedocs/documents/s18801en/s18801en.pdf](http://apps.who.int/medicinedocs/documents/s18801en/s18801en.pdf)
- Professor Balasubramanian Thiagarajan. Grisel Syndrome; A Review. ENT SCHOLAR April 5, Laryngology, 2013. .
- Karkos PD, Benton J, Leong SC, Mushi E, Sivaji N, Assimakopoulos DA. Grisel’s syndrome in otolaryngology: a systematic review. Int J Pediatr Otorhinolaryngol 2007;71(12):1823–1827. DOI: 10.1016/j.ijporl.2007.07.002
- Alécio C. E. S. Barcelos, Gustavo C. Patriota, Arlindo Ugulino Netto. Nontraumatic Atlantoaxial Rotatory Subluxation: Grisel Syndrome. Case Report and Literature Review. Global Spine J 2014;4:179–186. doi:10.1055/s-0033-1363936
- Alqroom RY, Jeszenszky DJ, Michalitsis GS, Franke J. Non-traumatic Atlanto-axial Rotatory Subluxation- Grisel’s Syndrome Case Report and Literature Review. J Spine 2016, 5:3. doi:10.4172/2165-7939.1000312
- Wetzel F T, La Rocca H. Grisel’s syndrome. Clin Orthop Relat Res. 1989;(240):141–152.