
SHORT REPORTS

Anaesthesia for conjoined twins

PM Fenton, RF Ligowe

The oxyhaemoglobin saturation of a set of conjoined twins was measured before and during supplementary oxygen administration and inhalation anaesthesia to assess the extent to which oxygen given to one twin could maintain oxygenation in the other before separation. The process of anaesthesia revealed that although some oxygenated blood could cross over from one twin to the other, as measured at the finger by pulse oximetry, it was not adequate to support life after the cessation of respiration.

A pair of vaginally delivered conjoined female twins was presented for surgical separation at age 1 day. One twin had an abdominal defect with a large gastroschisis below the conjoined area. This conjoined area extended from the xiphisternum to a point where a common umbilical cord entered both abdomens. General, cardiac and respiratory examination was normal. The combined weight was 3.6 kg. There was no bony fusion between the twins and they could be manipulated easily to gain access to each airway.

Because of the presumed partial common circulation, it was considered possible that induction of anaesthesia and oxygenation might be maintained in both twins (until the moment of separation) by anaesthetising only one.

A pulse oximeter (Ohmeda Biox 3740 with neonatal finger probe) had recently become available at the hospital and could be used to measure the state of oxygenation from moment to moment.

The pulse oximeter was connected to the finger of Twin 1 (without the gastroschisis) breathing room air. The oxyhaemoglobin saturation (SaO_2) stabilised at 90 - 92% during quiet, undisturbed breathing. Similar values for Twin 2 were 91 - 93%.

Leaving the probe on Twin 2, oxygen was then given to Twin 1 via a face mask using a paediatric draw-over patient system consisting of a paediatric "Ambu" bag and "Paedivalve" drawing oxygen-enriched air through a halothane vaporiser. Oxygen was supplied from an electric oxygen concentrator which can give 2 litres of 95% oxygen per minute. This apparatus has been described¹

After 3 minutes the SaO_2 of Twin 2 improved to values between 96 - 98%. While holding the mask and "Paedivalve" in place, but disconnecting the oxygen supply (so that room air was drawn into the lungs) the SaO_2 returned to previous levels. The same procedure carried out with the twins changed around produced similar results. Oxygen was re-applied to Twin 1, and halothane was added to induce anaesthesia. The SaO_2 of Twin 2 once again rose, though 96% was the highest value reached.

Twin 1 reached the stage of surgical anaesthesia after 4 minutes while Twin 2 became only drowsy and still reacted to a stimulus. An intravenous infusion was set up on Twin 1 and atropine 0.1 mg was given. There was no significant change in the heart rate of either twin. Suxamethonium 10 mg. was given and twin 1 was intubated with a 2.5 mm endotracheal tube. Intermittent positive pressure ventilation was started with air, oxygen and halothane as before.

The pulse oximeter, still giving readings from Twin 2, then started to show desaturation and cyanosis in this twin was also observed. Evidently, the suxamethonium had paralysed Twin 2, but oxygenation was insufficient for this twin. A second, similar, anaesthetic patient system was ready and twin 2's lungs were inflated using a face mask, after which the SaO_2 returned to normal. However, the degree of paralysis and depth of anaesthesia in Twin 2 did not allow intubation. Twin 2 was given inhalation induction using another draw-over vaporiser, connected to the same oxygen source, and then intubated under deep halothane anaesthesia. With difficulty, a second intravenous infusion was started on Twin 2.

Anaesthesia now proceeded with two anaesthetists separately monitoring the twins which were eventually physically separated. At operation, it was found that the two livers were joined over a consid-

Queen Elizabeth Central Hospital, Blantyre
PM Fenton, RF Ligowe

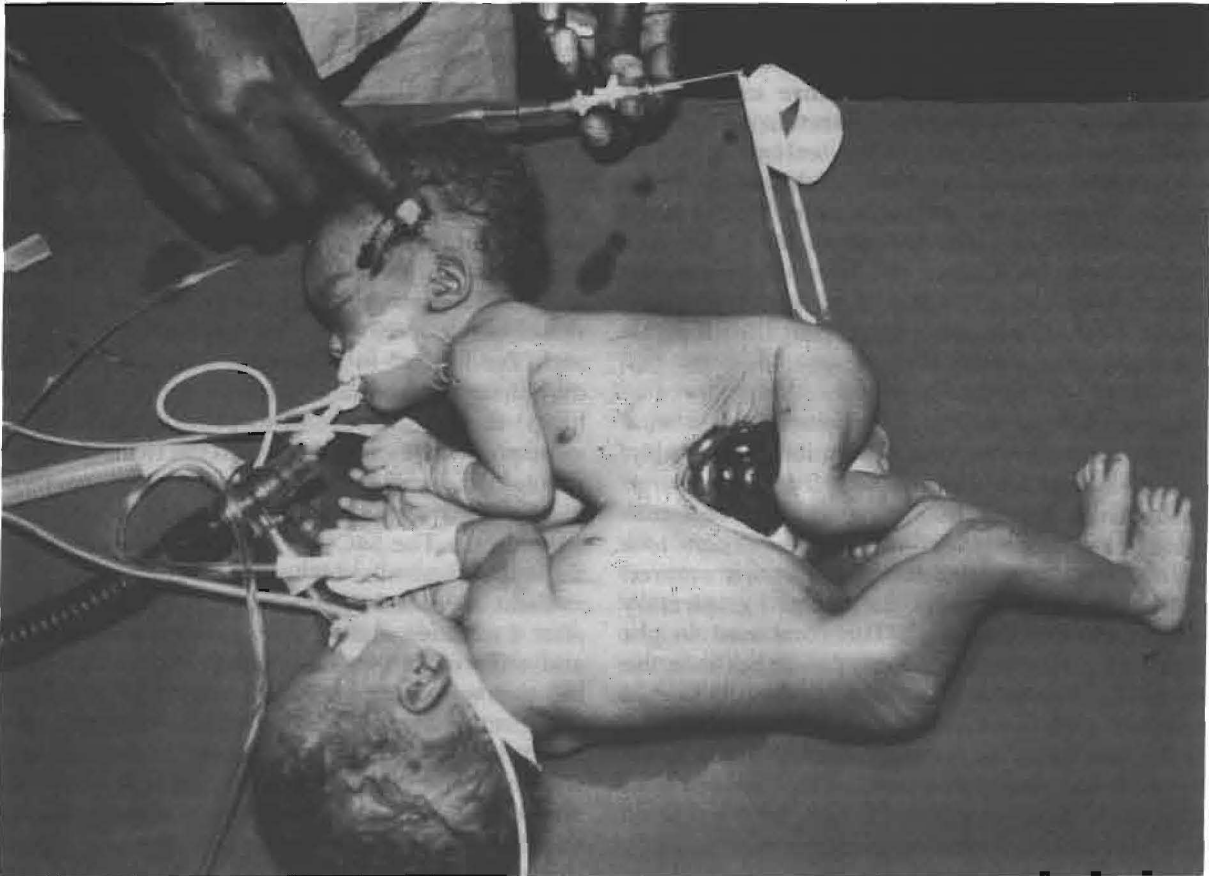
Correspondence to:
Dr. P.M. Fenton
Department of Anaesthesia
Queen Elizabeth Central Hospital
P.O. Box 95
Blantyre
Malawi

erable area. The gastroschisis could not be closed and was temporarily covered with a plastic bag. Recovery and extubation was uneventful, though unfortunately both twins died a few days later.

DISCUSSION

Anaesthesia for conjoined twins has been described². The associated anaesthetic problems reported

tions within the liver involving the ductus venosus. All these vessels, plus the foramen ovale, would have to have remained patent after birth. Blood flowing in this way would give a preferential oxygenation of the upper part of the body, including the fingers. The relative systemic arterial blood pressures of each twin were not measured but it seems likely that the fully anaesthetized twin would have



are: delay in the onset of anaesthesia due to a common circulation, difficult intubation and the need for two anaesthetic circuits and two anaesthetists. The partial common circulation of many of these rare cases means also that drug and fluid therapy (and blood loss) are shared until separation.

In the case reported above it appeared before giving anaesthesia that there was a significant common circulation since oxygen therapy given to one twin improved the oxygen saturation of the other. The anatomy of the umbilical vessels was not elucidated in the difficult operative circumstances, but possibilities are that the umbilical arteries were connected in some way with the umbilical veins, causing oxygenated blood from the left sided circulation of one twin to reach the right atrium of the other (and vice versa), and that there were connec-

a lower blood pressure than her drowsy, hypoxic sister, thereby making the transfer of significant amounts oxygenated arterial blood from the former to the latter less likely.

In the event, perhaps not surprisingly, the volume of shared arterial blood was insufficient to maintain adequate oxygenation in the second twin when the oxygenation of the pulmonary circulation in this twin ceased due to muscular paralysis.

Acknowledgement

The authors acknowledge with thanks the advice and support of Dr. E.J. van Hasselt who performed the surgical separation of the twins.

References:

1. Fenton P.M. The Malawi Anaesthetic Machine. *Anaesthesia* 1989;44:498-503.
2. Tovey R.M, et al. *Anaesthesia* 1979;34:178.