

## ii. Diarrhoea in a traveller

Stephany P<sup>1</sup>, Le Guern AS<sup>2</sup>, Buffet PA<sup>1</sup>

<sup>1</sup> Service de Pathologie Infectieuse et Tropicale. Centre Médical de l'Institut Pasteur, Paris, France.

<sup>2</sup> Laboratoire d'Analyses Médicales du Centre Médical de l'Institut Pasteur, Paris, France.

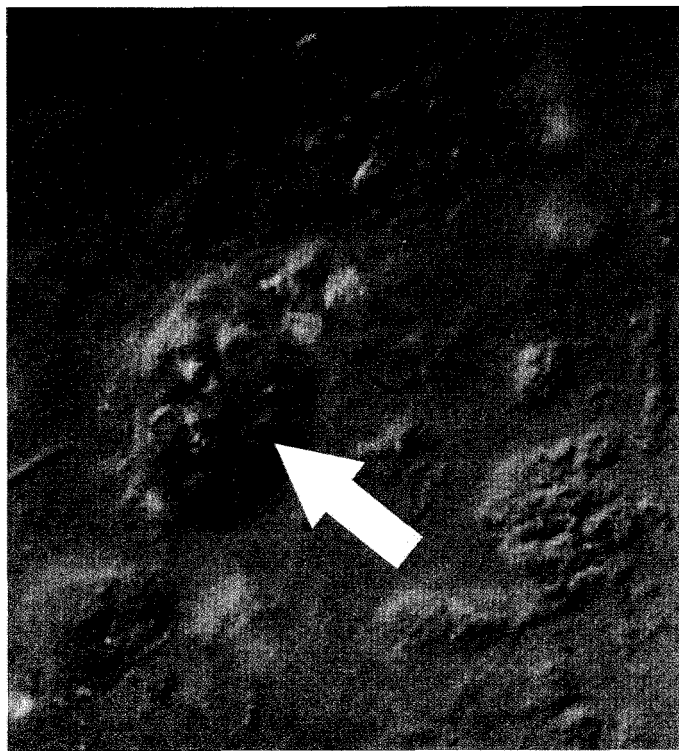
A 26 year-old woman presented with a 4 day-history of moderate diarrhoea with mucus, having returned two days before from a two weeks' stay in Senegal. There was no history of fever, vomiting, abdominal pain or blood in the stools. Her vaccination status included diphtheria-tetanus-polio, hepatitis A, typhoid fever and yellow fever. She had taken chloroquine and proguanil as chemoprophylaxis against malaria.

A drop of fresh unstained stool was examined by light microscopy. The objects in the picture (Figure – arrowed) were constantly changing shape.

*What is the diagnosis? What treatment would you give?*

<sup>1</sup> Service de Pathologie Infectieuse et Tropicale. Centre Médical de l'Institut Pasteur, Paris, France.

<sup>2</sup> Laboratoire d'Analyses Médicales du Centre Médical de l'Institut Pasteur, Paris, France.



## iii. Right flank pain and fever

Stephany P<sup>1</sup>, Aaron L<sup>2</sup>, Buffet PA<sup>1</sup>

<sup>1</sup> Service de Pathologie Infectieuse et Tropicale, Centre Médical de l'Institut Pasteur, Paris

<sup>2</sup> Service de Maladies Infectieuses et Tropicales, Hopital Necker, Paris

A 37 year-old engineer presented with a 5 day history of right lower thoracic pain and a 3 day history of high fever (39°-40°C) and shivering. The pain was increased by deep inspiration and during walking. The symptoms had started two days after returning from a one month stay in Ivory Coast, without chemoprophylaxis against malaria.

There was no diarrhoea and no dyspnoea. A blood test done two days before had shown a negative blood smear for malaria parasites, leucocytosis of 13 400/mm<sup>3</sup> (78 % neutrophils), and a raised C- reactive protein (306 mg/l). The medical history revealed an episode of blood-stained diarrhea on return from Ivory Coast eight months before, which he had self-treated with one tablet of 500 mg metronidazole.

Clinical examination showed fever of 38°C, decreased air entry on auscultation of the right lower lung field and pain on palpation and percussion of the right upper quadrant of the abdomen, without hepatomegaly. The rest of the clinical examination was normal.

A chest X-ray was normal. An abdominal ultrasound examination was done (Figure)

*What is the likely diagnosis? What would you do for this patient?*

For discussion see page 55

