

Ankylosing spondylitis in a Malawian.

Mkandawire, N.C.

Abstract

I report a case of ankylosing spondylitis in a Malawian patient. I believe this is the first reported case of ankylosing spondylitis in a Malawian. Ankylosing spondylitis is rare in black Africans when compared with the Caucasian population. The clinical features of this disease are also different in these different racial groups. I will present a brief clinical history and a review of ankylosing spondylitis with special reference to the black African.

Case

Mr D.M. Date of Birth 27th June 1938

A 63 year old man presented to QECH In July 2001 complaining of back and neck pain associated with loss of range of motion in the whole of his spine and hips rapidly getting worse since January 2001. He had not been able to walk since December 2000. He had difficulty squatting on a pit latrine and with perineal hygiene due to loss of motion in the hips.

The history of his illness dates back to 1988 when he first noticed pain and stiffness in his cervical spine. By 1989 pain and stiffness had progressed to involve the thoracic and lumbar spine forcing him to quit his job as a clerk in the civil service. Between 1989 and 1998 his symptoms were quiescent. Towards the end of 1998 the back symptoms relapsed and he also had severe pain and limitation of range of motion in the shoulder, hip and knee joints. He had difficulties with walking and started using a walking stick. Progressively loss of joint range of motion and fixed deformities in the spine, hips and, to a lesser extent, knees resulted in complete loss of ability to walk by December 2000.

He has no significant past medical, family, and social history. On examination he had complete loss of range of motion of the cervical, dorsal and lumbar spine. He had limitation of chest wall expansion. He could stand but both his hips and knees were in a flexed position (fig 1a and 1b).

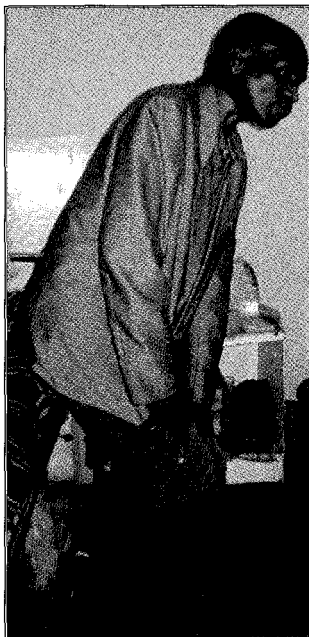


fig 1a



fig 1b

Standing posture showing fixed flexion deformities of the hips and knees.

Both his hips were ankylosed at 70 degrees of flexion and 0 degrees of abduction / adduction (fig 2).

Fig 2


Supine position showing maximum amount of hip extension possible. Hips were ankylosed at 70 degrees flexion and neutral abduction / adduction.



He had partial loss of range of motion in the shoulders with the right one more involved than the left one. The left shoulder had about 50% of normal range of motion preserved, whereas the right was estimated as having 30% of normal range of motion preserved (fig 3).

Fig 3

Showing functional range of motion possible at the shoulder joints.



His knees were in a flexed attitude with a range of motion from 45 to 130 degrees. He could not walk.

Full blood count, and erythrocyte sedimentation rate were normal. X-rays of the cervical, dorsal and lumbar spines showed classical features of a 'bamboo spine'. His sacroiliac and hip joints were ankylosed. The shoulders showed some degenerative changes. The knee x-rays were normal (see figs 4,5,6).

Fig 4

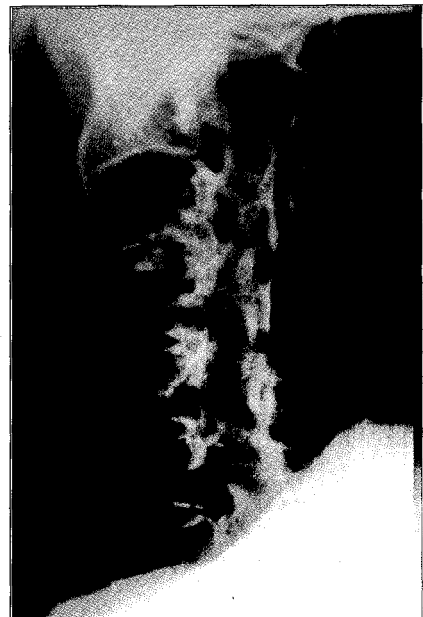

Fig 5

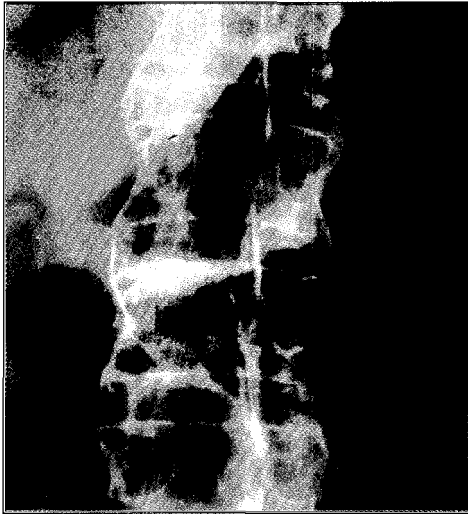
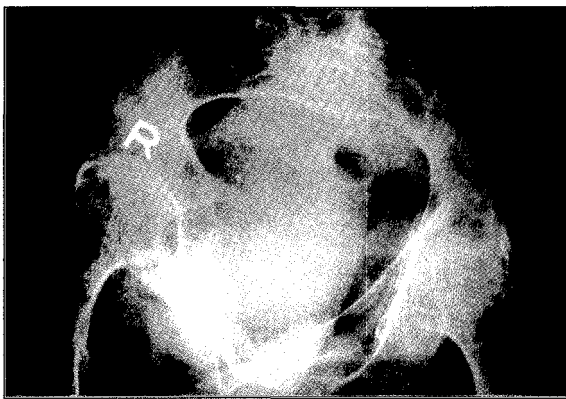

Fig 6



Management concentrated on pain relief with analgesics and anti inflammatory medications. Physiotherapy of the upper limbs and knees was done to maintain functional range of motion in these joints. The aim was to make him an independent wheelchair ambulatory patient.

Discussion

Ankylosing Spondylitis (AS) is a chronic inflammatory condition of unknown etiology. It is usually grouped together with other seronegative spondyloarthropathies such as Reiter's syndrome, psoriatic arthritis, arthritis of inflammatory bowel disease and undifferentiated spondyloarthropathies. It presents as an inflammatory polyarthritis principally affecting the vertebral column, sacroiliac joints and large peripheral joints such as the hips, shoulders and rarely the knees.

In the Caucasian population, the prevalence rate of AS is estimated at between 67.7 and 197 per 100,000 people. The incidence of AS in Caucasians is estimated at 1 to 2: 2000. The male to female ratio is 5:1. This compares with a male to female ratio of 1:3 in rheumatoid arthritis. There is a strong association of AS with the class I antigen HLA-B27, which is present in 80% to 98% of affected white patients compared with only 8% of the general population. HLA B27 has twenty different alleles (subtypes) numbered one to twenty. Subtype number five HLA B27*05 is the allele which is most clearly and consistently associated with ankylosing spondylitis and spondyloarthropathies (1).

AS is very rare in black Africans and no prevalence rates could be found in the literature. In the few cases of AS reported in black Africans, HLA B27 is rarely an associated finding. In seventeen cases of ankylosing spondylitis reported in Central and Southern

Africa, HLA B27 was present in only one patient (2). In sub Sahara Africa, the prevalence of HLA B27 in the general population is thought to be between 3% and 6%. These estimates are from research in Senegal and Gambia (3).

In the Gambia studies no case of ankylosing spondylitis was reported upon screening the HLA B27 positive population i.e. an HLA B27 positive black African has a much lower chance of having ankylosing spondylitis compared to a HLA B27 positive Caucasian. It may be postulated that there is presence of some non HLA B27 protective factor reducing the prevalence of ankylosing spondylitis in the black African population (3). Alternatively the HLA B27 subtype present in black Africans is not associated with ankylosing spondylitis. This rarity of HLA B27 and the lack of correlation between HLA B27 and spondyloarthropathies may explain the rarity of spondyloarthropathies in black Africans. Consequently, HLA B27 cannot be used as a diagnostic aid in spondyloarthropathies in African blacks (2).

Pathology

There is progressive ankylosis of the involved joints. In the spine, the apophyseal joints and costovertebral joints become fused. There is ossification of the intertebral discs, intervertebral ligaments, anterior longitudinal ligaments, and posterior longitudinal ligaments resulting in a rigid spine, the so called 'bamboo spine'. Involvement of the sacroiliac joints is usually present early in the disease process and results in ankylosing of these joints. In synovial joints there is synovitis with accumulation of inflammatory cells (lymphocytes, plasma cells and histiocytes). This is followed by villous Hyperplasia, formation of a pannus, and destruction of the articular cartilage and ankylosis of subchondral bone. Inflammatory induced joint destruction and soft tissue ossification result in ankylosis of the axial skeleton and large peripheral joints. Enthesopathy, which is inflammation at the insertion of tendons and ligaments into bone, is common and may be associated with the formation of bony spurs at these sites.

Clinical Features

The onset of the disease is usually between the ages of 16 to 30 years in the HLA B27 positive population. Age of onset is much older in the HLA B27 negative population and in Black Africans.

Patients may present with constitutional features as fatigue, weight loss and general malaise. Early morning stiffness, back pain and sacroiliitis are common early features. Chest pain may occur as a result of involvement of the costovertebral and costotransverse joints. There is progressive loss of range of motion of the spine and the chest cavity. Late in the disease, fixed spinal deformities such severe kyphosis may develop. In the lumbar spine kyphotic deformity may interfere with the patient's ability to see the horizon, and also causes compression of the abdominal viscera by the rib margin, compromising respiration, which is highly dependent on diaphragmatic excursion. In the cervical spine, kyphosis can progress to the point where the patient is unable to look forward because of a 'chin on chest deformity'. The hips and shoulders are the most commonly affected extra-axial joints and pain in these joints is the primary symptom in 15% of patients. Involvement of large peripheral joints such as hips and shoulders present with joint pains and loss of range of motion. Fixed deformities may develop late in the disease resulting in hip flexion and adduction contractures.

Extra articular involvement may result in anterior uveitis, iritis and iridocyclitis. Eye disease is the most common extra-articular manifestation of AS and occurs in 25% to 30% of Caucasian

patients. Rarely, the patient may have aortitis and myocarditis. In late stage progressive disease, the patient may develop amyloidosis, which can cause fatal renal failure.

Black Africans with ankylosing spondylitis commonly present with late onset disease after the age of fifty years. History of familial occurrence is rare in Africans and extra articular tissues are rarely involved. This pattern of presentation is similar to that seen in Caucasians with HLA B27 negative ankylosing spondylitis (2).

Differential Diagnoses

In the early phase of the disease, the differential of diagnosis of ankylosing spondylitis would include rheumatic diseases such as:

- Rheumatoid arthritis
- Reiter's syndrome
- Reactive arthritis secondary to gastrointestinal and genitourinary infections.

Other inflammatory condition such as psoriatic arthritis and gout are normally quite easily distinguished from ankylosing spondylitis.

In sub-Saharan Africa, the pandemic of HIV/AIDS has resulted in an increase in the incidence of 'HIV Related Arthropathies'. These primarily are reactive type arthritis or spondyloarthropathies other than ankylosing spondylitis. HIV/AIDS should therefore be considered in the sexually active age group presenting with rheumatic arthropathies (4).

Investigations

In the early phase of the disease routine investigation that may need to be done, depending on clinical presentation, may include:

- FBC
- ESR
- Rheumatoid factor
- HLA B27 (as discussed above this is not a useful diagnostic aid in black Africans suspected of having ankylosing spondylitis.)
- HIV

If reactive arthritis from gastrointestinal or genitourinary infection is suspected, appropriate investigation such as:

- Stool analysis
- Urinalysis
- Urethral swabs
- Vaginal swabs

may be necessary.

X-rays of the appropriate joints are important. Early sacroiliitis is seen as 'fuzziness' of the sacroiliac joint. Later frank obliteration of the sacroiliac joint signifies complete ankylosis. The vertebral column shows evidence of "squared off" vertebrae and bridging syndesmophytes due to calcification of the intervertebral discs, anterior longitudinal ligaments, posterior longitudinal ligaments and intervertebral ligaments. This gives the classical appearance of 'bamboo spine'.

Large joints such as hips may show evidence of joint destruction and, in late stages, frank ankylosis of the joint.

Management

The principle aims of management are **pain relief** and **maintenance of joint range of motion and function**.

Pain relief is achieved by administration of analgesic and non-steroidal anti-inflammatory drugs. Function and range of motion are maintained by adhering to a regime of physiotherapy and exercises. Analgesics and non-steroidal anti-inflammatory medication are crucial in maintenance of range of motion, function and adherence to exercise regimes. Physiotherapy and exercise regimes should include breathing exercises to maintain chest cavity expansion and posture training to avoid development of deformity such as spinal kyphosis.

In the case presented, DM had complete ankylosis of the hips with fixed flexion and adduction deformities resulting in loss of mobility and handicap with activities such as toileting. His entire spine is already completely ankylosed. The emphasis of management was pain relief with anti-inflammatory medications and physiotherapy to maintain upper limb range of motion. He has potential for independent wheel chair mobility if his upper limb function is maintained.

Surgery occasionally is indicated to correct fixed severe kyphotic deformities of the spine. In such cases, extension osteotomies of the spine are necessary to improve posture. Total joint replacement of the hips and shoulders may be indicated to relieve pain and restore function and range of motion. Joint replacements are best done before the major joints have become fully ankylosed. Because his hips are already fully ankylosed it is felt that joint replacements are relatively contraindicated.

Summary

- Ankylosing spondylitis is rare in black Africans. The incidence of HLA B27 is also rare in Black Africans and the association of HLA B27 and ankylosing spondylitis in black Africans is not strong.

- Clinical features of ankylosing spondylitis in Black Africans are similar to the pattern seen in Caucasians with HLA B27 negative ankylosing spondylitis.

- Early diagnosis and initiation of treatment with analgesics, non-steroidal anti-inflammatory medications and physiotherapy is important if joint range of motion and function are to be preserved. Results of joint surgery are maximised if operations are done before joints become ankylosed.

- Further investigations are needed to show the relationship of clinical features of ankylosing spondylitis and spondyloarthropathies and the different subtypes (alleles) of HLA B27 and their correlation with different racial populations and geographic regions of the World.

Mkandawire, N.C.

Dept. of Surgery, College of Medicine

Reference

1. Khan MA. Update: the twenty subtypes of HLA - B27 *Curr Opin Rheumatol* 2000 Jul; 12(4): 235 - 8
2. Miyajawa M, Oniankitan O, Khan MA. Spondyloarthropathies in sub-Saharan Africa. *Curr Opin Rheumatol* 2000 Jul; 12(4): 281 - 6
3. Brown MA, Jepson A, Young A, et. al. Ankylosing spondylitis in West Africans - evidence for a non-HLA - B27 protective effect. *Ann Rheum Dis* 1997 Jan; 56(1): 68 - 70
4. Adebajo A, Davis P. Rheumatic disease in African blacks. *Semin Arthritis Rheum* 1994 Oct; 24(2): 139 - 53