



Microbes and Infectious Diseases

Journal homepage: <https://mid.journals.ekb.eg/>

Original article

Role of special stains in identification of fungi in eumycetoma among Sudanese patients in Soba University Hospital

*Rawaa Adlan Elhady Ahmed*¹, *Alkhair Abd Almahmoud Idris*^{*2}, *Nadia Ibrahim Eldawi*³, *Ahmed Hassan Fahal*⁴

1- Medical Histopathology and Cytology Department, National University, Sudan.

2- Ahfad University for Women, Sudan

3- Department of Pathology, Faculty of Medicine, University of Khartoum, Sudan.

4- Department of Surgery, University of Khartoum, Sudan.

ARTICLE INFO

Article history:

Received 16 August 2021

Received in revised form 28 September 2021

Accepted 2 October 2021

Keywords:

Special stains

Fungi

Eumycetoma

Sudanese patients

Soba University Hospital

ABSTRACT

Background: Mycetoma is a unique neglected tropical disease caused by a substantial number of microorganisms of fungal or bacterial origins. Identification of the causative organism and the disease extension are the first steps in the management of the affected patients and predicting disease treatment outcome and prognosis. **Objectives.** To determine the role of special stain in identification of fungi in eumycetoma among Sudanese patients at Soba University Hospital. **Method:** This descriptive cross-sectional study was conducted of fifty-nine archival formalin fixed paraffin-embedded tissue blocks, four identical sections from each archival paraffin-embedded tissue block were obtained and stained with routine H&E and special stains {Periodic-Acid-Schiff (PAS) and Grocott-Gomori silver (GMS) and Gridley stain}, then the collected data was analyzed using SPSS version 23.0. **Results:** The use of special stains especially PAS and Grocott methenamine-silver (GMS) stain are of value (specific and sensitive) in identifying the fungal hyphae and yeast of eumycetoma. Mycetoma is more commonly reported in males than females; also mycetoma is most common in young adults (16–40 years old) and is uncommon in children. No significant relationship was demonstrated between diagnosis and variables (gender, age). Type I and II was the commonest type of the host tissue reaction encountered in this study. **Conclusion:** Results showed that GMS and PAS had the ability to stain both fungal hyphae and yeast in compare to Gridley's stain which had some limitations to stain fungal structures.

Introduction

Mycetoma is a chronic and progressive subcutaneous granulomatous infection characterized by painless swelling and tumefaction, draining sinus tracts, and purulent discharge. This discharge contains microbial sclerotic, or grains, which may be helpful in identifying the pathogen

[1]. This inflammatory disease may be caused by fungi or bacteria and is classified accordingly. The term “eumycetoma” is used to describe an infection caused by fungi, while an “actinomycetoma” is reserved for an infection caused by filamentous bacteria [2]. The first description of a case of

DOI: 10.21608/MID.2021.96355.1193

* Corresponding author: Alkhair Abd Almahmoud Idris

E-mail address: alkhair20@hotmail.com

mycetoma is usually attributed to Dr John Gill who reported “Madura foot” in a dispensary report of the Madras Medical Service of the British Army in India, in 1842 [3]. A subcutaneous mass and multiple sinuses draining pus, blood and fungal grains characterize the mycetoma lesion. Grains, also known as sclerotia, are aggregates of the fungal hyphae or the bacterial filaments, sometimes embedded in tough, cement-like material. The morphological characteristics and colour of the grains provides clues about the species of the agents [3].

Although mycetoma is found worldwide, it is endemic in tropical and subtropical countries [4-8]. The countries with the highest incidence of the disease are Sudan, Venezuela, Mexico, and India, but Sudan and Mexico have the highest number of cases reported [4-8].

Men are more likely to be affected than women, with the male to female ratio ranging from 3:1 to 5:1 [5,6].

Multiple diagnostic modalities are available and are an essential step in the proper evaluation of a patient. Accurate identification of the pathogen plays a vital role in the treatment plan as well as patient outcomes. Different laboratory-based diagnostic tools and techniques were developed over the years to determine and identify the causative agents. These include direct microscopy and cytological, histo-pathological, and immune-histochemical techniques in addition to the classical grain culture. More recently, various molecular-based techniques have joined the mycetoma diagnostic armamentarium. The available mycetoma diagnostic techniques are of various specificity and sensitivity rates. Most are invasive, time consuming, and operator dependent, and a combination of them is required to reach a diagnosis. In addition, they need a well-equipped laboratory and are therefore not field friendly.

Hematoxylin and eosin (H&E) is the stain for primary identification of the causative agent and the tissue reaction. Special stains usually follow for accurate identification of certain organisms and the cell components such as proteins, lipids, carbohydrates, and minerals that can be associated with the disease.

Three types of host tissue reaction against the organism were described and they are identical in all types of mycetoma [9]. In Type I tissue reaction, there is a zone of polymorphonuclear cells that surrounded the grains, sometimes the grains

were intermingled with neutrophils and in this instance the grains show cracking and fragmentation. Beyond the neutrophilic zone, there is granulation tissue containing macrophages, lymphocytes, plasma cells. The mononuclear cells increase in number towards the periphery of the lesion. The outermost zone of the lesion consists of fibrous tissue. In Type II tissue reaction, the neutrophils largely disappear and are replaced by macrophages and multinucleated giant cells. The latter engulf grain material. This consists largely of pigmented cement substance although hyphae are sometimes identified. Other inflammatory cells and histological changes are the same as in type I reaction. Type III reaction, is characterized by the formation of a well-organized epithelioid granuloma with Langhan’s type of giant cells. The center of the granuloma sometimes contains remnants of fungal material but in some no fungal elements could be identified. Inflammatory and histological changes are the same as described for both type I and II reactions [9].

Grains can be visualized with H&E staining and by special staining techniques, such as the Periodic-Acid-Schiff (PAS) and Grocott-Gomori silver staining. Actinomycetoma should also be investigated using Gram staining [2,10].

Also Gridley stain was used which is a modification of the Bauer technique in which a fewer number of reactive aldehyde groups remain intact to react with Schiff’s Solution. The result is less background staining and more highly defined fungi [10].

The accurate identification of mycetoma causative agents is considered the cornerstone for the initiation of appropriate therapy. Hence a rapid and accurate diagnostic tool to achieve the definitive species identification is considered a critical part in patient treatment and management. Although histopathological examination only takes 24-48 hours to identify the specific fungi compared to culture in which fungal organism may take weeks to grow if they grow at all, there are few studies regarding the role of special stain in diagnosis of mycetoma. Histopathological identification and differentiation between various etiological agents is of substantial importance as the treatment and prognosis for them are different.

This study aimed to determine utility of special stains in identification of fungi in eumycetoma.

Material and Methods

Study design

This was a descriptive cross-sectional study done to determine the utility of special stain in identification of fungi in eumycetoma. The study was conducted in Soba University Hospital in Khartoum state during the period from October 2020 to February 2021.

Study population

Fifty-nine Paraffin-embedded tissue blocks from eumycetoma patients were included in this study.

Study duration

This study was conducted during the period from October 2020 to February 2021.

Sample size

Fifty-nine archival formalin fixed paraffin-embedded (FFPE) tissue blocks.

Sample collection

Four identical sections from fifty-nine archival paraffin-embedded tissue block were stained with routine H&E and special stains (PAS, GMS and Gridley stain). Periodic-acid-Schiff and GMS were performed according to the method described by Bancroft and Stevens, (1982) [11]. While Gridley stain was performed according to the method described by Gridley and Amer, (1953) [12].

Laboratory precautions

Before the routine daily work, a great care in preparing the work surfaces and environment was taken. All surfaces and bench tops were thoroughly cleaned with 70% alcohol disinfectant. All instruments and glassware was thoroughly cleaned.

Quality control

High attention was given to the quality control from collection of paraffin embedded eumycetoma tissue blocks to the end of staining. Much care was given to the fixation and staining techniques. Every solution and staining batch were accurately prepared and tested before its applications.

Ethical consideration

Permission to carry out this research obtained from Research Board of Faculty of Medical Laboratory Sciences, National University.

Results

- Utility of special stain in identification of fungi in eumycetoma. Hematoxylin & eosin, PAS, GMS, and Gridley's stain were performed in the group of 59 cases of eumycetoma patients.
- **Figure 1** shows the distribution of the study cases according to gender, this reflects that the mycetoma was more commonly reported in males than females.
- **Table 1** shows the distribution of the study cases according to age group, this reflects that mycetoma can affect all age groups, but it occurs more commonly in young men aged between 20 and 40 years.
- **Table 2** shows the correlation between distribution of study sample according to gender and age.
- **Table 3** shows the staining reaction of special stains, in comparison between the three special stains we observed that GMS and PAS had the ability to stain both fungal hyphae and yeast, while Gridley's stain which had some limitations.
- **Figure 2** shows the distribution of study sample according to the host tissue reaction, Type I and II was the commonest type of reaction encountered in this study which represent 54.2%.
- **Figure 3** indicates the distribution of study samples according to diagnosis
- **Table 4** illustrates the correlation of diagnosis in relation to gender, age and host tissue reaction.

Table 1. Distribution of study sample according to age group.

Age groups	Number	Percent
Less than 20 years	8	13.5%
20-40 years	42	71.2%
More than 40 years	9	15.3%
Total	59	100%

Table 2. Correlation between distribution of study sample according to gender and according to age.

Variables		Gender		Total
		Male	Female	
Age groups	Less than 20 years	7	1	8
		87.50%	12.50%	100.00%
	20-40 years	31	11	42
		73.80%	26.20%	100.00%
	More than 40 years	5	4	9
		55.60%	44.40%	100.00%
Total		43	16	59
		72.90%	27.10%	100.00%

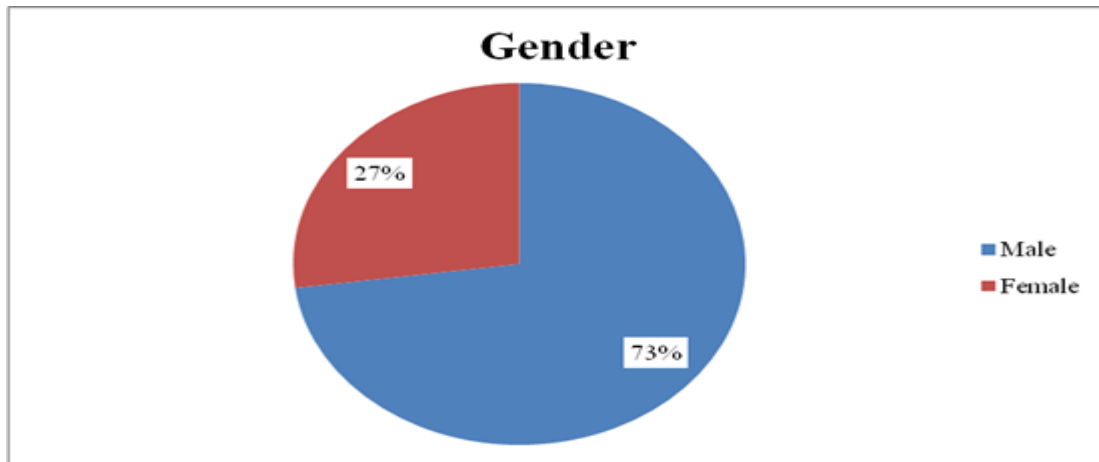
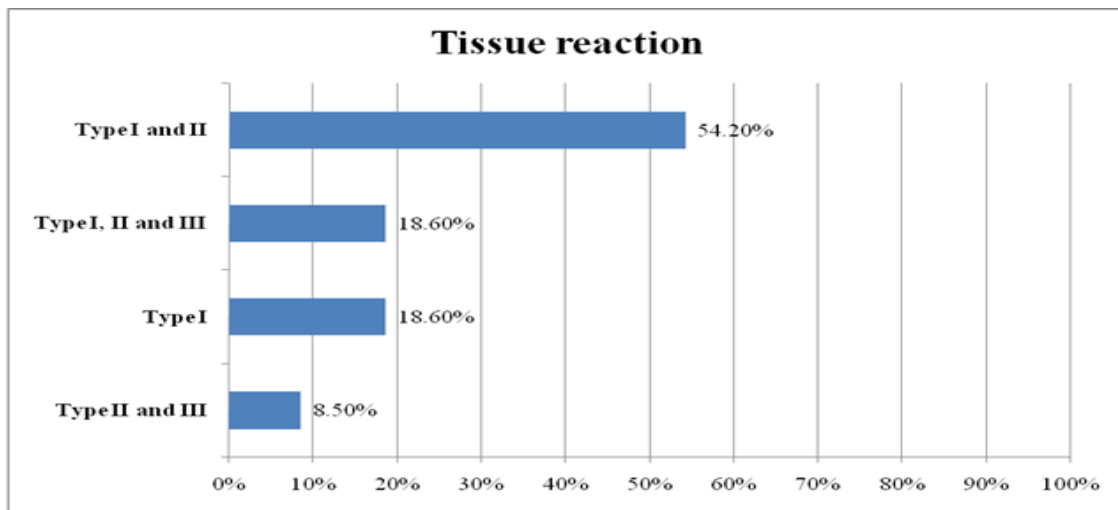
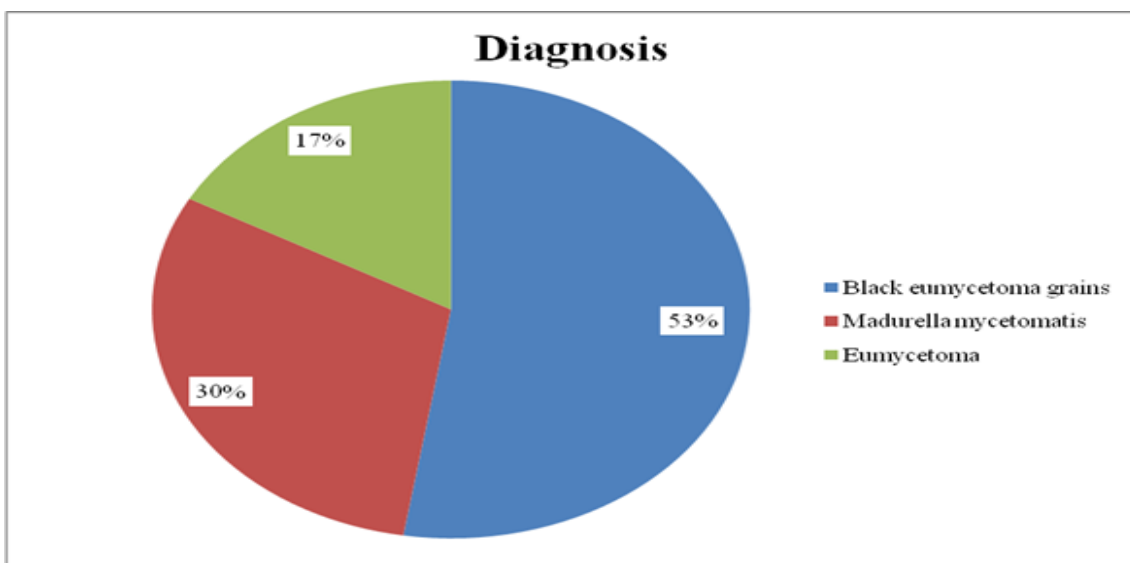
Table 3. The staining reaction of special stains.

Staining techniques	No reaction	Fungal hyphae	Fungal hyphae and yeast
PAS stain	2	4	53
	3.4%	6.8%	89.8%
GMS stain	2	0	57
	3.4%	0%	96.6%
Gridley stain	2	57	0
	3.4%	96.6%	0%
n=59			

Table 4. Correlation between diagnosis in relation to gender, age and host tissue reaction.

Variables		Diagnosis			Fisher's exact <i>p</i> value
		Black eumycetoma grains	Madurella mycetomatis	Eumycetoma	
Gender	Male	23	13	7	0.999*
		53.50%	30.20%	16.30%	
	Female	8	5	3	
		50.00%	31.30%	18.80%	
Age groups	Less than 20 years	5	2	1	0.975*
		62.50%	25.00%	12.50%	
	20-40 years	22	13	7	
		52.40%	31.00%	16.70%	
	More than 40 years	4	3	2	
		44.40%	33.30%	22.20%	
Tissue reaction	Type I	7	3	1	0.027**
		63.60%	27.30%	9.10%	
	Type I and II	21	6	5	
		65.60%	18.80%	15.60%	
	Type I, II and III	3	5	3	
		27.30%	45.50%	27.30%	
Type II and III	0	4	1		
	0.00%	80.00%	20.00%		

- ***p* value <0.05 that's considered as statistically significant.
- **p* value >0.05 that's considered as statistically insignificant.

Figure 1. Distribution of study sample according to gender.**Figure 2.** Distribution of study sample according to the host tissue reaction.**Figure 3.** Distribution of study samples according to diagnosis.

Discussion

Mycetoma, being a relatively painless condition, is often diagnosed at an advanced stage where permanent deformity of affected part has already occurred, so there is a need for correct diagnosis of mycetoma after clinical examination, assisted by histological and microbiological studies along with the use of special stains and hence proper treatment.

Fifty-nine (59) cases of previously diagnosed patients with eumycetoma were selected from the year of 2017 up to 2021. Forty-three of cases were males and the remaining 16 cases were females. The age groups of patients ranged from 9 years to 77 years. The most frequent age group affected by the disease was from 20 to 40 years which represent 71.2% of cases, while the other age group of less than 20 years represent 13.6%, and remaining age group of more than 40 years represent 15.3%. This findings showed agreement with study done by **Fahal et al.**, and **LópezMartínez et al.**, concluded that mycetoma is more commonly reported in males than females [3:1]. The condition is most common in young adults ([16–40 years old) and is uncommon in children [13,14].

In the present study, we assessed the utility of special stains (PAS, GMS, and Gridley's stain) in identification of fungi in eumycetoma patients; we observed that all these three special stains can stain the fungi with variations in color of stained background structure. PAS and GMS had stained both fungal hyphae and yeast very clear. While Gridley's stain had a limitation for identifying the fungal structures.

One advantage of GMS is that it produces better staining contrast in tissues sections, and detects even degenerated and dead fungi that may not be detected by PAS stain. This makes GMS a better, study conducted by **D'Hue et al.** concluded that GMS is superior to PAS for the diagnosis of onychomycosis, being both more sensitive and qualitatively better [15].

In the present study, a hypothetical relationship was tested between diagnosis and patient gender and age. No significant relationship was demonstrated between diagnosis and variables (gender, age) with *p* value 0.999 and 0.975 respectively that's considered as statistically insignificant. But there was significant relationship between diagnosis and the host tissue reaction with *p*.value 0.027 that's considered as statistically

significant. (No literature review found correlate these variables).

The study concluded that the use of special stains especially periodic acid Schiff's and Grocott methenamine-silver (GMS) stain are of value (specific and sensitive) in identifying the fungal hyphae and yeast of eumycetoma.

Acknowledgement

Great thanks for all members in Soba University Hospital (Khartoum) for their helping in collection of samples

Conflict of interest: None.

Funding :None.

References

- 1-**Ahmed AOA, Van de Sande WWJ, Ahmed F.** Management of mycetoma: major challenge in tropical mycoses with limited international recognition. *CurrB Opin Infect Dis* 2007;20(2):146–151.
- 2-**Fahal A, EL Sheikh M, EL Hassan AM, Abdel-Rahman ME.** Mycetoma in the Sudan: An Update from the Mycetoma Research Centre, University of Khartoum, Sudan. *PLoS Negl Trop Dis* 2015; 9(3): e0003679.
- 3-**Boiron P, Locci R, Goodfellow M, Gumaa SA, Isik K, Kim B, et al.** Nocardia, nocardiosis and mycetoma. *Med Mycol* 1998; 36: 26–37.
- 4-**Zijlstra EE, Van de Sande WWJ, Welsh O, Mahgoub ES, Goodfellow M, Fahal AH.** Mycetoma: a unique neglected tropical disease. *Lancet Infect Dis* 2016; 16:100–112.
- 5-**Bonifaz A, Tirado-Sánchez A, Calderón L, Saúl A, Araiza J, Hernández M, et al.** Mycetoma: Experience of 482 Cases in a Single Center in Mexico. *PLoS Negl Trop Dis* 2014;8: e3102.
- 6-**Lichon V, Khachemoune A.** Mycetoma: a review. *Am J Clin Dermatol* 2006; 7:315–321.
- 7-**Venkatswami S, Sankarasubramanian A, Subramanyam S.** The Madura Foot: Looking Deep. *Int J Low Extrem Wounds* 2012; 11:31–42.

- 8-**Welsh O, Al-Abdely HM, Salinas-Carmona MC and Fahal AH.** Mycetoma Medical Therapy. PLoSNegl Trop Dis 2014;8:e3218.
- 9-**Fahal AH, El Toum EA, El Hassan AM, Gumaa SA, Mahgoub ES.** Host tissue reaction to *Madurella mycetomatis*: New classification Myco. J Med Vet 1995; 33: 15-17.
- 10-**Thirumalachar MJ, Padhye AA.** Isolation of *Madurella mycetomi* from soil in India. Hindustan Antibiot Bull 1968; 10: 314–18.
- 11-**Bancroft JD, Stevens A.** Theory and practice of histological techniques (1982) Ed. 2
- 12-**Gridley MF, Amer J.** Clin Path 1953; 23:303
- 13-**Fahal AH, Sabaa AH.** Mycetoma in children in Sudan. Trans R Soc Trop Med Hyg 2010; 104:117-21.
- 14-**López Martínez R, Méndez Tovar LJ, Lavalle P, Welsh O, Saúl A, MacotellaRuíz E.** Epidemiology of mycetoma in Mexico: Study of 2105 cases. Gac Med Mex 1992;128:477-81.
- 15-**D’Hue Z, Perkins SM, Billings SD.** GMS is superior to PAS for diagnosis of onychomycosis. J CutanPathol 2008; 35: 745–747.

Elhady RA, Idris AA, Eldawi NA, Fahal AH. Role of special stains in identification of fungi in eumycetoma among Sudanese patients in Soba University Hospital. Microbes Infect Dis 2022; 3(1): 185-191.