

# Microbes and Infectious Diseases

Journal homepage: <https://mid.journals.ekb.eg/>

## Original article

# Cutaneous infections among human immunodeficiency virus (HIV) - infected patients in a single centre in Kuala Lumpur, Malaysia

Ahlam Muthanna\*, Adawiyah Jamil

Dermatology Department, Faculty of Medicine, The National University of Malaysia, Kuala Lumpur, Malaysia.

### ARTICLE INFO

#### Article history:

Received 5 April 2021

Received in revised form 2 May 2021

Accepted 5 May 2021

#### Keywords:

Human immunodeficiency virus  
Acquired immunodeficiency syndrome  
Skin  
Infection

### ABSTRACT

**Background:** Human immunodeficiency virus (HIV) infection is frequently associated with cutaneous infections. **Objective:** To determine the spectrum of dermatological infections among HIV positive patients, identify the causative microorganisms and CD4 count. **Methods:** This is a retrospective study conducted in a tertiary center. HIV-positive patients registered in 2013 to 2018 were identified from casemix database, those with suspected cutaneous infection were selected. Data was obtained from electronic and physical medical records. **Results:** A total of 27 patients were enrolled. Mean age was  $38.61 \pm 11$  years, 22(81.5%) were males and 5(18.5%) were females. Most patients 14(52%) developed more than one skin disease, there were a total of 46 diagnoses. The skin infections were fungal 11(24%), viral 4(8.7%) and bacterial 4(8.7%). Disseminated mycoses were mostly due to *Penicillium marneffe* 4(8.7%). Superficial fungal infections were due to *Fusarium sp.*, *Candida sp.* and *Trichosporum sp.* Cutaneous candidiasis constituted 3(6.47%). The average CD4 count in patients with fungal infections was 79 cells/mm<sup>3</sup>. Other skin diseases documented were adverse cutaneous drug reactions 8(17.4%) and pruritic papular eruption 5(11%). CD4 count was  $<200$  cell/mm<sup>3</sup> in 34(73.9%) of the dermatological illnesses encountered by the patients. **Conclusion:** Both disseminated and superficial fungal infections were common in our cohort. *Penicillium marneffe* caused majority of disseminated infections while superficial infections are due to moulds.

### Introduction

Dermatological diseases are common in HIV infection, more than 90% of patients develop skin diseases at any stage of the infection [1]. Skin diseases may appear early and are important to be recognized for early diagnosis of HIV [2]. Few skin diseases are exclusively related to HIV infection and

are often described as “HIV defining” and their appearance warrant HIV screening. These include Kaposi sarcoma (KS), eosinophilic folliculitis, oral candidiasis, oral hairy leukoplakia, herpes zoster, ulcerative herpes simplex, disseminated cryptococcosis and histoplasmosis [3,4]. Other non-

DOI: 10.21608/MID.2021.71180.1140

\* Corresponding author: Ahlam Muthanna

E-mail address: ahlammuthahar@hotmail.com

specific skin disorders such fungal and viral skin infections, and inflammatory skin disorders such as seborrhoeic dermatitis, lichen planus and prurigo are also common during HIV illness [5]. However, they display an atypical presentation, are more severe and resistant to treatment in HIV patients [6]. In addition, patients with HIV are more susceptible to develop adverse cutaneous drug reactions (ACDR) compared to general population [6].

The spectrum of dermatological profile among HIV positive patients varies between countries. The most common skin diseases reported in Malaysia were inflammatory diseases: generalized hyperpigmentation, pruritic papular eruption (PPE), xerosis and seborrheic dermatitis; followed by skin infections - mostly fungal infections [7,8]. In Iran, 67% of HIV patients developed non-infectious skin diseases and only 33% developed skin infections, mostly due to herpes [9]. Skin infections did not correlate with CD4 count [10]. In Pakistan, skin infections including oral candidiasis and herpes zoster accounted for 75.8% while non-infectious skin diseases especially xerosis accounted for 24.2% [5]. CD4 count was not correlated with the frequency of skin diseases. In India, skin infections accounted for 63.34%, mostly herpes zoster followed by dermatophytes, ACDR (20.66%) and inflammatory causes (16.66%)[10]. In a study in Spain, HIV patients developed skin infections, predominantly onychomycosis [11]. In Ethiopia, the following mucocutaneous disorders were seen in descending order: tongue papillary atrophy, oral hairy leukoplakia, herpes zoster, oral candidiasis, pruritic papular eruption (PPE), condylomata acuminata, and telogen effluvium [12].

Skin diseases in HIV infections tend to have atypical presentation, chronic and difficult to treat [5,6]. Early diagnosis and aggressive treatment reduce morbidity and disfigurement [2]. Therefore, it is important that clinicians are aware of the common presentation of skin infections in HIV infections and causative agents. Empirical treatment can be started immediately until laboratory results are ready.

### **Objective**

To determine the spectrum of dermatological infections among HIV positive patients in UKM Medical Center, identify the causative microorganisms and the CD4 count.

### **Methodology**

This is a retrospective study conducted on hospital-based HIV-positive patients who attended the Universiti Kebangsaan Malaysia Medical Center (UKMMC) in Kuala Lumpur, Malaysia, from 2013 to 2018. One hundred and fifty HIV-positive patients were identified from UKMMC Case mix Database. The electronic laboratory results (electronic) for each of the 150 patients were screened to identify patients suspected to have developed infections. This was done by searching for the results of skin biopsy culture, nail culture, skin scraping or skin swabs. Patients who were found to have undergone these investigations were included in the study. Out of the 150 patients screened, 27 patients were found to have undergone these tests. Ethical approval was then obtained to retrieve the 27 medical files from the Department of Health Information. The medical file in UKMMC (paper based) contains the clinical information about the patients' illness, including notes from outpatient clinics and wards. The 27 medical file of the 27 HIV patients were then screened meticulously to trace other dermatological diseases these patients have developed, whether infectious or non-infectious and these skin conditions were further added to the study.

### **Results**

#### **Sociodemographic distribution**

Twenty-seven patients were included in this study. The mean age of patients was  $38.61 \pm 11$  years. Majority were males, 22(81.5%), females accounted for 5(18.5%) of cases. There were 13(48.2%) Malays, Chinese 12(44.44%), Indians 1(3.7%) and other ethnicities 1(3.7%). Information on mode of transmission was only recorded in 8 patients (29.6%) with 5 cases reporting homosexual behavior compared to 3 heterosexual transmission.

#### **Skin presentation in relation to HIV duration, antiretroviral therapy (ART) and CD4 count**

The 27 patients developed 46 skin conditions. Majority of the skin conditions [34(74%)] either coincided with HIV diagnosis or developed in the first year after HIV diagnosis. Skin diseases appeared two to six years after HIV diagnosis in the remaining 12(26%). In relation to ART, 24(52%) of skin problems developed while on ART compared to 22(48%) not on ART. CD4 count was low in 34(73.9%) patients during manifestation of most dermatological illnesses. Very low CD4 count,  $< 50$  cell/mm<sup>3</sup> was seen in 19(41.3%) patients and low

CD4 count between 50-200 cell/mm<sup>3</sup> in 15(32.6%) patients. CD4 count > 200 cell/mm<sup>3</sup> was documented in 12(26.1%) (Figure 1).

#### Spectrum of cutaneous infections

Cutaneous infections constituted 19(41.3%) of the skin illnesses in our cohort. Skin infections identified were: fungal infections, viral infections and bacterial infections in subsequent order (Table 1). Fungal infections are common than viral and bacterial infections. Disseminated mycoses were slightly more encountered than superficial fungal infections. Skin and blood cultures isolated *Pencillium marneffe* in most patients. Clinically these patients presented with widespread, umbilicated papules and pustules over the face, trunk and limbs. Average CD4 count in these patients was very low, 57 cell/mm<sup>3</sup>.

Onychomycosis (*Fusarium sp* isolated) and cutaneous candidiasis (*Candida glabrata*, *Trichosporon sp* and *Candida parapsilosis* isolated) were the superficial fungal infections diagnosed in our study. The average CD4 count in patients with fungal infections was low, at 79 cells/mm<sup>3</sup>.

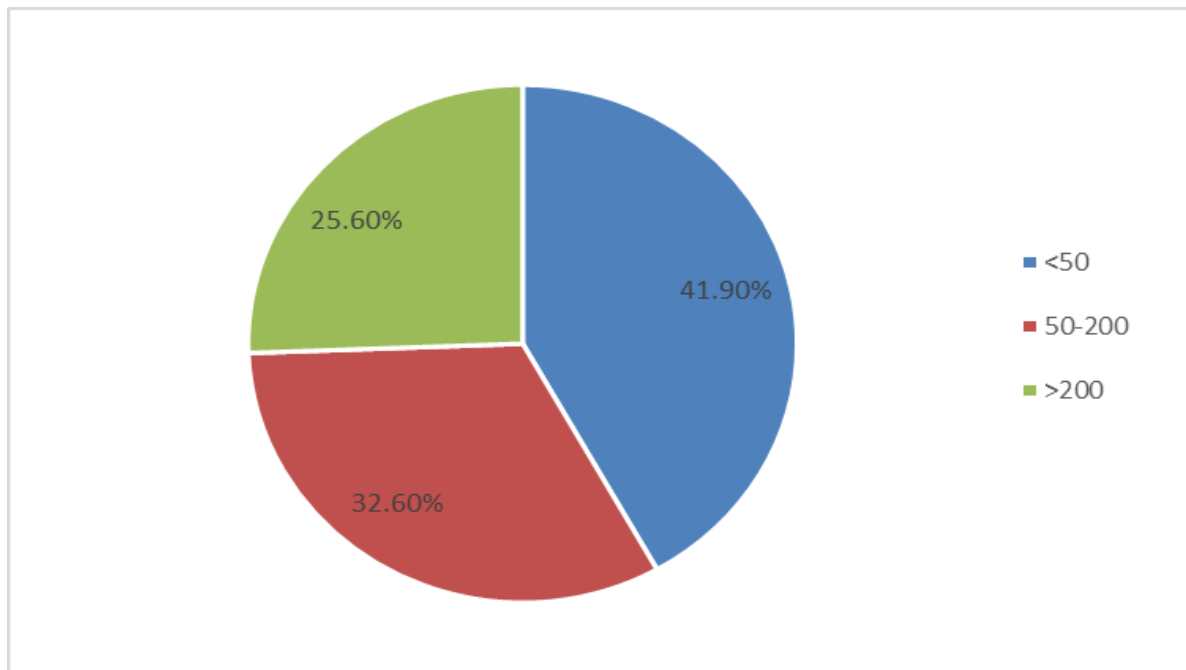
Viral infections/ reactivation contracted by the patients were: shingles, verruca vulgaris, herpes simplex and condylomata accuminata and average CD4 count was below 200 cell/mm<sup>3</sup> for all the cases. Bacterial infections was less encountered in our

cohort. Folliculites was the predominant bacterial infection in our cohort with *Staphylococcus aureus* identified as the causative agent in one patient only.

#### Other cutaneous diseases

Non-infectious skin diseases comprised 27(58.7%) in our study sample and were as follows in subsequent order: ACDR, PPE, endogenous eczema, KS, eosinophilic folliculitis, seborrheic dermatitis, prurigo nodularis and erythema annulare centrifugum (Table 1). Bactrim was the culprit drug in 4 patients while Nevirapre and Stocrin were the offending drug in only one patient each. Most of the drug reactions was in the form morbilliform rash while toxic epidermal necrolysis (TEN) and Steven Johnson syndrome (SJS) were encountered by very few patients. In contrast to skin infections, average CD4 count in patients with drug reactions was considerably higher, 275 cells/mm<sup>3</sup>. Patients with eczema also had a significantly high average CD4 count, >400 cells/mm<sup>3</sup>. PPE appeared as pruritic and excoriated papules which developed in 5 patients with average CD4 count of 162 cells/mm<sup>3</sup>. The three patients with KS were newly diagnosed with HIV infection and had very low CD4 count, a mean of 47 cell/mm<sup>3</sup>. Kaposi sarcoma was locally distributed in these patients: on the face in two patients and on the limbs and glans penis in another.

**Figure 1.** Distribution of CD4 count among the study population during manifestation of their skin diseases.



**Table 1.** Spectrum of cutaneous infections, other cutaneous diseases and CD4 count.

Skin diseases	N(%)	Average CD 4 count (cell/mm <sup>3</sup> )
I. Cutaneous infections		
<b>Fungal Infections</b>	11(24%)	79
Deep mycoses	6(13.04%)	
<i>Pencillium marneffe</i>	4(8.7%)	57
<i>Aspergillus niger and Rhodotorula</i>	1(2.17%)	391
<i>Histoplasma capsulatum</i>	1(2.17%)	13
Superficial mycoses	5(10.77%)	
Onychomycosis ( <i>Fusarium sp</i> )	2(4.3%)	299
Cutaneous candidiasis ( <i>Candida glabrata, trichosporum sp, Candida parapsilosis</i> )	3(6.47%)	108
<b>Viral Infections</b>	4(8.7%)	
Shingles	1(2.17%)	113
Verruca Vulgaris	1(2.17%)	
Herpes simplex	1(2.17%)	178
Condylomata accuminata	1(2.17%)	16
<b>Bacterial Infections</b>		
Folliculitis	4(8.7%)	141
II. Other cutaneous diseases		
<b>Drug Reactions</b>	8(17.4%)	275
Morbilliform rash	5(10.9%)	187
Steven Johnson Syndrome (SJS)	1(2.17%)	45
Toxic Epidermal Necrolysis (TEN)	1 (2.17%)	384
Erythema Multiforme	1 (2.17%)	482
<b>Pruritic papular eruption (PPE)</b>	5(10.9%)	162
<b>Eczema</b>	4(8.7%)	407
<b>Kaposi sarcoma</b>	3(6.5%)	47
<b>Eosinophilic folliculitis</b>	2(4.3%)	219
<b>Seborrheic dermatitis</b>	2(4.3%)	133
<b>Prurigo Nodularis</b>	2(4.3%)	26
<b>Erythema annulare centrifugum</b>	1(2.17%)	597
<b>Total</b>	46(100%)	

## Discussion

Skin diseases display a wide spectrum during HIV illness including infectious and non-infectious etiologies. It is very crucial that clinicians are aware of the commonest skin infections presented in HIV patients in their areas as this can aid in selecting the most appropriate empirical treatment. Studies on cutaneous infections in Malaysia are scarce and we identified only two studies [7,8]. The most common skin infection in our study was fungal infections. There is a strong

association between disseminated fungal infections and HIV, making the former a label for the latter, usually described as “HIV-defining” disease[13]. Consistent with another study from Malaysia [7], *P.marneffe* was the most frequently fungus isolated in disseminated infections. In 1990, **Supparatpinyo et al.** identified *P.marneffe* in 21 HIV infected patients in Thailand and suggested that *P.marneffe* must be added to the list of AIDS-defining illnesses that previously included *Cryptococcus neoformans*,

*Coccidioides immitis* and *Histoplasma capsulatum* [13]. Humans are exposed to *P.marneffe* either directly from soil especially during rainy season or indirectly from the bamboo rat, both are suggested to be the environmental reservoirs of *P.marneffe* in Asia [14].

Candidiasis and dermatophytosis are also common in HIV patients [2]. In our study, patients developed cutaneous candidiasis due to *Candida* sp mixed *Trichosporum* and *Candida* infections. In HIV patients, dermatophyte infections have unusual morphology and are less inflammatory with no central clearing and poorly defined margin. Onychomycosis are caused by *Candida* sp, dermatophytes and saprophytes. *Fusarium*, a saprophyte, commonly affects toenails. The immune status of the majority of patients in our study population was severely compromised reflected by the significantly low CD4 count in the majority of cases which is consistent with similar studies from Malaysia [7,8].

The most common non-cutaneous diseases documented in our study were ACDR and PPE. ACDR is more common in HIV patients than general population as patients become more susceptible to drug reactions as their immunity deteriorates [15]. Common culprit drugs are trimethoprim-sulfamethoxazole, sulfadiazine, trimethoprim-dapsone and aminopenicillins [15]. Likewise, trimethoprim-sulfamethoxazole was the most common offending drug among our patients and morbiliform rash the commonest ACDR presentation. Noticeably, the average CD4 count of patients with ACDR were more than 200 cell/mm<sup>3</sup>. Given the high susceptibility of HIV patients to ACDR, it is important to rationalize the prescription of antibiotics in these patients.

Pruritic papular eruption is very common in HIV patients and represents a hypersensitivity reaction to insect bites associated with low CD4 count [16,17]. Other common cutaneous disease commonly encountered in HIV patient are: seborrheic dermatitis, psoriasis and eosinophilic folliculitis. Seborrheic dermatitis is a common cause of erythroderma in HIV patients and is not associated with any CD4 levels, however it becomes severe, extensive and difficult to treat with lower CD4 count [6].

Kaposi sarcoma is an "HIV-defining" illness and is correlated to low CD4 count [18]. The low prevalence of KS in our study correlates very well with another study in Malaysia [8] and China

[17]. The prevalence of KS is low among HIV-infected population in Asia compared to western countries [19]. Kaposi sarcoma is the most common malignancy associated with HIV but is less encountered after the introduction of ART.

Our study has few limitations, being a retrospective study that was dependent on laboratory investigations and medical records to collect data, some infections that were clinically diagnosed and did not require investigations might have been missed. Our sample size was also small and so the results cannot be generalized. A population-based study are necessary to validate our findings about skin infections among HIV-infected population in the country.

### Conclusion

Most HIV-infected patients in our study had low CD4 count and were afflicted with a spectrum of skin diseases. Fungal infections was the most commonest infectious skin disorder while drug reactions was at the top list of non-infectious skin disorders in our study. Recognizing HIV-defining diseases is important to raise suspicion about HIV infection and predict the immune status. Antibiotics use should be cautiously prescribed in these patients.

**Conflict of interest:** No conflict of interest declared.

**Funding:** None.

### References

- 1-**Tschachler E, Bergstresser PR, Stingl G.** HIV-related skin diseases. *The Lancet* 1996 ;348(9028):659-663.
- 2-**Kurgis BS.** Skin manifestations of human immunodeficiency virus (HIV): Part 1. Infectious manifestations. *J Am Osteopath Assoc* 1993; 93(1): 223-.
- 3-**Kreuter A, Schugt I, Hartmann M, Rasokat H, Altmeyer P, Brockmeyer NH.** Dermatological diseases and signs of HIV infection. *European journal of medical research* 2002;7(2):57-62.
- 4-**Rajeev A, Fuller C.** Cutaneous manifestations of human immunodeficiency virus infection. *Dermatological Nursing* 2011;10(1):12-17.

- 5-**Azfar NA, Khan AR, Zia MA, Humayun A, Malik LM, Jahangir M.** Frequency of mucocutaneous manifestations in HIV positive Pakistani patients. *Journal of Pakistan Association of Dermatology* 2016;21(3):149-153.
- 6-**Zalla MJ, Su WD, FRANSWAY AF.** Dermatologic manifestations of human immunodeficiency virus infection. in *Mayo Clinic Proceedings*. 1992. Elsevier.
- 7-**Jing W.** A retrospective survey of mucocutaneous manifestations of HIV infection in Malaysia: analysis of 182 cases. *The Journal of dermatology* 2000; 27(4): 225-232.
- 8-**Jing W, Ismail R.** Mucocutaneous manifestations of HIV infection: a retrospective analysis of 145 cases in a Chinese population in Malaysia. *International journal of dermatology* 1999;38(6):457-463.
- 9-**Davarpanah MA, Motazedian N, Jowkar F.** Dermatological manifestations of HIV/AIDS individuals in Shiraz, South of Iran. *Journal of global infectious diseases* 2018;10(2):80-83.
- 10-**Bosamiya SS, Vaishnani JB, Momin AM.** Dermatological manifestations of human immunodeficiency virus/acquired immunodeficiency syndrome in era of highly active antiretroviral therapy. *Indian journal of sexually transmitted diseases and AIDS* 2014;35(1):73. -75.
- 11-**Blanes M, Belinchón I, Merino E, Portilla J, Sánchez-Payá J, Betlloch I.** Current prevalence and characteristics of dermatoses associated with human immunodeficiency virus infection. *Actas Dermo-Sifiliográficas (English Edition)* 2010;101(8):702 -709.
- 12-**Padovese V, Racalbutto V, Barnabas GA, Morrone A.** Operational research on the correlation between skin diseases and HIV infection in Tigray Region, Ethiopia. *International journal of dermatology* 2015 ;54(10):1169 -74.
- 13-**Supparatpinyo K, Chiewchanvit S, Hirunsri P, Uthammachai C, Nelson KE, Sirisanthana T.** *Penicillium marneffei* infection in patients infected with human immunodeficiency virus. *Clinical infectious diseases* 1992;14(4):871-874.
- 14-**Vanittanakom N, Cooper CR, Fisher MC, Sirisanthana T.** *Penicillium marneffei* infection and recent advances in the epidemiology and molecular biology aspects. *Clinical microbiology reviews* 2006;19(1):95-110.
- 15-**Coopman SA, Johnson RA, Platt R, Stern RS.** Cutaneous disease and drug reactions in HIV infection. *New England journal of medicine* 1993;328(23):1670-1674.
- 16-**Eisman S.** Pruritic papular eruption in HIV. *Dermatologic clinics* 2006; 24(4): 449-457.
- 17-**Han J, Lun WH, Meng ZH, Huang K, Mao Y, Zhu W, et al.** Mucocutaneous manifestations of HIV-infected patients in the era of HAART in Guangxi Zhuang Autonomous Region, China. *Journal of the European Academy of Dermatology and Venereology* 2013;27(3):376-382.
- 18-**Tan J, Pina A, Borges-Costa J.** Skin diseases in the era of highly active antiretroviral therapy: a retrospective study of 534 patients. *Journal of the International Association of Providers of AIDS Care (JIAPAC)* 2018;17: 2325957417752255.
- 19-**Kim TG, Lee KH, Oh SH.** Skin disorders in Korean patients infected with human immunodeficiency virus and their association with a CD4 lymphocyte count: a preliminary study. *Journal of the European Academy of*

---

Dermatology and Venereology  
2010;24(12):1476 -1480.

Muthanna AM, Jamil A. Cutaneous infections among human immunodeficiency virus (HIV) - infected patients in UKMMC, Malaysia. *Microbes Infect Dis* 2022; 3(1): 55-61.