

# Mediastinal goiter diagnosed by functional imaging

Guido Michels<sup>1\*</sup>, Markus Dietlein<sup>2</sup>, Carsten Kobe<sup>2</sup> and Roman Pfister<sup>1</sup>

<sup>1</sup>Department III of Internal Medicine, University of Cologne, Cologne, Germany; <sup>2</sup>Department of Nuclear Medicine, University of Cologne, Cologne, Germany

A 63-year-old asymptomatic woman with cured Hodgkin diseases presented for restaging. The chest computed tomography showed a mass at the right side of the upper mediastinum. The benignity and the origin of the tissue were unknown. First, we performed a bronchoscopy-guided biopsy but without success. In the next step, we initiated radionuclide imaging with technetium-99m pertechnetate (Tc-99m) and radioiodine (I-123). Low uptake of Tc-99m and intense accumulation of I-123 after 2 and 24 h to the mediastinal mass suggested that the mass was a mediastinal goiter. Based on iodine uptake and the fact that our patient had no symptoms of tracheal compression, we decide to go for a radioiodine therapy.

Keywords: *mediastinal goiter; mediastinal tumor; scintigraphy; iodine-123; technetium-99m pertechnetate; radioiodine I-131 therapy*

Received: 9 December 2011; Revised: 21 December 2011; Accepted: 28 December 2011; Published: 19 January 2012

**A** 63-year-old asymptomatic woman with cured Hodgkin diseases presented in our hospital for restaging.

The physical examination and the laboratory tests were without pathological findings. The chest computed tomography (CT) showed a 54 × 44 × 75 mm mass at the right side of the upper mediastinum (Fig. 1A). The benignity and the origin of the tissue were still unknown. Therefore, after the CT, we performed a bronchoscopy with biopsy because it was very difficult radiologically to differentiate, for example, lymphoma (relapse) from other mediastinal tumors such as goiter. The histopathological results were unfortunately without success. Fine-needle biopsies are often difficult because of the inaccessibility of the mass or of the unreliability of the results. In our case, a bronchoscopy-guided rebiopsy as well a fine-needle aspiration was refused by the patient. In the next diagnostic step, we initiated radionuclide imaging with technetium-99m pertechnetate (Tc-99m; Fig. 1B) and radioiodine (I-123; Fig. 1C, D). Low uptake of Tc-99m and intense accumulation of I-123 after 2 h (Fig. 1C) and 24 h (Fig. 1D) to the mediastinal mass suggested that the paratracheal mass was a mediastinal goiter. The relatively expensive tracer I-123 offers the following advantages compared with Tc-99m: I-123 has the higher gamma energy of 159 keV instead of 141 keV and has higher uptake into the thyroid, which is relevant for the penetration of the gamma emitters through the chest wall. The I-123 scan after

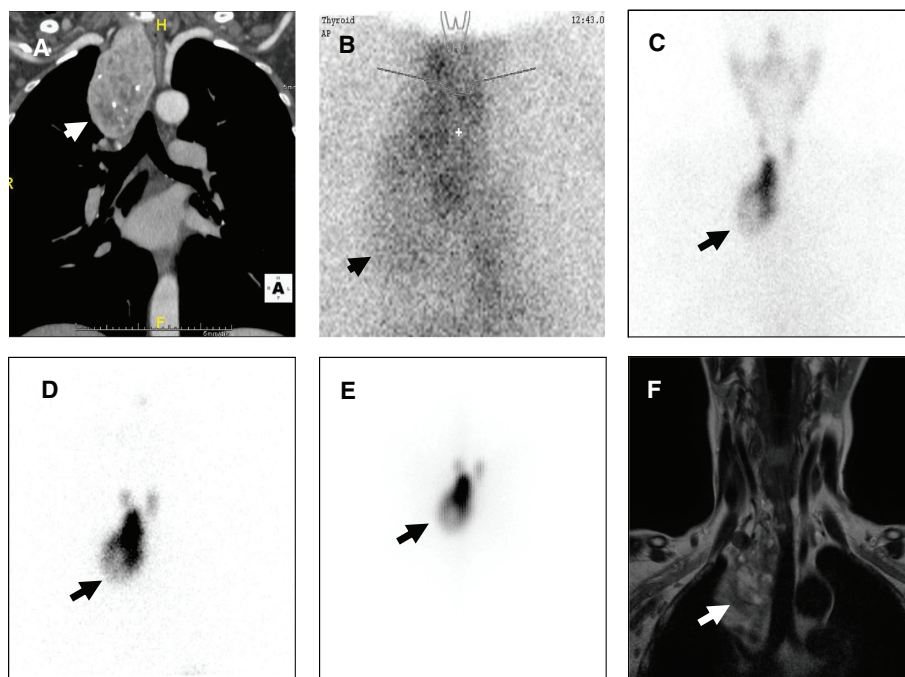
24 h shows organification of iodine, which is specific for thyroid tissue. Tc-99m uptake stands for trapping of an iodine analog in the early phase, but Tc-99m is not used for the synthesis of thyroid hormone. Thyroid nodules, which accumulate Tc-99m, but the late I-123 scans are iodine negative, are called 'trapping only nodules.' In such a constellation, the dignity of the tissue remains unclear, and patients are not qualified for radioiodine therapy. Based on I-123 uptake and the fact that our patient had no symptoms of tracheal stenosis such as stridor, we decide for a radioiodine therapy. The post-therapeutic I-131 scans 5 days after I-131 application show the organification of I-131 (E). One year later, magnetic resonance imaging presented goiter shrinkage without narrowing of the trachea (F).

## Learning points

- 1) Mediastinal goiters are the most frequent masses in the superior mediastinum (1–3).
- 2) The CT and radionuclide imaging can suggest or make the diagnosis in most cases.
- 3) In treatment, the radioactive I-131 therapy has been effectively used to reduce the size of intrathoracic goiters.

## Conflict of interest and funding

The authors have not received any funding or benefits from industry or elsewhere to conduct this study.



**Fig. 1.** (A) Contrast-enhanced CT demonstrates a homogeneous mass at the right side of the mediastinum (arrow). (B) Thyroid scintigraphy with 75 MBq Tc-99m pertechnetate. The scanning showed only marginal activity throughout the mediastinal mass (arrow). (C) Scintigraphy with 10 MBq I-123 2 h post-injection. (D) Image 24 h later. The late accumulation of I-123 at the right thyroid lobe and the mediastinal mass are the direct evidence that both areas are composed of a thyroid hormone-producing tissue. (E) Image 5 days after I-131 therapy. (F) Magnetic Resonance Imaging (MRI) 1 year after radioiodine therapy.

## References

1. Hardy RG, Bliss RD, Lennard TW, Balasubramanian SP, Harrison BJ. Management of retrosternal goitres. *Ann R Coll Surg.* 2009; 91: 8–11.
2. Madjar S, Weissberg D. Retrosternal goiter. *Chest.* 1995; 108: 78–82.
3. Rives JD. Mediastinal aberrant goiter. *Ann Surg.* 1947; 126: 797–810.

## \*Guido Michels

Department III of Internal Medicine  
 University of Cologne  
 Kerpener Str.-62, DE-50937 Cologne, Germany  
 Tel: +49 (221) 478 32379  
 Fax: +49 (221) 478 32355  
 Email: guido.michels@uk-koeln.de