

# Propranolol, infantile haemangiomas, and serendipity: new use for an old drug

Victor Grech<sup>1\*</sup> and Carmen Scerri<sup>2</sup>

<sup>1</sup>Consultant Pediatrician (Cardiology), Paediatric Department, Mater Dei Hospital, Tal-Qroqq, Malta;

<sup>2</sup>Midwifery Coordinator, St. James Hospital, Sliema, Malta

Capillary haemangiomas are benign lesions that may occur anywhere on the skin, may grow rapidly in the first two years of life and may impair vital organs. Propranolol has been recently discovered to shrink these lesions effectively. We report the first such patient treated in Malta with this drug.

Keywords: *haemangioma; propranolol*

Received: 22 November 2010; Accepted in revised form: 6 December 2010; Published: 1 January 2011

Capillary haemangiomas (strawberry nevus) are benign, haemartomatous endothelial cell neoplasms and occur as raised, red, lumpy lesions that may occur anywhere on the skin with a predilection (>50%) for the head and neck area. They constitute the most common orbital/periorbital tumours of childhood. Haemangiomas are found in approximately 1–2% of all neonates, manifesting between 1 and 4 weeks of age (1). Some may grow rapidly in the first 2 years in both size, depth, and elevation above the skin surface (proliferative phase), but then start to regress with 60% disappearing by 5 years of age and over 90% by 9 years age (involutional phase) (2). These lesions are common in Caucasians and in females rather than in males (5:1) (1). Because of their high rate of spontaneous resolution, treatment is only limited to those that impair sensory (obstruction of an eye may lead to irreversible amblyopia), vital organs, or that produce significant complication(s). Treatment in such cases was traditionally with the use of corticosteroids, alpha-interferon, and vincristine, all with limited success. Plastic surgery is equally disappointing (3, 4).

In 2009, a group of researchers who treated an infant with a large nasal haemangioma with corticosteroids iatrogenically induced hypertrophic obstructive cardiomyopathy. On commencing standard treatment with propranolol, they observed rapid involution of the haemangioma and this prompted the treatment of a small series of children (up to 5 mg/kg/d), with equal success (5). We report on one of the first patients treated

locally with this old drug in order to raise awareness of this 'novel' treatment.

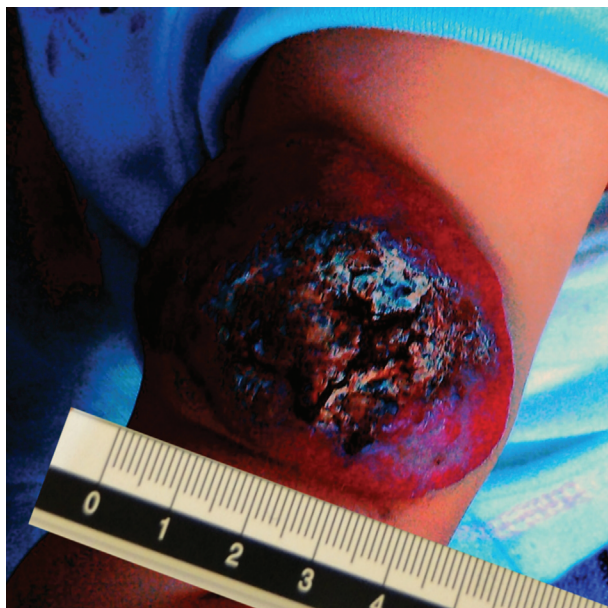## Patient

Our patient was a 6-month-old female Libyan infant who was delivered uneventfully in Malta at St. James Hospital in Sliema. Shortly after the baby returned to Libya, the parents noted a capillary haemangioma on the lateral aspect of the left arm. This lesion rapidly proliferated and ulcerated with a serous, non-infected discharge, probably as a result of frequent trauma as would be expected in an infant of this age with a lesion at this location. The lesion was tense, reddish purple all over, measured 53×44 mm, and was elevated by 20 mm above the skin surface (Fig. 1).

Due to the ulceration, discharge, and possibility of infection, propranolol was commenced at a dose of 1 mg/kg/dose thrice daily. Blood pressure remained stable and propranolol was increased to 2 mg/kg/dose thrice daily in the second week of treatment. The lesion exhibited rapid involution with shrinkage and reappearance of patches of normal skin. The child developed varicella and this did not have any effect on the lesion or treatment whatsoever. Propranolol was stopped after 6 weeks (Fig. 2) with the lesion measuring 40×20 mm and elevated 10 mm above the skin.

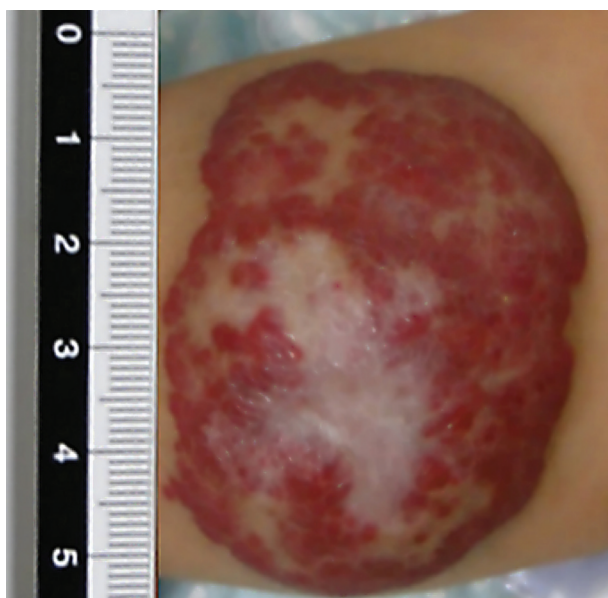
## Discussion

The practice of any aspect of science – including that of medicine – requires the independent replication of new



*Fig. 1.* Initial appearance of haemangioma prior to commencing oral propranolol.

ideas and results and, if these are confirmed, a paradigm shift occurs with the rejection of conventional theory and acceptance of the new standard. Breakthroughs commonly occur serendipitously in all branches of science including medicine. Serendipity is the propensity for making fortuitous discoveries while looking for something unrelated. An important aspect is the 'sagacity' of being able to link together apparently unrelated facts to



*Fig. 2.* Appearance of haemangioma after 6 weeks of treatment with oral propranolol.

come to a valuable conclusion. The list of such discoveries is endless including, for example, the accidental discovery of penicillin, the useful side effect of minoxidil for the promotion of hair growth in a drug initially developed for the treatment of hypertension, and the useful side effect of penile erection with sildenafil, a drug initially developed to treat coronary artery disease (6).

The mechanisms of haemangioma proliferation are uncertain, and it is believed that such growth is regulated through mediators such as basic fibroblast growth factor (bFGF) and vascular endothelial growth factor (VEGF) (7). Propranolol is a non-selective beta-blocker developed in the late 1950s and possible actions for promoting haemangioma involution, while uncertain, may include an immediate vasoconstriction within the lesion resulting in rapid colour change and palpable softening, decreased expression of VEGF and bFGF genes, and triggering of apoptosis of the endothelial cells contained within the lesion (7).

Propranolol is an effective and well-tolerated treatment in the management of selected cases of severe haemangiomas in infancy. Side effects include bradycardia, hypotension, and hypoglycaemia in very young infants and neonates, but these effects are typically mild and short lived. Indeed, after more than 40 years of clinical use in infants, there is no documented case of death or serious cardiovascular disease as a direct result of exposure to a beta-blocker in the literature (8). In our patient, treatment was stopped after 6 weeks as the lesion had involuted significantly with no residual ulceration, and the natural history of such lesions is spontaneous resolution. We hope that this publication will raise awareness among clinicians in Libya and in Malta with regard to this new treatment for significant haemangiomas by this old and inexpensive drug.

### Conflict of interest and funding

The authors have not received any funding or benefits from industry or elsewhere to conduct this study.

### References

1. Drolet BA, Esterly NB, Frieden IJ. Hemangiomas in children. *N Engl J Med.* 1999; 341: 173–81.
2. Haggstrom AN, Drolet BA, Baselga E, Chamlin SL, Garzon MC, Horii KA, et al. Prospective study of infantile hemangiomas: demographic, prenatal, and perinatal characteristics. *J Pediatr.* 2007; 150: 291–4.
3. Bruckner AL, Frieden IJ. Infantile hemangiomas. *J Am Acad Dermatol.* 2006; 55: 671–82.
4. Kilcline C, Frieden IJ. Infantile hemangiomas: how common are they? A systematic review of the medical literature. *Pediatr Dermatol.* 2008; 25: 168–73.
5. Léauté-Labrèze C, Dumas de la Roque E, Hubiche T, Boralevi F, Thambo JB, Taïeb A. Propranolol for severe hemangiomas of infancy. *N Engl J Med.* 2008; 358: 2649–51.
6. Pepys MB. Science and serendipity. *Clin Med.* 2007; 7: 562–78.

7. Storch CH, Hoeger PH. Propranolol for infantile haemangiomas: insights into the molecular mechanisms of action. *Br J Dermatol.* 2010; 163: 269–74.
  8. Love JN, Sikka N. Are 1–2 tablets dangerous? Beta-blocker exposure in toddlers. *J Emerg Med.* 2004; 26: 309–14.
- 

**\*Victor Grech**  
Consultant Paediatrician (Cardiology)  
Paediatric Department  
Mater Dei Hospital  
Tal-Qroqq, Malta  
Tel: 00356 25458000  
Email: victor.e.grech@gov.mt