



## Correspondence

### A Rare Case of a Giant Pelvic Retroperitoneal Epidermoid Cyst

Fakhir B, Mamouni N, Bouramdane N, Bouchikhi C, Bouguern H, Chaara H, Melhouf MA, Banani A

*Gynécology and Obstétrics departement, university hospital Hassan II Fez, Morocco.*  
Email: fakhirbouchra@hotmail.com

Received for publication on 25 December 2008. Accepted in revised form 13 January 2009

**Key words:** Cyst; Epidermic; Pelvis.

**To The Editor:** Epidermoid cyst is a frequent benign cutaneous tumor that could occur in any part of the human body. The pelvic cysts are uncommon and only a few cases are described in the literature. The following is a report of a rare case of a pelvic epidermoid cyst.

A seventy year old multiparus lady presented with progressive swelling in the abdomen. Clinical examination confirmed a large mass in the abdomen. The ultrasound showed a giant 35 cm abdomino-pelvic echogene mass, extending from the pubis symphysis to the epigastric region, displacing the liver, spleen and the urinary bladder. The computed

tomography showed similar finding (figure 1). A giant ovarian cyst was diagnosed.

Median laparotomy was performed and a 30 cm retroperitoneal cyst was found. Ovaries and uterus were normal. Uneventful cyst cleavage was performed after liberation of some intestinal and epiploic adhesences (figure 2). The cyst contained sebaceous matter and histological examination shows that the cystic wall was lined with flattened squamous epithelia with a distinguished granular layer. The cystic space was filled with a large amount of keratinized material. The histology was compatible with an epidermoid cyst. The post operative course was uneventful and the patient was doing well at the 5 months follow-up visit.

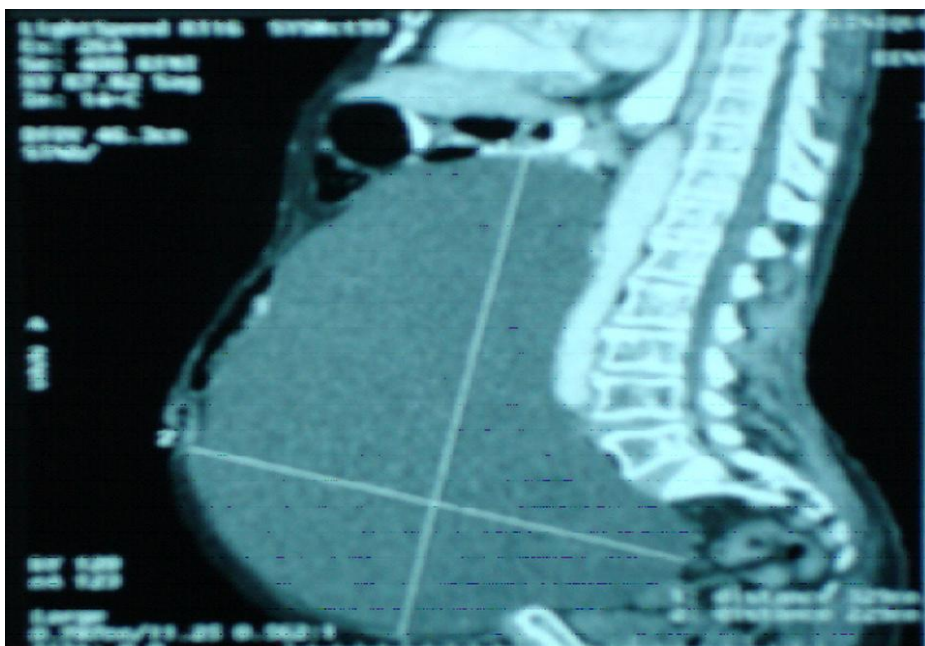

Figure 1: Reconstruction of the image with CT scan, giant intra-abdominal mass.

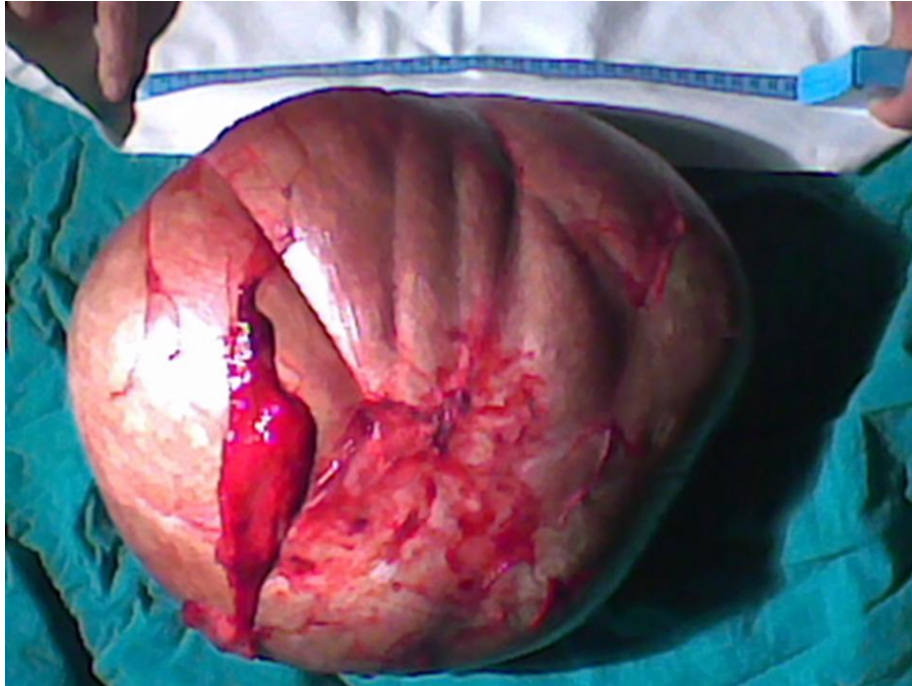


Figure 2: Image of the cyst after excision, size > 30cm

Epidermoid cyst is a frequent benign cutaneous tumor, usually present in patients with an age range of 19 to 45 years. In children it is associated with a Gardner syndrome in 50% of cases [1]. It was described in various parts of the body including penis, spleen and brain [2-4]. It is the most frequent cutaneous cyst in the head and neck (49%) [5]. Only three cases of pelvic epidermoid cyst were reported in the literature, one was retroperitoneal [1] and the other two were retro-rectal [6,7]. Concerning pathogenic theories, the epidermal cyst could be congenital, or post traumatic [8]. Epidermoid cysts are benign tumors with no risk of malignant transformation, but they may grow insidiously to reach a considerable sizes displacing or damaging other tissues and organs [9].

Pre-operatively, diagnosis of pelvic epidermoid cyst is difficult. Ultrasound and computed tomography often lead to a diagnosis of ovarian cyst. Magnetic resonance imaging (MRI) is more specific, as it shows epidermoid cyst as hypointense area on T1-weighted imaging and hyperintense on T2 weighted imaging without enhancement at contrast injection [10]. MRI could also help in confirming retroperitoneal localization; unfortunately it was not performed in our patient's case.

The treatment of the pelvic epidermoid cyst is a surgical ablation using a cleavage to avoid any organ damage. However, in dealing with

retroperitoneal space it could be difficult to avoid damaging iliac vessels and nerves [11] and if that is the case then the cyst must be punctured and drained before it is dissected. Precaution should be taken to avoid spillage of the contents out. A successful laparoscopic excision of a retro-rectal epidermoid cyst was described [7].

In conclusion, this report described a patient with a giant retroperitoneal pelvic epidermoid cyst which was successfully treated surgically. Although the pelvic epidermoid cysts are rare and difficult to diagnose pre-operatively, it should be considered in the differential diagnosis of ovarian tumors.

#### REFERENCES

- 1- Hachi H, Reragui A, Bouglab A, Benjelloune S. Le kyste épidermique géant pelvien : Une observation rare. *Gynecol. Obstet et fertilité* 31(2003) 359-61.
- 2- Shah SS, Varca G, Farsoil A, Fersaudez R, Richardson C. Giant epidermoid cyst Of Penis. *Urology* 1979; 14(4):389-91.
- 3- Sakamoto Y, Yonotani S, Edakuni G, Mori M, Iyama A, Miyazaki K. Laparoscopic splenectomy for a giant splenic epidermoid cyst: report of a case. *Surg today* 1999; 29(12):1268-72.
- 4- Lakhdar A. ; Sami A. ; Najaa A. ; Achouri M. ; Ouboukhlik A. ; EL Kamar A. ; EL Azhari A. Kyste épidermoïde de l'angle ponto-cérébelleux: Série chirurgicale de 10 cas et

- revue de la littérature. Neuro-chirurgie, 2003; 49(1) :13-24.
- 5- Al Khateeb TH., Al Masci NM., AL Zoubi F. Cutaneous cysts of the head and neck. J.oral. Maxillofac. Surg. 2009 Jan; 67(1):52-57.
  - 6- Midorikawa Y, Kubota K, Kayama H, Watanabe S, Kawai K, Kajivra N. Presacral epidermal cyst: a report of an adult case. Hepatogastroenterology 1996; 46(11):1399-402
  - 7- Palanivelu C, Rangarajan M, Senthilkumar R, Madankumar MV, Annapoorni S. Laproscopic and perineal excision of an infected "dumb-bell" shaped retrorectal epidermoid cyst. J. Laparoendosc. Adv. Surg. Tech. A. 2008 Feb; 18(1):88-92.
  - 8- Jaiswal A, Shetty A P, Rajasekaran S. Precoccygeal epidermal inclusion cyst presenting as coccygodynia. Singapore Med J 2008; 49(8):e212
  - 9- Chaimouf CH, Dintsman M. Omentopexy as treatment of a huge presacral epidermoid cyst: A case report. Dis. Col. And rect. 1974; 17(12):262.
  - 10- Chu CK, Tseng HM, Young YH. Clinical presentation of post fossa epidermoid cysts. Eur Arch. Otorhinolaryngol. 2006; (263):548-51.
  - 11- Andronescu PD, Simion S, Gomu N. and all. Surgical treatment of pelvic subperitoneal tumors. Chirurgia. 2000; 95(1):37-42.

**To cite this article:** Fakhir B, Mamouni N, Bouramdane N, Bouchikhi C, Bouguern H, Chaara H, Melhouf MA, Banani A. A Rare Case of a Giant Pelvic Retroperitoneal Epidermoid Cyst. *Libyan J Med.* 2009;4:74-76.