

## Effects of Ecballium elaterium on brain in a rat model of sepsis-associated encephalopathy

Demet Arslan, Aysun Ekinci, Akgul Arici, Eda Bozdemir, Esref Akil & Hasan Huseyin Ozdemir

To cite this article: Demet Arslan, Aysun Ekinci, Akgul Arici, Eda Bozdemir, Esref Akil & Hasan Huseyin Ozdemir (2017) Effects of Ecballium elaterium on brain in a rat model of sepsis-associated encephalopathy, *Libyan Journal of Medicine*, 12:1, 1369834, DOI: [10.1080/19932820.2017.1369834](https://doi.org/10.1080/19932820.2017.1369834)

To link to this article: <http://dx.doi.org/10.1080/19932820.2017.1369834>



© 2017 The Author(s). Published by Informa UK Limited, trading as Taylor & Francis Group.



Published online: 31 Aug 2017.



Submit your article to this journal [↗](#)



Article views: 47



View related articles [↗](#)



View Crossmark data [↗](#)

## Effects of Ecballium elaterium on brain in a rat model of sepsis-associated encephalopathy

Demet Arslan<sup>a</sup>, Aysun Ekinci<sup>b</sup>, Akgul Arici<sup>c</sup>, Eda Bozdemir<sup>d</sup>, Esref Akil<sup>a</sup> and Hasan Huseyin Ozdemir<sup>a</sup>

<sup>a</sup>Medical School, Neurology, Dicle University, Diyarbakir, Turkey; <sup>b</sup>Medical School, Biochemistry, Dicle University, Diyarbakir, Turkey; <sup>c</sup>Medical School, Pathology, Gaziosmanpasa University, Tokat, Turkey; <sup>d</sup>Cellular and Structural Biology, University of Texas Health Science Center at San Antonio, San Antonio, TX, USA

### ABSTRACT

Despite recent advances in antibiotic therapy, sepsis remains a major clinical challenge in intensive care units. Here we examined the anti-inflammatory and antioxidant effects of Ecballium elaterium (EE) on brain, and explored its therapeutic potential in an animal model of sepsis-associated encephalopathy (SAE) [induced by cecal ligation and puncture (CLP)].

Thirty rats were divided into three groups of 10 each: control, sepsis, and treatment. Rats were subjected to CLP except for the control group, which underwent laparotomy only. The treatment group received 2.5 mg/kg EE while the sepsis group was administered by saline. Twenty-four hours after laparotomy, animals were sacrificed and the brains were removed. Brain homogenates were prepared to assess interleukin 1beta (IL-1 $\beta$ ), interleukin 6 (IL-6), tumor necrosis factor alpha (TNF- $\alpha$ ), total antioxidant capacity (TAC), and total oxidant status (TOS). Brain tissue sections were stained by hematoxylin and eosin (H&E) to semi-quantitatively examine the histopathologic changes such as neuron degeneration, pericellular/perivascular edema and inflammatory cell infiltration in the cerebral cortex.

We found a statistically significant reduction in brain tissue homogenate levels of TNF- $\alpha$   $59.5 \pm 8.4/50.2 \pm 6.2$  ( $p = 0.007$ ) and TOS  $99.3 \pm 16.9/82.3 \pm 7.8$  ( $p = 0.01$ ) in rats treated with EE; although interleukin 6 levels were increased in the treatment group compared to the sepsis group, this was not statistically significant. Neuronal damage ( $p = 0.00$ ), pericellular/perivascular edema and inflammatory cell infiltration ( $p = 0.001$ ) were also significantly lower in the treatment group compared to those in the sepsis group.

These data suggest that Ecballium elaterium contains some components that exert protective effects against SAE in part by attenuating accumulation of proinflammatory cytokines, which may be important contributors to its anti-inflammatory effects during sepsis.

### ARTICLE HISTORY

Received 18 February 2017  
Accepted 11 August 2017

### RESPONSIBLE EDITOR

Amin Bredan  
Inflammation Research  
Center & VIB, Ghent  
University, Belgium

### KEYWORDS

Sepsis associated  
encephalopathy; Ecballium  
elaterium; Sepsis; TNF- $\alpha$ ; TOS

## 1. Introduction

Sepsis remains a major cause of morbidity and mortality despite recent advances in new treatments and rapidly evolving technologies that are being exploited to improve organ dysfunctions [1]. Sepsis is a systemic inflammatory response that may extend to involvement of widespread cell and tissue damage remote from the localized site of infection. During sepsis, brain is one of the first organs affected and up to 71% of patients demonstrate encephalopathy [1,2]. Sepsis associated encephalopathy (SAE) is the most common encephalopathy encountered among intensive care unit (ICU) patients and has been usually associated with poor prognosis [3,4]. SAE may cause serious cognitive dysfunctions, impaired consciousness, and delirium [5].

Polymicrobial sepsis induced by cecal ligation and puncture (CLP) is the most frequently used model among researchers since it closely resembles the characteristics of human sepsis [6]. It has been accepted as a gold standard model for sepsis and SAE [7]. This model

may show central nervous system involvement as well as hepatic, pulmonary and renal dysfunctions [5].

Ecballium elaterium (EE) is a plant from the Cucurbitacea family growing in the Mediterranean region of Turkey. It has been used in traditional Anatolian medicine for rhinosinusitis treatment due to its topical anti-inflammatory properties. These properties were widely studied by Uslu et al. [8,9]. Here, in our study, we wanted to further explore its anti-inflammatory effects and to determine if EE has neuroprotective potential during SAE.

## 2. Material and methods

### 2.1. Plant materials

Ecballium elaterium plant was picked from the Izmir forests in Turkey. The plant extract was prepared according to the method described by Okur et al. [10].

## 2.2. Anesthesia and surgical procedures

This study was approved by the Ethics Committee of Animal Experimentation of Dicle University School of Medicine. The animals were cared for according to the principles of the Guide for Care and Use of Experimental Animals.

We used 30 male Wistar albino rats, weighing 260–290 g, in this study. The rats were kept in cages under controlled conditions of temperature ( $21 \pm 1^\circ\text{C}$ ), light (12 h light/12 h dark cycle) and relative humidity (% 40–70). They were fed a balanced pellet diet and water, and acclimatized to conditions for one week before use.

Intramuscular injection of 50 mg/kg ketamine hydrochloride (Ketalar; Eczacibasi, Istanbul, Turkey) and 10 mg/kg xylazine (Rompun; Bayer, Istanbul, Turkey) was used for surgical anesthesia in all animal groups. Anesthesia was repeated as required during the surgical procedure. Animals underwent surgery under aseptic conditions. No antibiotics were administered during the experiment. A 3-cm midline incision was made on the abdominal wall, followed by ileocecal valve ligation with 3-O silk suture. Using a 18-gauge needle, antimesenteric surface of the cecum was punctured once. A piece of stool was extruded from the cecal enterotomy. Finally, the cecum was returned to the intraperitoneal cavity and the abdominal wall closed in layers of peritoneum and skin using running 3-O silk suture.

## 2.3. Animal groups and study design

Thirty rats were randomly divided into three groups: control group ( $n = 10$ ), sepsis group ( $n = 10$ ), treatment group ( $n = 10$ ). Rats in the control group underwent sham laparotomy only, while sepsis and treatment groups were subjected to CLP after laparotomy; 2.5 mg/kg Ecballium elaterium extract and 2 cc saline were administered intraperitoneally (treatment group and sepsis group, respectively) as previously reported [10,11] and then incisions were closed by proper suturing of the peritoneum and skin layers. At post-operative 24 h, the animals were sacrificed and the brains were removed. Brain homogenates and tissue sections were prepared for biochemical and histological examinations.

## 2.4. Assessment of IL-1 $\beta$ , IL-6, TNF- $\alpha$ , TAC, and TOS levels in brain tissue

Tissues were stored at  $-80^\circ\text{C}$  and then were thawed by stepwise temperature increase ( $-20^\circ\text{C}$  and  $+4^\circ\text{C}$ , respectively). Phosphate tampon with pH 7.4 and WiseTis homogenizer were used for tissue homogenization. The homogenate was then subjected to centrifugation at 3000 rpm for 10 min at  $+4^\circ\text{C}$ .

Supernatant was then transferred to ependorf tubes and IL-1 $\beta$ , IL-6, TNF- $\alpha$  levels were studied according to the ELISA kit procedure (eBioscience, Austria). Total antioxidant capacity (TAC) and total oxidant status (TOS) were measured by Erel's methods [12,13].

## 2.5. Histologic analysis

Brain tissues were fixed by 10% formalin and then embedded in paraffin; 4  $\mu\text{m}$ - thin sections were prepared and then stained by hematoxylin and eosin (H&E). Three sections from each animal were taken and three microscopic areas (cerebral cortex, basal ganglion, and cerebellum) in each section were examined. Histopathologic changes were observed under a light microscope by a pathologist blinded to the three study groups. Neuron degeneration, pericellular/perivascular edema and inflammatory cell infiltration were semiquantitatively examined in the cerebral cortex. Pycnotic nucleus, perineural space expansion and swelling or shrinkage of the cell were accepted as neuron degeneration and scored on a scale of 0–3 (0: no injury, 1: 1–3 cells/region 2: 4–6 cells/region, 3: 7–10 cells/region). Pericellular /perivascular edema and inflammatory cell infiltration was scored as 0: no injury, 1: slight injury, 2: moderate injury, 3: severe injury.

## 2.6. Statistical analysis

Data were analyzed using IBM SPSS statistics for Windows 18.0. Continuous variables were reported as mean  $\pm$  standard deviation and median  $\pm$  minimum-maximum. Descriptive statistics were used as continuous variables. Mann-Whitney *U*-test with Bonferroni correction and the Kruskal-Wallis test were used to compare differences between the groups within a categorical value. *p* values of  $<0.017$  were considered statistically significant.

## 3. Results

### 3.1. Biochemical results for brain tissues

Sepsis group was compared with the controls. The brain tissue levels of TNF- $\alpha$  ( $p = 0.003$ ) and TAC ( $p = 0.004$ ) were significantly higher in the sepsis group compared to those of control group. However, there was no statistical difference detected in IL-1  $\beta$ , IL-6 and TOS levels between these groups.

Sepsis group was further compared with the treatment group. The brain tissue levels of TNF- $\alpha$  ( $p = 0.007$ ) and TOS ( $p = 0.01$ ) decreased significantly in the treatment group compared to the sepsis group. No statistical difference was detected between IL-1  $\beta$ , IL-6 and TAC levels of these two groups (Tables 1 and 2).

Table 1. Biochemical analysis of brain tissue in different groups.

	IL-1 $\beta$ $\pm$ sd pg/L	IL-6 $\pm$ sd pg/mL	TNF- $\alpha$ $\pm$ sd ng/L	TAC $\pm$ sd mmol/L	TOS $\pm$ sd $\mu$ mol/L
CG	392.9 $\pm$ 12.5	31.7 $\pm$ 2.2	51.9 $\pm$ 2.4	0.1 $\pm$ 0.06	116.4 $\pm$ 11.6
SG	403.5 $\pm$ 35.0	29.9 $\pm$ 1.2	59.5 $\pm$ 8.4	0.2 $\pm$ 0.03	99.3 $\pm$ 16.9
TG	374.7 $\pm$ 37.5	36.8 $\pm$ 9.5	50.2 $\pm$ 6.2	0.2 $\pm$ 0.09	82.3 $\pm$ 7.8
p <sup>a</sup>	0.796	0.06	<b>0.003</b>	<b>0.004</b>	0.034
p <sup>b</sup>	0.08	0.02	<b>0.007</b>	0.21	<b>0.01</b>

CG: control group; SG: sepsis group; TG: treatment group; p<sup>a</sup>: comparison of CG and SG; p<sup>b</sup>: comparison of SG and TG.

Table 2. Biochemical analysis of brain tissue in different groups. Median (min-max).

	IL-1 $\beta$ pg/L	IL-6 pg/mL	TNF- $\alpha$ ng/L	TAC mmol/L	TOS $\mu$ mol/L
CG	396,9 (371,6–403,7)	31,2 (29,6–34,6)	52,8 (47,8–54,6)	0,12 (0,02–0,23)	113,6 (101,5–134,9)
SG	394,5 (349,6–498,4)	29,8 (27,8–31,9)	55,7 (52,8–75,0)	0,22 (0,14–0,25)	95,2 (76,2–127,6)
TG	377,7 (327,3–431,2)	34,4 (27,6–54,6)	49,3 (38,3–61,1)	0,28 (0,13–0,43)	83,7 (72,03–95,7)
p <sup>a</sup>	0.796	0.06	<b>0.003</b>	<b>0.004</b>	0.034
p <sup>b</sup>	0.08	0.02	<b>0.007</b>	0.21	<b>0.01</b>

CG: control group; SG: sepsis group; TG: treatment group.

### 3.2. Histopathological analysis

Neuronal damage ( $p = 0.002$ ,  $p = 0.00$ ), pericellular/perivascular edema and inflammatory cell infiltration ( $p = 0.003$ ,  $p = 0.001$ ) were higher in the sepsis group compared to those in control and treatment groups, respectively (Figure 1, Table 3).

## 4. Discussion

Sepsis is a major clinical challenge in intensive care units [14]. It is a potentially life threatening condition

complicated with important biochemical and histologic changes occurring especially within six hours [3]. The understanding of underlying mechanisms of sepsis has been improving [15]. Inflammatory response, which is induced by sepsis, may cause serious organ dysfunctions where endothelial injury plays a pivotal role [16]. As well as being a gatekeeper between blood and tissues, endothelium also exerts many functions in anti-inflammatory and anti-oxidant defense. Bacterial toxins and oxidative stress disturb endothelial integrity [15,16]. This results in increased permeability of the blood-brain barrier and brain

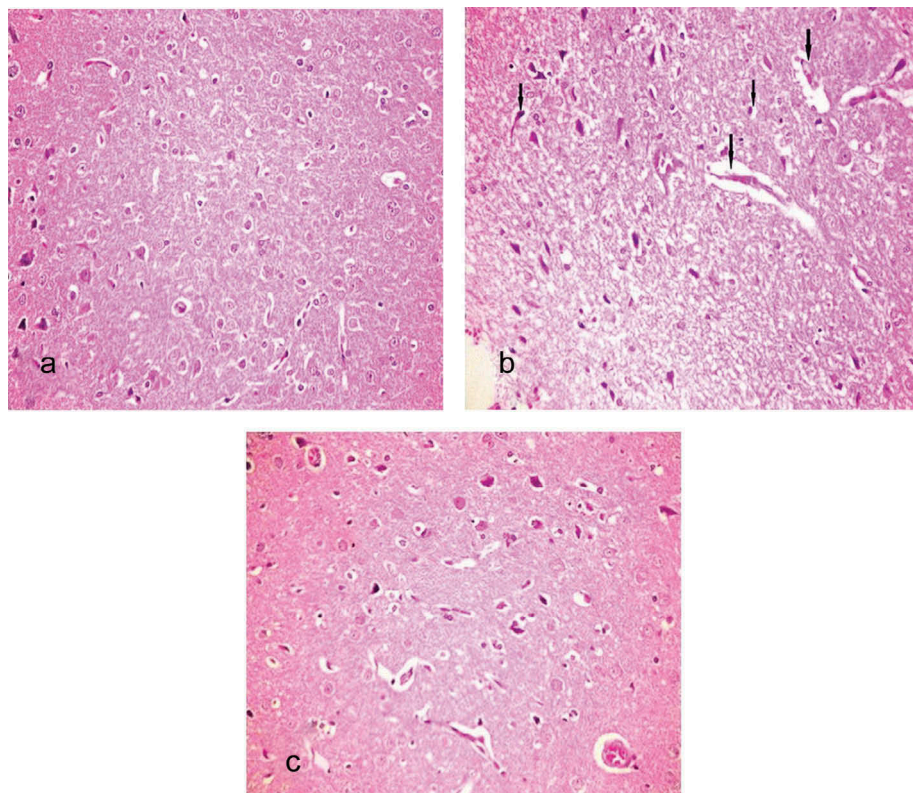


Figure 1. Light microscopy of brain tissues in different groups [hematoxylin and eosin (H&E), magnification 200 $\times$ ]. (a) Normal cerebral cortex (control group). (b) Pyknosis, degeneration at the capillary vessels, perineural and perivascular edema (sepsis group). (c) perineural and perivascular mild/moderate edema (treatment group).



**Table 3.** Brain histopathology results.

	CG	SG	TG	p <sup>a</sup>	p <sup>b</sup>
Neuronal damage $\pm$ <i>sd</i>	0.00	2.3 $\pm$ 0.4	0.00	<b>0.002</b>	<b>0.00</b>
Edema and inflammatory cell infiltration $\pm$ <i>sd</i>	0.00	2.6 $\pm$ 0.5	1.2 $\pm$ 0.4	<b>0.003</b>	<b>0.001</b>

CG: control group; SG: sepsis group; TG: treatment group; p<sup>a</sup>: comparison of CG and SG; p<sup>b</sup>: comparison of SG and TG.

edema, which may distort microcirculation. Further production of reactive oxygen species (ROS) through the brain tissues may induce increased secretion of pro-inflammatory cytokines such as IL-1  $\beta$ , IL-6 ve TNF- $\alpha$  [17,18]. This extreme inflammatory response produces oxidative tissue damage and affects brain functions as well. Although it is known that sepsis may cause encephalopathy via distant organ damage such as seen in liver and kidney, it is also possible to see encephalopathy without any distant organ damage. This may support the idea of SAE resulting from the systemic inflammation related to sepsis [4,7].

It is well-known that interleukin 6 plays an important role in diagnosis and prediction of mortality of patients with sepsis [18,19]. Most sepsis studies are based on serum interleukin 6 levels. In this study, we measured the levels of interleukin 6 in brain tissue. Goncalves et al. studied the profile of inflammatory markers in different tissues in experimental sepsis [20]. Their study showed that the changes of inflammatory marker levels in different tissues were not following a similar pattern at similar time-points although the serum levels were high at all time-points. Also, they reported that interleukin 6 levels in brain tissue are not significantly changed after 24 h. In the literature, TNF-alpha was commonly measured as a marker for sepsis associated encephalopathy in the brain tissue. The interleukin 6 levels were measured in serum [1,19,21–24].

TNF- $\alpha$  is secreted by many cells in brain tissues. It has protective and modulatory functions in normal brain tissues while showing neurotoxic effects during pathologic changes in the brain. It has a key role during immune response and may cause inflammation, apoptosis and necrosis [25]. It has been shown that peripheral and central administration of some pro-inflammatory cytokines may induce behavioral changes [26]. Erbas et al. detected a positive correlation between TNF- $\alpha$  levels and stereotype scores in septic rats. Their study further clarified the role of TNF- $\alpha$  and oxidative stress in behavioral changes [27]. In a similar manner, TNF- $\alpha$  may have an important role in SAE pathophysiology. Here, in our study, the sepsis group was found to have a significant increase in brain tissue levels of TNF- $\alpha$  while the rats treated with Ecballium elaterium had a significant reduction. EE might cause this decrease in TNF- $\alpha$  levels by its anti-inflammatory effects.

Although SAE pathophysiology is not well understood, many signs such as changes in the blood-

brain barrier and cerebral blood flow, cerebral edema, inflammation, oxidative stress, mitochondrial dysfunction, distortion in microcirculation and apoptosis were shown in different animal models [28]. An increase in apoptosis in lung, liver, kidney and intestine was detected in experimental sepsis models and found to be directly proportional to serum TNF- $\alpha$  levels [29]. TNF- $\alpha$  increases neuronal apoptosis and brain edema by stimulating neutrophil infiltration in the brain tissue. It has been shown that TNF- $\alpha$  is related to aquaporin 4 receptor up-regulation and cerebral edema, and has a key role in SAE [21]. Long-term memory deficit and neuronal loss was seen in experimental models, similar to signs in patients with sepsis [30]. Our study also showed higher neuronal damage, pericellular/perivascular edema and inflammatory cell infiltration score in the sepsis group. This score was significantly lowered in the treatment group, which might explain the protective effects of Ecballium elaterium on brain during SAE.

The complexities of the septic cascade continue to emerge and may identify new targets for innovative patient management. Current conventional sepsis treatments may worsen endothelial damage. Antibiotics may increase proinflammatory cytokine secretions and may further cause organ deficiencies. Fluid resuscitation, if delayed, may not improve the microcirculation disturbances, or if given too much, may distort barrier function. Taken together anti-oxidant agents are important candidates in sepsis treatment since they protect endothelial integrity [17].

Ecballium elaterium (EE) is a wild plant, which grows in the Mediterranean region and has been used in traditional medicine for many centuries. Some studies have described its cytotoxic effects against cancer cells as well as its neuroprotective and hepatoprotective roles [8,11,30]. The core of the EE fruit contains black seeds and a liquid juice. EE extract is made from this juice, which is also called 'elaterium'. This juice, without dilution, may cause edema formation if used topically [31]. However, Yesilada et al. determined EE's anti-edema activity by decreasing vascular permeability [32]. Also, our study did not show any edema formation due to EE but rather its protective effects against brain edema.

There is no previous study that determined the effects of EE on brain in a sepsis model. Our study is the first to reveal its effects in SAE, yet it has considerable importance from this perspective. Here, in this study, we explored the underlying mechanisms of EE's anti-oxidant and anti-inflammatory effects and determined that EE decreases oxidative damage induced by sepsis. TAC levels were increased in the sepsis group as opposed to decreased TOS levels in inverse proportion. This may explain that anti-oxidant activity was enhanced in order to suppress oxidant activity.

Furthermore, in the treatment group, EE also suppressed oxidant activity due to a significant decrease in TOS levels.

There is a limitation of the current study: The brains of 10 rats were divided into two hemispheres. The first hemisphere was used for homogenate studies. The second hemisphere was used for histological examination. Kafa et al. reported that sepsis affects each part of the brain differently but affects bilateral hemispheres equally. Because of this, we used this technique to prevent errors resulting from different responses from different parts of the brain to the sepsis [33].

## 5. Conclusions

We suggest that EE reduces the detrimental effects of sepsis on brain by its anti-inflammatory and anti-oxidant functions. Ecballium elaterium contains some components that exert protective effects against SAE in part by attenuating accumulation of proinflammatory cytokines. Decreased TNF- $\alpha$  and TOS levels, while correlated with the histopathologic results, show strong evidence that EE might be beneficial in neuroprotection during sepsis with all these potential effects. However, further studies with larger numbers of animals, different dosages of medications, and measurements of cytokines and oxidative parameters and also more detailed examination of the chemical composition of these extracts, are needed to clarify the neuroprotective role of EE in sepsis.

## Disclosure statement

No potential conflict of interest was reported by the authors.

## References

- [1] Chen D, Pan H, Li C, et al. Effects of hydrogen sulfide on a rat model of sepsis-associated encephalopathy. *J Huazhong Univ Sci Technolog Med Sci.* 2011;31:632–636.
- [2] Ebersoldt M, Sharshar T, Annane D. Sepsis-associated delirium. *Intensive Care Med.* 2007;33:941–950.
- [3] Toklu HZ, Uysal MK, Kabasakal L, et al. The effects of riluzole on neurological, brain biochemical, and histological changes in early and late term of sepsis in rats. *J Surg Res.* 2009;152:238–248.
- [4] Jacob A, Brorson JR, Alexander JJ. Septic encephalopathy: inflammation in man and mouse. *Neurochem Int.* 2011;58:472–476.
- [5] Imamura Y, Wang H, Matsumoto N, et al. Interleukin-1 $\beta$  causes long-term potentiation deficiency in a mouse model of septic encephalopathy. *Neuroscience.* 2011;187:63–69.
- [6] Brooks HF, Moss RF, Davies NA, et al. Caecal ligation and puncture induced sepsis in the rat results in increased brain water content and perimicrovessel oedema. *Metab Brain Dis.* 2014;29:837–843.
- [7] Ziaja M. Septic encephalopathy. *Curr Neurol Neurosci Rep.* 2013;13:383.

- [8] El Naggat el MB, Chalupova M, Prazanova G, et al. Hepatoprotective and proapoptotic effect of Ecballium elaterium on CCl<sub>4</sub>-induced hepatotoxicity in rats. *Asian Pac J Trop Med.* 2015;8:526–531.
- [9] Uslu C, Karasen RM, Sahin F, et al. Effect of aqueous extracts of Ecballium elaterium rich, in the rabbit model of rhinosinusitis. *Int J Pediatr Otorhinolaryngol.* 2006;70:515–518.
- [10] Okur MH, Aydogdu B, Arslan MS, et al. Intra-peritoneal administration of Ecballium elaterium diminishes post-operative adhesions. *Acta Cir Bras.* 2014;29:639–643.
- [11] Arslan MS, Basuguy E, Ibiloglu I, et al. Effects of Ecballium elaterium on proinflammatory cytokines in a rat model of sepsis. *J Invest Surg.* 2016;11:399–404.
- [12] Erel O. A novel automated method to measure total antioxidant response against potent free radical reactions. *Clin Biochem.* 2004;37:112–119.
- [13] Erel O. A new automated colorimetric method for measuring total oxidant status. *Clin Biochem.* 2005;38:1103–1111.
- [14] Makled MN, El-Awady MS, Abdelaziz RR, et al. Pomegranate protects liver against cecal ligation and puncture-induced oxidative stress and inflammation in rats through TLR/NF-kappaB pathway inhibition. *Environ Toxicol Pharmacol.* 2016;43:182–192.
- [15] Angus DC, van der Poll T. Severe sepsis and septic shock. *N Engl J Med.* 2013;369:2063.
- [16] Boisrame-Helms J, Kremer H, Schini-Kerth V, et al. Endothelial dysfunction in sepsis. *Curr Vasc Pharmacol.* 2013;11:150–160.
- [17] Ince C, Mayeux PR, Nguyen T, et al. The Endothelium in sepsis. *Shock.* 2016;45:259–270.
- [18] Hou T, Huang D, Zeng R, et al. Accuracy of serum interleukin (IL)-6 in sepsis diagnosis: a systematic review and meta-analysis. *Int J Clin Exp Med.* 2015;8:15238–15245.
- [19] Aksoy AN, Toker A, Celik M, et al. The effect of progesterone on systemic inflammation and oxidative stress in the rat model of sepsis. *Indian J Pharmacol.* 2014;46:622–626.
- [20] Goncalves MC, Horewicz VV, Luckemeyer DD, et al. Experimental sepsis severity score associated to mortality and bacterial spreading is related to bacterial load and inflammatory profile of different tissues. *Inflammation.* 2017;5:31.
- [21] Alexander JJ, Jacob A, Cunningham P, et al. TNF is a key mediator of septic encephalopathy acting through its receptor, TNF receptor-1. *Neurochem Int.* 2008;52:447–456.
- [22] Catalao CH, Santos-Junior NN, da Costa LH, et al. Brain oxidative stress during experimental sepsis is attenuated by simvastatin administration. *Mol Neurobiol.* 2016.
- [23] Huang M, Liu C, Hu Y, et al. Gamma-secretase inhibitor DAPT prevents neuronal death and memory impairment in sepsis associated encephalopathy in septic rats. *Chin Med J.* 2014;127:924–928.
- [24] Ning Q, Liu Z, Wang X, et al. Neurodegenerative changes and neuroapoptosis induced by systemic lipopolysaccharide administration are reversed by dexamethasone treatment in mice. *Neurol Res.* 2017;39:357–366.
- [25] Perry SW, Dewhurst S, Bellizzi MJ, et al. Tumor necrosis factor-alpha in normal and diseased brain: conflicting effects via intraneuronal receptor crosstalk? *J Neurovirol.* 2002;8:611–624.
- [26] Zalzman S, Murray L, Dycck DG, et al. Interleukin-2 and -6 induce behavioral-activating effects in mice. *Brain Res.* 1998;811:111–121.

- [27] Erbas O, Taskiran D. Sepsis-induced changes in behavioral stereotypy in rats; involvement of tumor necrosis factor-alpha, oxidative stress, and dopamine turnover. *J Surg Res.* 2014;186:262–268.
- [28] Comim CM, Barichello T, Grandgirard D, et al. Caspase-3 mediates in part hippocampal apoptosis in sepsis. *Mol Neurobiol.* 2013;47:394–398.
- [29] Cinel I. Sepsiste patojenik mekanizmalar. *J Turk Soc Intens Care.* 2003;1:14–24.
- [30] Arel-Dubeau AM, Longpre F, Bournival J, et al. Cucurbitacin E has neuroprotective properties and autophagic modulating activities on dopaminergic neurons. *Oxid Med Cell Longev.* 2014;2014:425496.
- [31] Eken C, Ozbek K, Yildirim CK, et al. Severe uvular edema and nasal mucosal necrosis due to *Ecbalium elaterium* (squirting cucumber): an allergic reaction or direct toxic effect? *Clin Toxicol.* 2008;46:257–258.
- [32] Yesilada E, Tanaka S, Sezik E, et al. Isolation of an anti-inflammatory principle from the fruit juice of *Ecballium elaterium*. *J Nat Prod.* 1988;51:504–508.
- [33] Kafa IM, Uysal M, Bakirci S, et al. Sepsis induces apoptotic cell death in different regions of the brain in a rat model of sepsis. *Acta Neurobiol Exp.* 2010;70:246–260.