

ORIGINAL ARTICLE

The effect of levosimendan on myocardial ischemia–reperfusion injury in streptozotocin-induced diabetic rats

Hasan Ali Kiraz¹, Fatih Poyraz², Gülay Kip³, Özlem Erdem⁴, Metin Alkan⁵, Mustafa Arslan^{5*}, Abdullah Özer⁶, Volkan Şivgin⁵ and Faruk Metin Çomu⁷

¹Department of Anaesthesiology and Reanimation, Onsekiz Mart University Medical Faculty, Canakkale, Turkey; ²Department of Cardiology, Kirikkale University Medical Faculty, Afyonkarahisar, Turkey; ³Department of Paediatric Dentistry (Anaesthesiology and Reanimation specialist), Gazi University Dentistry Faculty, Ankara, Turkey; ⁴Department of Pathology, Gazi University Medical Faculty, Ankara, Turkey; ⁵Department of Anaesthesiology and Reanimation, Gazi University Medical Faculty, Ankara, Turkey; ⁶Department of Cardiovascular Surgery, Gazi University Medical Faculty, Ankara, Turkey; ⁷Department of Physiology, Kirikkale University Medical Faculty, Afyonkarahisar, Turkey

Objective: Ischemia/reperfusion (I/R) injury is an important cause of myocardial damage by means of oxidative, inflammatory, and apoptotic mechanisms. The aim of the present study was to examine the potential cardio protective effects of levosimendan in a diabetic rat model of myocardial I/R injury.

Methods: A total of 18 streptozotocin-induced diabetic Wistar Albino rats (55 mg/kg) were randomly divided into three equal groups as follows: the diabetic I/R group (DIR) in which myocardial I/R was induced following left thoracotomy, by ligating the left anterior descending coronary artery for 60 min, followed by 2 h of reperfusion; the diabetic I/R levosimendan group (DIRL), which underwent I/R by the same method while taking levosimendan intraperitoneal 12 µg kg⁻¹; and the diabetic control group (DC) which underwent sham operations without tightening of the coronary sutures. As a control group (C), six healthy age-matched Wistar Albino rats underwent sham operations similar to the DC group. Two hours after the operation, the rats were sacrificed and the myocardial tissue samples were examined by light microscopy for evidence of myonecrosis and inflammatory cell infiltration.

Results: Myonecrosis findings were significantly different among groups ($p = 0.008$). Myonecrosis was more pronounced in the DIR group compared with the C, DC, and DIRL groups ($p = 0.001$, $p = 0.007$ and $p = 0.037$, respectively). Similarly, the degree of inflammatory cell infiltration showed significant difference among groups ($p < 0.0001$). Compared with C, DC, and DIRL groups, the inflammatory cell infiltration was significantly higher among the DIR group ($p < 0.0001$, $p < 0.0001$, and $p = 0.020$, respectively). Also, myocardial tissue edema was significantly different among groups ($p = 0.006$). The light microscopic myocardial tissue edema levels were significantly higher in the DIR group than the C, DC, and DIRL groups ($p = 0.001$, $p = 0.037$, and $p = 0.014$, respectively).

Conclusion: Taken together, our data indicate that levosimendan may be helpful in reducing myocardial necrosis, myocardial inflammation, and myocardial tissue edema resulting from ischemia–reperfusion injury.

Keywords: ischemia–reperfusion; levosimendan; myonecrosis; inflammatory cell infiltration; diabetic rat

*Correspondence to: Mustafa Arslan, Department of Anesthesiology and Reanimation, Gazi University Medical Faculty, TR-06510, Ankara, Turkey, Email: marslan36@yahoo.com; mustarslan@gmail.com

Received: 25 July 2015; Revised: 11 November 2015; Accepted: 16 November 2015; Published: 7 December 2015

Coronary artery atherosclerosis ranks first among the causes of death globally, and in the Western world it is thought that over one million people will experience life-threatening myocardial infarction (MI) annually (1). Diabetes mellitus is an important triggering factor that increases the risk of cardiovascular disease four- to fivefold (2). In diabetics, two- to fourfold higher risks of heart failure and fatalities after MI were reported (3).

Oxidative stress is an essential mediator of myocardial injury during ischemia and reperfusion. Mitochondria-derived reactive oxygen species has special relevance among various cellular sources of free radicals during tissue ischemia and reperfusion. Particularly in diabetics, hyperglycemia, hyperinsulinemia, and insulin resistance are closely related with high levels of oxidatives associated with myocardial ischemia–reperfusion injury (4).

Mitochondrial dysfunction, high NADPH oxidase activity, and nitric oxide synthetase (NOS) uncoupling result in very high levels of free radical generation in myocardium of diabetic rodents and subsequently myocardium tissue becomes non-resistant to the process of ischemia–reperfusion (5). Hyperglycemic state, mitochondrial dysfunction, NOS uncoupling, and decreased antioxidant defense systems in addition to disregulated cellular signaling mechanisms can lead to a more vulnerable myocardium, increased remodeling with a high risk of heart failure (6).

Levosimendan is an inotropic agent that sensitizes myocardium to calcium effects without leading to any increase in intracellular calcium levels (7). Levosimendan facilitates functional recovery from myocardial ischemia–reperfusion injury and may lead to preserved perfusion of major organs after myocardial reperfusion (8–10). Another important effect of levosimendan is the vasodilation of cardiac vessels as a result of the opening of ATP-sensitive potassium (KATP) channels in the plasma membrane and the activation of myocardial mitochondrial KATP (m-KATP) channels that result in limiting and persevering deleterious effects of ischemia–reperfusion injury (10). In this experimental study, we investigated the effects of levosimendan on cardiac ischemia–reperfusion injury in diabetic rats.

Materials and methods

Animals and experimental protocol

This study was conducted in the GUDAM Laboratory of Gazi University with the consent of the Experimental Animals Ethics Committee of Gazi University. All animals received human care in compliance with the ‘Principles of Laboratory Animal Care’ formulated by the National Society for Medical Research and the ‘Guide for the Care and the Use of Laboratory Animals’ prepared by the National Academy of Science and published by the National Institutes of Health (NIH Publication No. 85–23, revised in 1985).

In the study, 24 male Wistar Albino rats weighing between 200 and 250 g, raised under the same environmental conditions, were used. The rats were kept at 20–21°C in cycles of 12 h of daylight and 12 h of darkness and had free access to food until 2 h before the anesthetic procedure. The animals were randomly separated into four groups, each containing six rats.

Diabetes was induced by a single IP injection of streptozotocin (Sigma Chemical, St. Louis, MO, USA), at a dose of 55 mg kg⁻¹ body weight. The blood glucose levels were measured 72 h and 4 weeks following this injection. Rats were classified as diabetic if their fasting blood glucose (FBG) levels exceeded 250 mg dl⁻¹, and only animals with FBGs of >250 mg dl⁻¹ were included in the diabetic groups (diabetes only, diabetes plus ischemia–reperfusion,

and diabetes plus levosimendan–ischemia–reperfusion). The rats were kept alive for 4 weeks after streptozotocin injection to allow the development of chronic diabetes before they were exposed to ischemia/reperfusion (I/R), as described previously (11).

Rats were anesthetized with an IP injection of 100 mg kg⁻¹ of ketamine. The trachea was cannulated for artificial respiration. The chest was shaved and each animal was fixed in a supine position on the operating table. The chest was opened by a left thoracotomy followed by sectioning of the fourth and fifth ribs about 2 mm to the left of the sternum. Positive-pressure artificial respiration was started immediately with room air, using a volume of 1.5 ml/100 g body weight at a rate of 60 strokes/min. Sodium heparin (500 IU/kg) was administered through the peripheral vein in the tail.

After the pericardium was incised, the heart was exteriorized with gentle pressure on the right side of the rib cage. An 8-0 silk suture attached to a 10-mm micro point reverse-cutting needle was quickly placed under the left main coronary artery. The heart was then carefully replaced in the chest and the animal was allowed to recover for 20 min.

There were four experimental groups. Control group (C; *n* = 6), diabetic control group (DC; *n* = 6), diabetes–ischemia–reperfusion group (DIR; *n* = 6), and diabetes–ischemia–reperfusion–levosimendan group (DIRL; *n* = 6) underwent left thoracotomy and received IP Simdax 2.5 µg/ml (Abbott®, Orion Pharma, Espoo, Finland) 12 µg kg⁻¹ diluted in 10 ml of 0.5% dextrose administered intraperitoneally 30 min before ligating the left anterior descending (LAD) (12–14). A small plastic snare was threaded through the ligature and placed in contact with the heart. The artery could then be occluded by applying tension to the ligature (60 min of ischemia), and reperfusion was achieved by releasing the tension (120 min) (15). However, after the above procedure, the coronary artery was not occluded or reperfused in the control and diabetic control rats.

All the rats were given ketamine 100 mg kg⁻¹ IP and intracardiac blood samples were obtained. At the end of the reperfusion period, all rats were sacrificed under anesthesia and myocardium was harvested for histopathological analyses.

Histological determinations

All of the specimens were fixed in 10% buffered neutral formalin and embedded in paraffin. To visualize myocardial lesions at different levels, the entire heart was cut into four segments from apex to the base. The segments were embedded in paraffin and 4-µm thickness cross-sections were cut from each segment.

The slides were stained with Hematoxylin–Eosin (Bio-optica, Milano, Italy) for the evaluation of the tissues’ histological features. The slides were examined under light

microscope for myonecrosis, inflammatory cell infiltration, and edema. A minimum of 10 fields for each slide were examined and graded for severity of changes using scores on a scale of severe (+++), moderate (++) , mild (+), and nil (-) (16).

Statistical analysis

The Statistical Package for the Social Sciences (SPSS, Chicago, IL, USA) 20.0 Program was used for the statistical analysis. Differences in blood glucose levels and histopathological observations between study groups were assessed using the Kruskal–Wallis test. The Bonferroni-adjusted Mann–Whitney U-test was used after significant Kruskal–Wallis to determine which groups differed from the others. Results were expressed as mean \pm standard deviation (Mean \pm SD). Statistical significance was set at a *p* value of <0.05 for all analyses.

Results

Blood glucose levels measured 72 h after the injection were 83.44 ± 7.65 , 353.64 ± 47.35 , 368.26 ± 50.42 , and 355.32 ± 38.27 mg/dL for the C, DC, DIR, and DIRL groups, respectively. Blood glucose levels after 4 weeks were 96.35 ± 7.73 , 335.23 ± 38.19 , 349.34 ± 43.28 , and 368.30 ± 50.49 mg/dL for the C, DC, DIR, and DIRL groups, respectively. Serum glucose was detected to be significantly lower in Group C when compared with the DC, DIR, and DIRL groups (*p* < 0.0001).

Light microscopic myonecrosis findings were significantly different among groups (*p* = 0.008). Myonecrosis findings were significantly higher in the DIR group compared with the C, DC, and DIRL groups (*p* = 0.001, *p* = 0.007, and *p* = 0.037, respectively) (Table 1, Figs. 1–4). Similarly, light microscopic inflammatory cell infiltration degrees showed significant difference among groups (*p* < 0.0001). Compared with the C, DC, and DIRL groups, the microscopic inflammatory cell infiltration was significantly higher among the DIR group (*p* < 0.0001, *p* < 0.0001, and *p* = 0.020, respectively) (Table 1, Figs. 1–4). Myocardial tissue edema was significantly different among groups (*p* = 0.006). The light microscopic myocardial tissue edema levels were significantly higher in the DIR group than in the C, DC, and DIRL groups (*p* < 0.0001, *p* = 0.037, *p* = 0.014, respectively) (Table 1, Figs. 1–4).

Discussion

Myocardial ischemia and the following reperfusion is often a fatal consequence of increased oxygen requirement and/or diminished oxygen supply to the myocardium. Thirty minutes after coronary ligation, signs of cellular damage start, and if duration of coronary occlusion lengthens out, contraction band necrosis and myocytic cellular lysis – signs of irreversible myocardial damage – occur. After a period of ischemia (60 min) and reperfusion (60 min) edematous changes, nuclear changes, such as chromatin clumping and swelling, apoptosis induced by increased Bcl-2, and Fas ligand are observed. Also, glycogen depletion, mitochondrial swelling, and dilatation of sarcoplasmic reticulum are observed 60 min after occlusion (17). The essential participant of contraction and cellular injury processes is the Na(+)-Ca(++) ion exchange. Na(+)-K(+)ATPase and Ca(++)ATPase are key enzymes in maintaining normal myocardial function (17). During MI, high levels of oxidative stress arise and consequently superoxide and free radicals damage these ATPases. Impairment of Na+ -K+ ATPase pump emerges within 1 h of coronary artery ligation. Another important factor that causes cellular damage is hypoactivity of Ca++ATPase which is located in plasma membrane and endoplasmic reticulum. Reduced activity of Ca++ATPase leads to increased calcium intake. Increased intracellular calcium decreases mitochondrial ATP production. Free radical formation accelerates following intracellular calcium overload and consequently ischemia–reperfusion injury emerges. Further to that, diabetic myocardium is more sensitive to ischemia and reperfusion injury than that in non-diabetics. The principal triggering factor for myocardial injury secondary to ischemia and reperfusion in type 2 diabetes is oxidative stress (18). Several factors lead more vulnerable myocardium to oxidative stress in diabetics. Uncontrolled oxidation of cardiomyocyte sarcomeres, mitochondria, and interstitial and microvascular structures cause reversible or irreversible injury that can result in necrotic and apoptotic cell death (19). Advanced glycation end products (AGEs) and proteins are responsible for functional disturbances, impaired cytokine elimination, and the transformation process. In the diabetic state, smooth muscle cells that take up AGEs proteins through the RAGE

Table 1. Histopathological findings of the heart tissue (Mean \pm SD)

	Group C (n = 6)	Group DC (n = 6)	Group DIR (n = 6)	Group DIRL (n = 6)	<i>p</i> **
Myonecrosis	0.0 \pm 0.0*	0.17 \pm 0.41*	0.83 \pm 0.41	0.33 \pm 0.52*	0.008
Inflammatory cell infiltration	0.0 \pm 0.0*	0.17 \pm 0.41*	1.00 \pm 0.00	0.50 \pm 0.55*	< 0.0001
Edema	0.17 \pm 0.41*	0.83 \pm 0.41*	1.17 \pm 0.82	0.67 \pm 0.82*	0.006

**p* < 0.05: When compared with the DIR group.

***p*: Statistical significance was set at a *p* value < 0.05 for Kruskal–Wallis test.

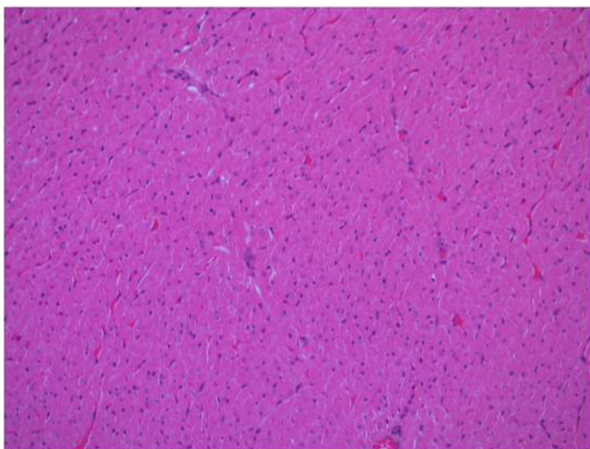


Fig. 1. Normal-structured myocardial tissue fibers in the control group, HEx200.

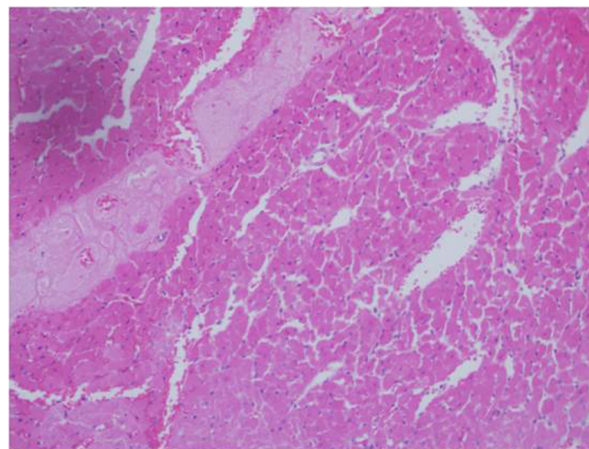


Fig. 4. Mild inflammatory cell infiltration and myonecrotic myocardial tissue in the diabetic ischemia reperfusion levosimendan group, HEx200.

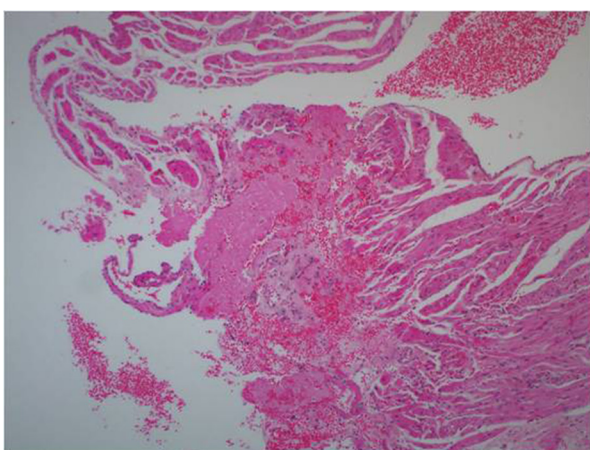


Fig. 2. Mild inflammatory cell infiltration and myonecrosis myocardial tissue in the diabetic control group, HEx200.

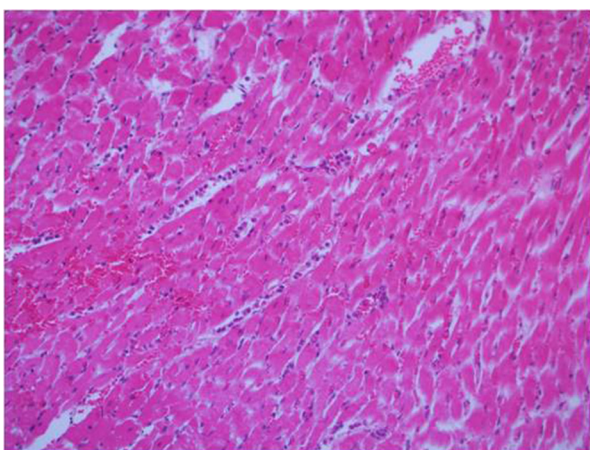


Fig. 3. Extensive inflammatory cell infiltration and edematous myocardial tissue in the diabetic ischemia reperfusion group, HEx200.

receptor migrate into coronary arteries and results in accelerated atherosclerosis in diabetes mellitus (17). On the contrary, there are several mechanisms, including activation of kinases such as protein kinase C (PKC), the overexpression of heat shock protein 72 in the myocardium, and also mitochondrial ATP-dependent potassium (mitoKATP) channel. The latter is particularly relevant to the present study because of its role in the mechanism of actions of levosimendan. It was shown that the opening of the mitochondrial mitoK(ATP) channel depolarizes the inner mitochondrial membrane leading to a reduction of Ca(++) overload during reperfusion and thereby limiting the extent of the I/R injury (17, 20).

Levosimendan sensitizes myocardium to calcium without changing the cytosolic Ca²⁺ concentration and activates the K ATP channels, which results in the protection of the ischemic-reperfused myocardium. Levosimendan exerts its action via two different mechanisms. The first mechanism involves sensitizing Troponin C to calcium via stabilizing calcium-induced conformation of Troponin C which results in increased Ca effect on myofilaments during systole without any high energy consumption. The second mechanism involves decreasing Ca levels during diastole which results in declined sensitization without any calcium overload – in contrast to other inotropics. Calcium overload – as mentioned above – is a trigger factor for oxidative stress because of the increased energy consumption, and myocyte dysfunction. These two actions of levosimendan increase the calcium myofilament interaction (actin-myosin) and facilitate cross-bridge formation results in greater contractility. One of the most important features of levosimendan is the Ca-dependent enhancement of actin-myosin cross-bridge formation. During diastole, intracellular Ca decreases and Ca-dependent action of levosimendan does not cause any harmful effect on myocardial relaxation during diastole. In addition,

levosimendan induces vasodilatation via opening ATP-dependent potassium (K) channels in myocytes and vascular smooth muscle cells. In this way, levosimendan reduces both preload and afterload, and increases coronary blood flow (21).

The beneficial actions of levosimendan in ischemia–reperfusion injury, as demonstrated by the results of the present study as well as previous studies (22, 23), may be attributed to its ability to open the ATP-sensitive K⁺ channels in the coronary vasculature causing relaxation of vascular wall and restoring coronary blood flow (22, 23). Levosimendan sensitizes myocardium to Ca⁺⁺ without changing the cytosolic Ca⁺⁺ concentration, and activates the K⁺-ATP channels that result in the protection of the myocardium against I/R injury. Although the exact mechanism has not been clarified, the higher IL6 and CRP levels in patients exhibiting myocardial stunning may serve as a link between inflammation and ischemia–reperfusion injury followed by stunning (24–26). In a pilot study, Wu et al. (27) investigated levosimendan effects on patients with acute myocardial infarction (AMI) who underwent percutaneous coronary intervention (PCI). Patients in the levosimendan group received levosimendan at a continuous infusion dose of 0.1 µg/kg/min for 24 h, and the remaining 10 patients received placebo treatment. At the end of study, the authors concluded that levosimendan can significantly improve the myocardial function of patients with myocardial stunning after PCI. Levosimendan prevented the rapid growth of inflammatory markers and thereby prevented the development of extensive injury. In our study, we similarly found that myocardial necrosis, myocardial inflammation, and myocardial tissue edema resulting from I/R injury were significantly reduced in levosimendan-treated group than that observed in other study groups.

Yapici et al. (28) showed that levosimendan-treated rat hearts were better protected than that in untreated group with cold cardioplegic arrest followed by global hypothermic ischemia. Although the manner of ischemia–reperfusion injury in this study was different from the method used in our study, the results were similar to ours.

In a similar model of acute regional myocardial ischemia–reperfusion injury that we used, Papp et al. (29) compared the effects of levosimendan versus milrinone – a phosphodiesterase inhibitor – on ventricular arrhythmias and in the overall survival in dogs. At the end of the study, they concluded that levosimendan was more effective than milrinone on preventing ventricular arrhythmias. In addition, levosimendan significantly improved the overall survival rate following myocardial ischemia–reperfusion injury.

Louhelainen et al. (30) assessed the effects of oral levosimendan (1 mg/kg/day) treatment that was started 24 h after LAD occlusion in type 2 diabetic Goto-Kakizaki (*n* = 54) versus non-diabetic Wistar (*n* = 25) rats

for 12 weeks. The main objective of this study was investigating post–infarct heart failure and cardiac remodeling. They found that in diabetic rats, levosimendan improved cardiac function (as assessed by transthoracic echocardiography) and attenuated cardiomyocyte apoptosis more effectively than that observed in normal Wistar rats. The authors concluded that this result may be related with the apoptosis-preventing effect of levosimendan via induction of cellular senescence in the pathogenesis. Although we have not investigated inflammation markers, such as interleukins, C-reactive peptide, etc., or apoptosis signaling pathways, our findings are positively correlated with this study in terms of diminished inflammatory processes as is seen in histological investigation.

In conclusion, our findings strongly indicate that levosimendan – similar to that shown in non-diabetic cardiac ischemia–reperfusion injury – has preventive effects on diabetic cardiac ischemia–reperfusion injury. This study shows promising results for levosimendan therapy, which may limit and/or prevent cardiac damage arising from ischemia–reperfusion injury.

Conflict of interest and funding

The authors have not received any funding or benefits from industry or elsewhere to conduct this study.

References

1. Roger VL, Go AS, Lloyd-Jones DM, Adams RJ, Berry JD, Brown TM, et al. Heart disease and stroke statistics – 2011 update: a report from the American Heart Association. *Circulation*. 2011; 123: 1–195.
2. Brown JR, Edwards FH, O'Connor GT, Ross CS, Furnary AP. The diabetic disadvantage: historical outcomes measures in diabetic patients undergoing cardiac surgery – the pre-intravenous insulin era. *Semin Thorac Cardiovasc Surg*. 2006; 18: 281–8.
3. Fisher BM. Heart abnormalities in IDDM. *Diabetologia*. 1997; 40(Suppl 2): S127–9.
4. Anderson EJ, Kypson AP, Rodriguez E, Lehr EJ, Neuffer PD. Substrate-specific derangements in mitochondrial metabolism and redox balance in the atrium of the type 2 diabetic human heart. *J Am Coll Cardiol*. 2009; 54: 1891–8.
5. Raedschelders K, Ansley DM, Chen DD. The cellular and molecular origin of reactive oxygen species generation during myocardial ischemia and reperfusion. *Pharmacol Ther*. 2012; 133: 230–55.
6. Boudina S, Abel ED. Diabetic cardiomyopathy, causes and effects. *Rev Endocr Metab Disord*. 2010; 11: 31–9.
7. Hasenfuss G, Pieske B, Kretschmann B, Holubarsch C, Alpert NR, Just H. Effects of calcium sensitizers on intracellular calcium handling and myocardial energetics. *J Cardiovasc Pharmacol*. 1995; 26: S45–51.
8. Huang L, Weil MH, Tang W, Sun S, Wang J. Comparison between dobutamine and levosimendan for management of postresuscitation myocardial dysfunction. *Crit Care Med*. 2005; 33: 487–91.
9. Eriksson HI, Jalonen JR, Heikkinen LO, Kivikko M, Laine M, Leino KA, et al. Levosimendan facilitates weaning from cardiopulmonary bypass in patients undergoing coronary artery

- bypass grafting with impaired left ventricular function. *Ann Thorac Surg.* 2009; 87: 448–54.
10. Kersten JR, Montgomery MW, Pagel PS, Warltier DC. Levosimendan, a new positive inotropic drug, decreases myocardial infarct size via activation of K(ATP) channels. *Anesth Analg.* 2000; 90: 5–11.
 11. Türeci E, İş M, Üzüm G, Akyüz F, Ulu MO, Döşoğlu M, et al. Alterations in blood-brain barrier after traumatic brain injury in streptozotocin-induced diabetic rats. *J Nervous Sys Surgery.* 2009; 2: 79–86.
 12. Cakir M, Polat A, Tekin S, Vardi N, Taslidere E, Rumeysa Duran Z, et al. The effect of dexmedetomidine against oxidative and tubular damage induced by renal ischemia reperfusion in rats. *Ren Fail.* 2015; 37: 704–8.
 13. Wang H, Chen H, Wang L, Liu L, Wang M, Liu X. Acute hyperglycemia prevents dexmedetomidine-induced preconditioning against renal ischemia-reperfusion injury. *Acta Cir Bras.* 2014; 29: 812–18.
 14. Jeon YT, Hwang JW, Lim YJ, Park SK, Park HP. Postischemic sevoflurane offers no additional neuroprotective benefit to preischemic dexmedetomidine. *J Neurosurg Anesthesiol.* 2013; 25: 184–90.
 15. Kocoglu H, Karaaslan K, Gonca E, Bozdogan O, Gulcu N. Preconditioning effects of dexmedetomidine on myocardial ischemia/reperfusion injury in rats. *Curr Ther Res Clin Exp.* 2008; 69: 150–8.
 16. Loh HK, Sahoo KC, Kishore K, Ray R, Nag TC, Kumari S, et al. Effects of thalidomide on isoprenaline-induced acute myocardial injury: a haemodynamic, histopathological and ultrastructural study. *Basic Clin Pharmacol Toxicol.* 2007; 100: 233–9.
 17. Asano G, Takashi E, Ishiwata T, Onda M, Yokoyama M, Naito Z, et al. Pathogenesis and protection of ischemia and reperfusion injury in myocardium. *Nippon Med Sch.* 2003; 70: 384–92.
 18. Ansley DM, Wang B. Oxidative stress and myocardial injury in the diabetic heart. *J Pathol.* 2013; 229: 232–41.
 19. Schneider R, Welt K, Aust W, Löster H, Fitzl G. Cardiac ischemia and reperfusion in spontaneously diabetic rats with and without application of EGb 761: I. cardiomyocytes. *Histol Histopathol.* 2008; 23: 807–17.
 20. Wang Y, Takashi E, Xu M, Ayub A, Ashraf M. Downregulation of protein kinase C inhibits activation of mitochondrial K (ATP) channels by diazoxide. *Circulation.* 2001; 104: 85–90.
 21. Kasikcioglu HA, Cam N. A review of levosimendan in the treatment of heart failure. *Vasc Health Risk Manag.* 2006; 2: 389–400.
 22. Grossini E, Molinari C, Caimmi PP, Uberti F, Vacca G. Levosimendan induces NO production through p38 MAPK, ERK and Akt in porcine coronary endothelial cells: role for mitochondrial KATP channel. *Br J Pharmacol.* 2009; 156: 250–61.
 23. Caimmi PP, Molinari C, Uberti F, Micalizzi E, Valente G, Mary DA, et al. Intracoronary levosimendan prevents myocardial ischemic damages and activates survival signaling through ATP-sensitive potassium channel and nitric oxide. *Eur J Cardiothorac Surg.* 2011; 39: e59–67.
 24. Jefferies HJ, Virk B, Schiller B, Moran J, McIntyre CW. Frequent hemodialysis schedules are associated with reduced levels of dialysis-induced cardiac injury (myocardial stunning). *Clin J Am Soc Nephrol.* 2011; 6: 1326–32.
 25. Steffens S, Montecucco F, Mach F. The inflammatory response as a target to reduce myocardial ischaemia and reperfusion injury. *Thromb Haemost.* 2009; 102: 240–7.
 26. Anselmi A, Abbate A, Girola F, Nasso G, Biondi-Zoccai GG, Possati G, et al. Myocardial ischemia, stunning, inflammation, and apoptosis during cardiac surgery: a review of evidence. *Eur J Cardiothorac Surg.* 2004; 25: 304–11.
 27. Wu X, Wu J, Yan X, Zhang Y. Enhancement of myocardial function and reduction of injury with levosimendan after percutaneous coronary intervention for acute myocardial infarction: a pilot study. *Cardiology.* 2014; 128: 202–8.
 28. Yapici D, Altuncan Z, Ozeren M, Bilgin E, Balli E, Tamer L, et al. Effects of levosimendan on myocardial ischaemia–reperfusion injury. *Eur J Anaesthesiol.* 2008; 25: 8–14.
 29. Papp JG, Pollesello P, Varro AF, Végh AS. Effect of levosimendan and milrinone on regional myocardial ischemia/reperfusion-induced arrhythmias in dogs. *J Cardiovasc Pharmacol Ther.* 2006; 11: 129–35.
 30. Louhelainen M, Vahtola E, Forsten H, Merasto S, Kytö V, Finckenberg P, et al. Oral levosimendan prevents postinfarct heart failure and cardiac remodeling in diabetic Goto-Kakizaki rat. *J Hypertens.* 2009; 27: 2094–107.