

LETTER TO THE EDITOR

## Interventricular septum hydatid cyst presenting with acute lower limb ischemia: a case report

Ben Jmaà Hèla<sup>1\*</sup>, Bouassida Abir<sup>1</sup>, Gueldich Majdi<sup>1</sup>, Dammak Aiman<sup>1</sup>, Souissi Iheb<sup>2</sup>, Elleuch Nizar<sup>1</sup>, Masmoudi Sayda<sup>1</sup> and Frikha Imed<sup>1</sup>

<sup>1</sup>Department of Cardiovascular and Thoracic Surgery, Habib Bourguiba Hospital, Sfax, Tunisia; <sup>2</sup>Department of Anesthesiology, Habib Bourguiba Hospital, Sfax, Tunisia

Cardiac hydatid cysts are rarely seen. The presentation of an acute lower limb ischemia secondary to embolization from an interventricular hydatid cyst is also rare. We describe a case of a 30-year-old-man who presented with acute lower limb ischemia revealing hydatid cyst of the interventricular septum and septal defect, and who was operated on successfully.

Keywords: *hydatidosis; embolism; interventricular septum; embolectomy; cardiopulmonary bypass*

\*Correspondence to: Ben Jmaà Hèla, Department of Cardiovascular and Thoracic Surgery, Habib Bourguiba Hospital, PO Box 3029, Sfax, Tunisia, Email: bjhela@yahoo.fr

Received: 24 May 2015; Accepted in revised form: 10 June 2015; Published: 29 June 2015

Hydatid cyst of the heart is very rare. It is characterized by a clinical latency. Rupture into left-sided chambers may cause systemic emboli. Embolization to the femoral artery is very rare (1).

We report a case of a patient presented with a cardiac hydatid cyst with a peripheral embolic event in the femoral artery.

### Case presentation

A 30-year-old man was admitted to our hospital for acute pain of the right lower limb. Clinical examination revealed a cold limb with cyanotic toes. The right popliteal pulse was abolished. So he was operated on for acute lower limb ischemia. He underwent embolectomy of the femoral artery through a surgical access of the common femoral artery.

The deobstruction with a Fogarty catheter took off a cruric thrombus with a white membrane from the superficial femoral artery (Fig. 1). So the diagnosis of cardiac hydatid cyst complicated by systemic embolism was suspected.

A trans-thoracic echocardiography defined an anechoic lesion of 29 × 27 mm originating from the interventricular septum and ruptured into the left ventricle via a septal defect of 9 mm (Fig. 2).

Computerized tomographic scan of thorax revealed a well-defined cystic lesion of 26.7 mm in diameter protruding into the right ventricle (Fig. 3).

The patient underwent surgery via a sternotomy and under cardiopulmonary bypass between the ascending aorta and the two vena cava.

Right atriotomy revealed a mass protruding into the cavity of the right ventricle and based in the interventricular septum. So, this mass was excised and the septal defect was closed by a synthetic patch (Fig. 4).

The postoperative period was uneventful, and the patient was discharged from the hospital on the fourth

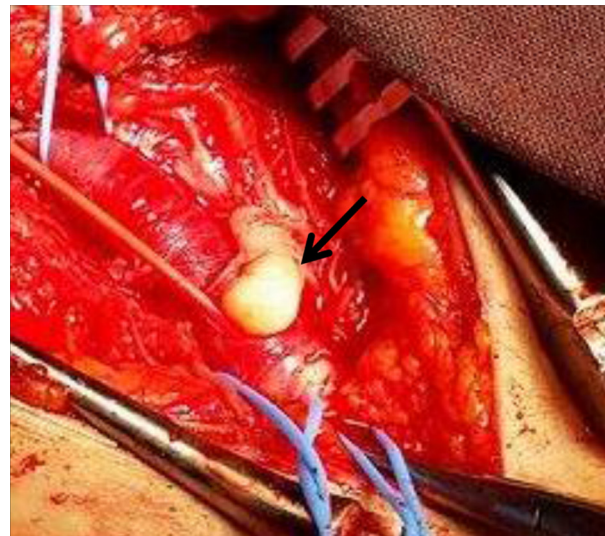
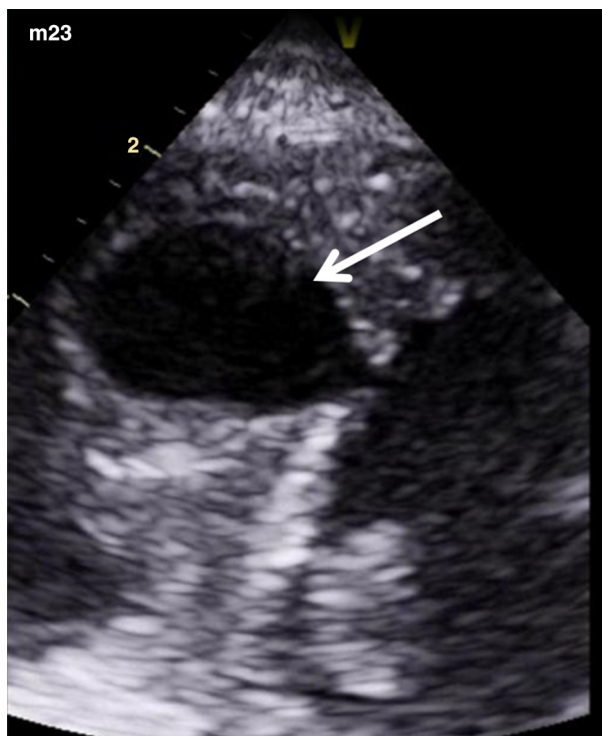


Fig. 1. Hydatid membrane removed from the superficial femoral artery (arrow).



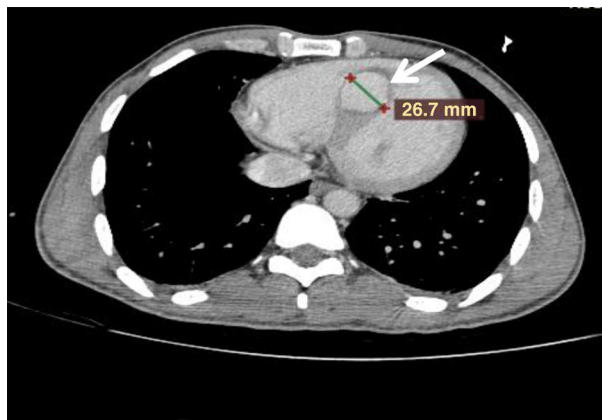
**Fig. 2.** Anechoic lesion originating from the interventricular septum (arrow).

postoperative day without symptoms. Then, the patient was treated with albendazole.

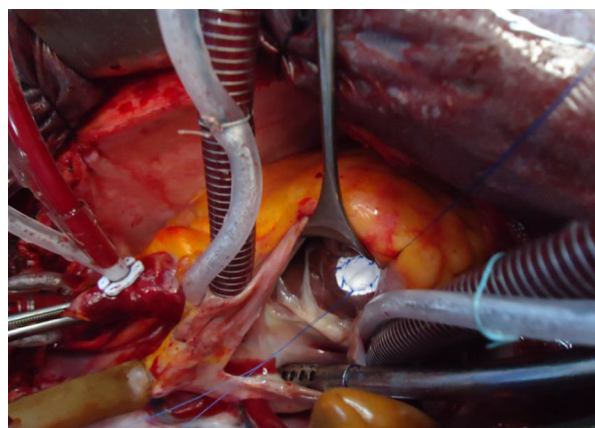
### Discussion

Echinococcosis is a tissue infestation caused by the larva of *Echinococcus granulosus*. Man is a common accidental host.

Cardiac echinococcosis is a rare condition; it represents only 0.5–2% of all hydatid infestations (2). The left ventricle is the most commonly affected site (3). The location in the interventricular septum is reported in 5–9% of cardiac cases (4).



**Fig. 3.** A cystic mass originating from the interventricular septum and protruding into the right ventricle (arrow).



**Fig. 4.** Suture of the septal defect by a synthetic patch.

Systemic embolism by echinococcus cyst is rare and is due to rupture of a primary left-sided intracardiac cyst and lodgement of the daughter cysts in an arterial bifurcation, commonly that of the femoral artery (5). Di Bello and Menéndez reported eight cases of acute embolism of the lower limbs by an echinococcus cyst (5).

Ozer et al. (6) reported two cases of cysts of left heart revealed by systemic embolic event.

In our case, the cyst was located within the interventricular septum, which is an uncommon site, and it was protruding to the right ventricle. It was complicated by rupture and systemic embolism via a septal defect of 9 mm.

Other locations of systemic embolism may occur. Acartürk et al. (7) reported a case of left ventricular hydatid presenting with acute ischemic stroke in a child. Rosenberg et al. (8) reported a case of abdominal aortic embolism by a primary intracardiac echinococcus cyst treated successfully with bilateral femoral embolectomy.

### Conclusion

Peripheral arterial embolism is a rare manifestation of interventricular septum hydatid cyst. Embolectomy and surgical resection of the cyst must be performed with emergency. Patients must then undergo treatment by albendazole to prevent dissemination of the disease.

### Conflict of interest and funding

The authors declared no conflict of interest.

### References

1. Madariaga I, de la Fuente A, Lezaun R, Imizcoz MA, Carmona JR, Urquia M, et al. Cardiac echinococcosis and systemic embolism: report of a case. *Thorac Cardiovasc Surg.* 1984; 32: 57–9.
2. Sai Chandran BV, Durga Prasad R, Sudarsan Reddy P, Subbarao VK. Intramyocardial hydatid cyst: a mistaken identity and its successful removal on a beating heart. *Interact Cardiovasc Thorac Surg.* 2011; 13: 208–10.

3. Nancuso L, Bondi F, Marchi S, Iacona MA, Guarnera S, Patane L. Cardiac hydatid disease with clinical features resembling tricuspid stenosis. *Am Heart J*. 1987; 113: 1234–6.
4. Tetik O, Yetkin U, Yazici M, Tulukoglu E, Gurbuz A. A case with giant hydatid cyst localized in right ventricle wall. *Turkish J Thorac Cardiovasc Surg*. 2004; 12: 265–7.
5. Di Bello R, Menéndez H. Intracardiac rupture of hydatid cysts of the heart. A study based on 3 personal observations and 101 cases in the world literature. *Circulation*. 1963; 27: 366–74.
6. Ozer N, Aytemir K, Kuru G, Atalar E, Özer Y, Övünc K, et al. Hydatid cyst of the heart as a rare cause of embolization: report of 5 cases and review of published reports. *J Am Soc Echocardiogr*. 2001; 14: 299–302.
7. Acartürk E, Özeren A, Koç M, Yaliniz H, Biçakci S, Demir M. Left ventricular hydatid cyst presenting with acute ischemic stroke: case report. *J Am Soc Echocardiogr*. 2004; 17: 1009–10.
8. Rosenberg T, Panayiotopoulos YP, Bastounis E, Papalambros E, Balas P. Acute abdominal aorta embolism caused by primary cardiac echinococcus cyst. *Eur J Vasc Surg*. 1993; 7: 582–5.