

HOW

I DO IT

# Preventing Inadvertent Placement of Foley Catheter into Prostatic Urethra During Suprapubic Trocar Cystostomy: A Simple Face-saver Trick

Rahul Yadav, Deepansh Dalela, Divakar Dalela, Rohit Kathpalia, Apul Goel, Satya N. Sankhwar

Department of Urology, King George's Medical University (Erstwhile Chattrapati Shahuji Maharaj Medical University), Lucknow, Uttar Pradesh, India

## INTRODUCTION

Percutaneous suprapubic trocar cystostomy (SPC) is often needed to drain the bladder when urethral catheterization either fails or is not advisable.<sup>[1]</sup> It is performed either directly or under ultrasound guidance.<sup>[2]</sup> SPC is safe, but complications such as bowel injury, hematuria, and migration of foley catheter into the prostatic urethra rarely happen.<sup>[1,3,4]</sup> We present a point of technique to prevent accidental placement of tip of foley catheter while performing SPC using the metal trocar and the cannula.

## MATERIALS AND METHODS

### Technique

Most surgeons use a metal trocar with a slotted cannula to accomplish suprapubic catheter placement under local anesthesia using standard technique.<sup>[2]</sup> Usually, this is introduced blindly through midline after ensuring full bladder or sometimes under ultrasound guidance. The slotted cannula sheath of trocar is usually beveled at distal end. Once the bladder is entered [Figure 1], the urine starts welling out through the hole in obturator. As the obturator is removed, the gush of urine flows outward and the resultant decrease in bladder volume tilts the slotted

## ABSTRACT

During suprapubic cystostomy using standard technique, there always remains a chance of accidental migration of foley catheter through bladder neck into prostatic urethra. We herein present a point of technique in which by keeping the direction of cannula slot toward umbilicus and making it vertical or slightly tilting its tip toward umbilicus during foley placement, prevents the inadvertent migration of catheter into prostatic urethra and further complications.

**Key words:** Catheter migration, foley catheter, suprapubic cystostomy

cannula toward pubic symphysis [Figure 2]. At this point of time, if the slot in cannula faces pubic symphyseal side, its bevel is in close proximity to bladder neck and the advancing catheter tip is likely to advance into bladder neck and prostatic urethra [Figure 3]. Instead, we recommend keeping the direction of slot toward the umbilicus side and then slightly tilting the cannula sheath cephalad before advancing the catheter through it, thus keeping the tip of cannula away from the bladder neck and preventing accidental advancement of foley catheter into prostatic urethra [Figure 4]. Moreover, the tendency to over insert the catheter in bladder lumen should be resisted.

## RESULTS

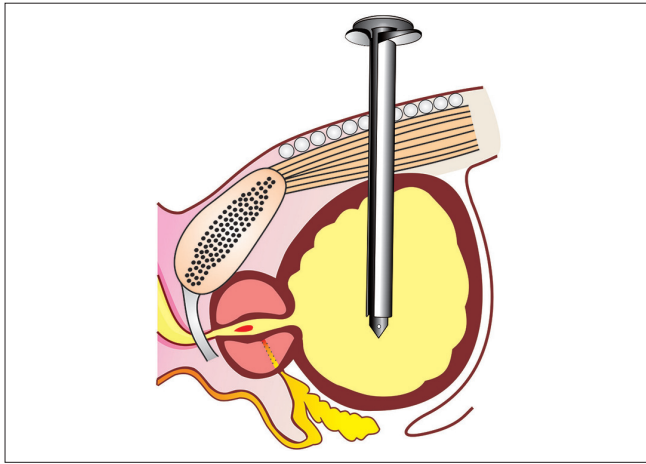
Retrospective data analysis of the patients who underwent trocar SPC where direction of slotted cannula was kept toward pubic symphysis was carried out between July 2012 and November 2012. It was found that in three cases out of 18, the foley catheter entered prostatic urethra intra-operatively. In one of these cases, the catheter even transgressed the prostatic and membranous urethra to get lodged in bulbous urethra. Between December 2012 and January 2013, another six patients underwent SPC with modification of technique i.e., keeping the direction of the slot toward umbilicus. In addition, the cannula was kept either straight or slightly tilted toward the dome of bladder while passing the foley catheter. With these technical changes, in none of the cases the catheter went into the prostatic urethra.

## DISCUSSION

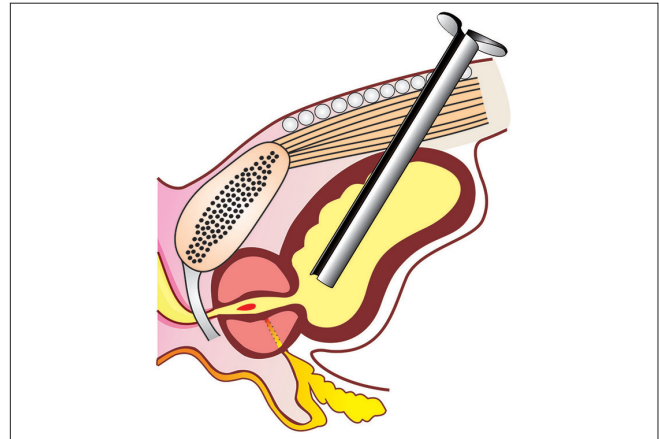
Percutaneous suprapubic cystostomy is the procedure of

Access this article online	
Quick Response Code:	Website: <a href="http://www.jstcr.org">www.jstcr.org</a>
	DOI: 10.4103/2006-8808.118634

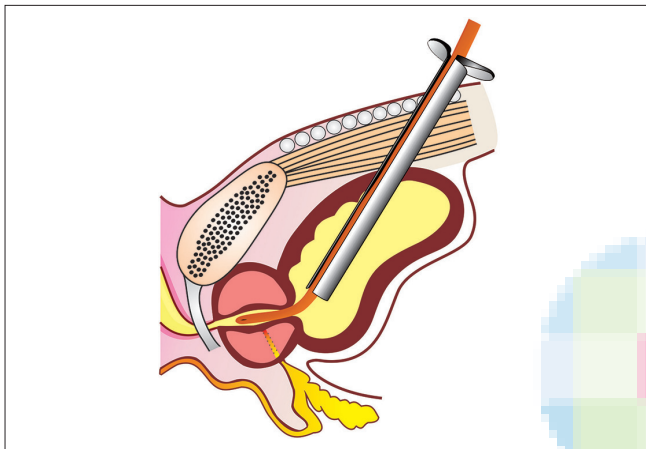
**Address for correspondence:** Dr. Divakar Dalela, Department of Urology, King George's Medical University (Erstwhile Chattrapati Shahuji Maharaj Medical University), Lucknow - 226 003, Uttar Pradesh, India. E-mail: [drdalela@satyam.net.in](mailto:drdalela@satyam.net.in)



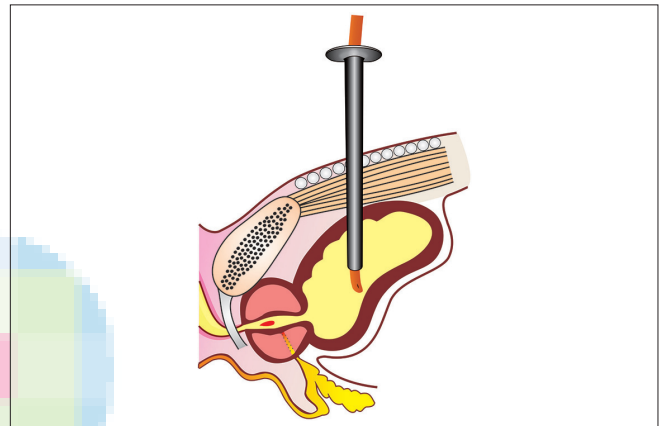
**Figure 1:** Entry of suprapubic cystostomy trocar in the bladder



**Figure 2:** Tilting of suprapubic cystostomy trocar cranially due to collapsing bladder following gush of urine outward



**Figure 3:** Trocar tip in close proximity to bladder neck, facilitating inadvertent advancement of catheter in the urethra



**Figure 4:** Keeping direction of slot toward umbilicus and slightly tilting cannula tip cephalad contribute safe placement of catheter into the lumen of bladder

choice for urinary retention when urethral catheterization of bladder is not possible or contraindicated. Intraoperative complications of trocar cystostomy range from the perivesical hemorrhage, blocking or dislodgement of catheter, transgression of the bowel etc.<sup>[1,3,4]</sup> The passage of catheter into bladder neck is another complication that happens sometime. If advanced too far, the tip may negotiate the urethra for variable distance. This causes severe irritation or failure of catheter to drain or even incontinence. Inflation of balloon at this location may further cause the urethral injury. Our modification of keeping the slotted half of trocar toward the umbilicus and keeping it straight vertical in bladder, directs the catheter upward and thus minimizes catheter malposition into the prostatic urethra. Avoidance of over insertion of the foley into bladder lumen may be of additional help. Such simple maneuvers can protect the sacred urethra from injury.

## CONCLUSION

Our simple technical amendment for directing and

positioning the trocar sheath coupled with avoidance of over insertion of foley catheter in bladder lumen can prevent the undesirable passage of foley catheter into the bladder neck and thereby in the urethra.

## REFERENCES

1. Irby PB 3<sup>rd</sup>, Stoller ML. Percutaneous suprapubic cystostomy. *J Endourol* 1993;7:125-30.
2. Goyal NK, Goel A, Sankhwar SN. Safe percutaneous suprapubic catheterisation. *Ann R Coll Surg Engl* 2012;94:597-600.
3. Lee MJ, Papanicolaou N, Nocks BN, Valdez JA, Yoder IC. Fluoroscopically guided percutaneous suprapubic cystostomy for long-term bladder drainage: An alternative to surgical cystostomy. *Radiology* 1993;188: 787-9.
4. Papanicolaou N, Pfister RC, Nocks BN. Percutaneous, large-bore, suprapubic cystostomy: Technique and results. *AJR Am J Roentgenol* 1989;152: 303-6.

**How to cite this article:** Yadav R, Dalela D, Dalela D, Kathpalia R, Goel A, Sankhwar SN. Preventing inadvertent placement of foley catheter into prostatic urethra during suprapubic trocar cystostomy: A simple face-saver trick. *J Surg Tech Case Report* 2013;5:58-9.

**Source of Support:** Nil, **Conflict of Interest:** None declared.