

Bone Suture in Management of Mandibular Degloving Injury

Amin Rahpeyma, Saeedeh Khajeahmadi¹

Department of Oral and Maxillofacial Surgery, Oral and Maxillofacial Diseases Research Center, ¹Dental Research Center, Faculty of Dentistry, Mashhad University of Medical Sciences, Mashhad, Iran

INTRODUCTION

Traumatic injuries that separate the entire anterior mandibular gingiva and alveolar mucosa from the underlying bone expose the alveolar process and mental tubercle from marginal bone down to the mandibular inferior border. As can be expected, the applied shear forces to the mentum and lower lip are responsible for this condition,^[1] whereas elective vestibular incisions, which are made in the mandibular anterior area for genioplasty, orthognathic surgeries, and trauma-treatment surgeries make two layer closure of the wound amenable.^[2] These incisions are made below the attached gingiva with a cuff of the alveolar mucosa and mentalis muscle attached to the mandible. Furthermore, supplemental lower face bandage after surgery is also recommended.

On the other hand, these ideal conditions are not present in trauma patients. In this paper, the management of a severe form of mandibular degloving injury, that leads to complete full thickness separation of soft tissue from mandible, with delay in referral and infection of the open wound, is fully discussed.

CASE REPORT

A 14-years-old male with a history of “fall” trauma, of his bicycle, experienced soft tissue injuries in the maxillofacial

ABSTRACT

Traumatic degloving injuries of the mandible are rare intraoral soft tissue traumas. A simple review of the medical literature shows that no article up to this date has reported the prevalence of the degloving injuries of the mandible. Moreover, the highest incidence of mandibular degloving injuries is reported in children and young adults. In this article, the author describes the mandibular degloving injury, characterized by the separation of periosteum and soft tissues of the anterior buccal side of the mandible, and the bone suture technique. This article outlines that a correct diagnostic assessment and appropriate treatment plan can reduce the complications after mandibular degloving injuries.

Key words: Bone suture, degloving, mandible, trauma

region. The patient, one week later, was referred to the department of Oral and Maxillofacial surgery of Mashhad's university for the management of the lacerated intraoral soft tissue wound in mandibular anterior region.

In the extraoral examination, abrasions of the nose, lips, and mentum were present. In addition, the right mandibular incisors had been avulsed. Moreover, silk suture in the lower labial vestibule, from unsuccessful attempts to repair severed mucosa, was noted. Furthermore, debris, necrotic tissue, and exposed bone were present in the vestibular depth [Figure 1].

The patient's hospital discharge card emphasized that tetanus prophylaxis has been introduced. Brain CT scans and orthopantomogram were also carried out.

After the administration of local anesthesia (lidocaine 2% with epinephrine 1/80000), debridement of necrotic soft tissue and copious irrigation with high pressure volumes of normal saline was rendered. In the next step, suturing of soft tissue was attempted. Firstly, bone between the left lower canine and lateral lower incisor root was penetrated by a surgical round bur (number 2). Secondly, 3-0 plain gut suture in 26 mm curved needle was modified to straight one so that it can be passed through this hole and exit through the lingual mucosa. By the means of this plain gut suture, the buccal soft tissue flap, 10 mm below free margin, was grasped and sutured to the lingual mucosa [Figure 2]. Likewise, the same procedure was repeated on the right side in the intact bone, apical to the avulsed lateral incisor. The suture knots were placed in the buccal vestibule.

Access this article online

Quick Response Code:



Website:

www.jstcr.org

DOI:

10.4103/2006-8808.118622

Address for correspondence: Dr. Saeedeh Khajeahmadi,
Dental Research Center, Faculty of Dentistry,
Mashhad University of Medical Sciences, Vakilabad Blvd,
Mashhad, Iran. E-mail: khajehahmadis@mums.ac.ir

Furthermore, despite of the intact remaining lower anterior teeth and supporting bone, Essig wiring technique was applied to support the mucosal free edge suturing [Figure 3]. As far as medications are concerned, clindamycin antibiotic 150 mg tabs qid was prescribed for one week. Analgesics (acetaminophen 500 mg) and chlorhexidine mouthwash were also ordered. Additionally, proper manner of tooth brushing was emphasized to the patient and parents.

The follow-up, which was carried out for one month after the treatment, has shown excellent results. Consequently, healthy gingiva without scar tissue was noticed [Figure 4].

DISCUSSION

Degloving injury occurs most commonly in lower and upper extremities whenever strong shear forces are applied. For most instances, cleavage plane is usually in

a plane between subcutaneous fat and deep fascia.^[3,4] Similarly, in the oral cavity, the term maxillary degloving applies to the special surgical incisions in maxillary vestibular mucosa and endonasal incisions that give access to the midface.^[2] Moreover, gingival degloving term is defined as soft tissue injury, in which full thickness separation of the gingiva from alveolar bone takes place.^[3] Likewise, mandibular degloving injury is a traumatic separation of the alveolar mucosa from the mandible in a full thickness manner extending to the inferior border of the mandible.^[4]

Usually, mandibular degloving injuries take place in MVAs, falls, and sport injuries, like skiing and biking. If immediate treatment of these injuries is to be considered, where soft tissues and mucosal remnants on mandibular are preserved, then primary suturing is indicated, whereas in late referral patients healing by secondary intention takes place, which is slow and accompanied with scar formation.^[4,5]

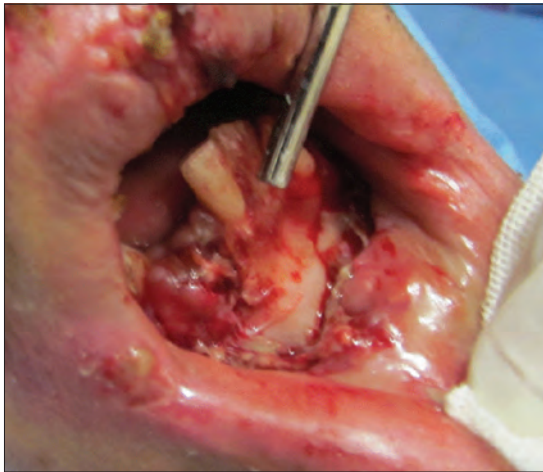

Figure 1: Complete mandibular degloving injury exposing mandibular bone from marginal bone to inferior border

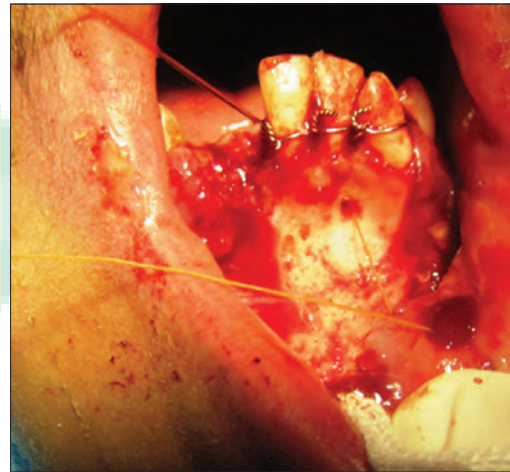


Figure 2: Bone suture of the alveolar bone between the left canine and the lateral incisor

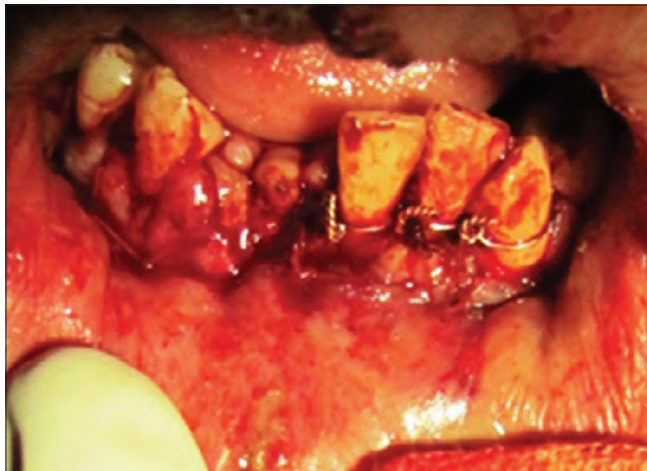


Figure 3: Essig wiring supporting the sutures. Vertical mucosal tear in the midline heals by secondary epithelialization

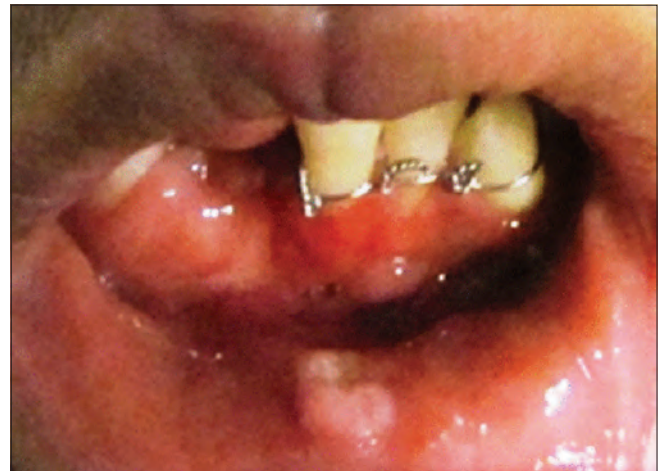

Figure 4: Four weeks after treatment; excellent healing of gingiva. Note the scar tissue in the center of the lip that healed by secondary intention

Anterior mandibular vestibular sulcus deepening and food entrapment are of the disadvantages of secondary intention wound healing in this region.

Bone suturing techniques in oral cavity operations are reported as useful aid in implant dentistry, vestibuloplasty, and cleft palate surgeries.^[6,7]

CONCLUSION


There are few reported cases of mandibular degloving injuries in the medical literature. Nevertheless, the authors experience in a trauma center points out that the prevalence of this condition is much more than that reported. The case previously mentioned shows the difficulty of primary suturing in the mandibular degloving injuries. Correspondingly, conventional methods of suturing degloving injuries were not successful. Alternatively, bone suturing with Essig wiring technique for primary healing has shown better results and, therefore, it is obviously more recommended.

REFERENCES

1. Dula DJ, Leicht MJ, Moothart WE. Degloving injury of the mandible. *Ann Emerg Med* 1984;13:630-2.
2. Mommaerts MY, Van Hemelen G, Sanders K, Vander Sloten J, Van Brussel K, Abeloos JV, et al. High labial incisions for genioplasty. *Br J Oral Maxillofac Surg* 1997;35:398-400.
3. Shockledge R, Mackie I. Oral soft tissue trauma: Gingival degloving. *Endod Dent Traumatol* 1996;12:109-11.
4. McLaughlin PP. Degloving injury to mental protuberance: A case report. *Int J Paediatr Dent* 2000;10:234-6.
5. Revuelta R, Sándor GK. Degloving injury of the mandibular mucosa following an extreme sport accident: A case report. *J Dent Child (Chic)* 2005; 72:104-6.
6. Motamedi MH, Shafeie HA. Technique to manage simultaneously impacted mandibular second and third molars in adolescent patients. *Oral Surg Oral Med Oral Pathol Oral Radiol Endod* 2007;103:464-6.
7. Hwang K, Lee JH, Kim YJ, Le SI. Palatoplasty: Suturing the mucoperiosteal flaps to the hard palate through hole. *J Craniofac Surg* 2009; 20:916-7.

How to cite this article: Rahpeyma A, Khajeahmadi S. Bone suture in management of mandibular degloving injury. *J Surg Tech Case Report* 2013;5:35-7.

Source of Support: Nil, **Conflict of Interest:** None declared.



Author Help: Online submission of the manuscripts

Articles can be submitted online from <http://www.journalonweb.com>. For online submission, the articles should be prepared in two files (first page file and article file). Images should be submitted separately.

- 1) **First Page File:**
Prepare the title page, covering letter, acknowledgement etc. using a word processor program. All information related to your identity should be included here. Use text/rtf/doc/pdf files. Do not zip the files.
- 2) **Article File:**
The main text of the article, beginning with the Abstract to References (including tables) should be in this file. Do not include any information (such as acknowledgement, your names in page headers etc.) in this file. Use text/rtf/doc/pdf files. Do not zip the files. Limit the file size to 1 MB. Do not incorporate images in the file. If file size is large, graphs can be submitted separately as images, without their being incorporated in the article file. This will reduce the size of the file.
- 3) **Images:**
Submit good quality color images. Each image should be less than 4096 kb (4 MB) in size. The size of the image can be reduced by decreasing the actual height and width of the images (keep up to about 6 inches and up to about 1800 x 1200 pixels). JPEG is the most suitable file format. The image quality should be good enough to judge the scientific value of the image. For the purpose of printing, always retain a good quality, high resolution image. This high resolution image should be sent to the editorial office at the time of sending a revised article.
- 4) **Legends:**
Legends for the figures/images should be included at the end of the article file.