

Primary Tuberculosis of the Appendix: A Rare Cause of a Common Disease

B. J. Sharath Chandra, T. U. Girish, P. B. Thrishuli, H. G. Vinay

Department of General Surgery, JSS Medical College Hospital, JSS University, Mysore, Karnataka, India

INTRODUCTION

Tuberculosis (TB) is a major public health problem in developing countries like India. India accounts for one-fifth of the global TB incident cases.^[1] Gastrointestinal TB accounts for 3% of extra pulmonary TB, the most common site of involvement being the ileocaecal region. However, involvement of the appendix, lying so close to the ileocaecal region is rare. Primary TB of the appendix presenting as appendicular abscess is even rarer with incidence of 0.1-0.6%.^[2] Because of its rarity and absence of any specific clinical and radiological finding, diagnosis is made only after histopathological examination of the appendectomy specimen. In our review of cases, for 3 years, we report our experience with tuberculous appendicitis in a tertiary center in a nation where TB is still endemic.

CASE REPORT

A 20-year-old male patient presented to our outpatient department with complaints of colicky type of pain in right lower abdomen, associated with vomiting and fever since 5 days. On examination, patient was febrile and his vitals were normal. The physical examination showed marked tenderness in right iliac fossa. On initial work up, patients leukocyte count was 17,600/mm³. Since these symptoms

ABSTRACT

Tuberculosis is still a common infection in India. Although the ileocecal region is the most affected part in intestinal tuberculosis, acute tuberculous appendicitis is quite a rare entity. Our case report highlights a rare presentation of tuberculosis and a brief review of literature.

Key words: Appendix, granuloma, tuberculosis

were consistent with appendicitis, patient was taken for emergency surgery. On laparotomy, a diffuse inflammatory mass and abscess of the appendix [Figure 1] was found and appendectomy was done. Exploration of the bowel and mesentery, through the grid iron incision showed normal ileum, cecum, and mesentery. In post-operative period, he had wound infection, which was managed by regular dressing. Histopathological examination of the appendix revealed caseating epithelioid granulomas and lumen filled with neutrophilic infiltrates [Figures 2 and 3]. Patient was later evaluated for primary source of TB else where in the body. Computed tomography (CT) abdomen and pelvis showed normal bowel loops and mesentery [Figure 4]. Chest X-ray and colonoscopy [Figures 5 and 6] were normal. Three consecutive early morning sputum sample were negative for acid fast bacilli. Tuberculin skin test was negative and erythrocyte sedimentation rate (ESR) was 80 mm/h. Patient was started on standard anti-TB drugs, course similar to pulmonary TB.

DISCUSSION

Tubercular appendicitis is a rare manifestation, with occasional case reports in literature. It was first recognized by Corbin^[3] in 1873. In 1896 Deaver^[4] reported 16 cases of tubercular appendicitis in his series of 7610 appendectomies, Mayo in 1905 reported 29 (1888 appendectomies), Allen reported 2 (89 appendectomies), and Scott^[5] in 1917, 1 case out of 179 appendectomies. In recent studies, Shah *et al.*,^[5] reported 10 cases of tubercular appendicitis over a period of 10 years, Dymock *et al.*,^[6] 2 cases in an analysis of 1000 appendectomy specimens. In a review of 2921 appendectomies carried out in a tertiary center in India, only 2.3% of cases were tubercular appendicitis.^[7] In our

Access this article online

Quick Response Code:



Website:

www.jstcr.org

DOI:

10.4103/2006-8808.118619

Address for correspondence: Dr. H. G. Vinay,
Department of General Surgery, JSS Medical College Hospital,
JSS University, Mysore - 570 004, Karnataka, India.
E-mail: vinay_1771@yahoo.co.in

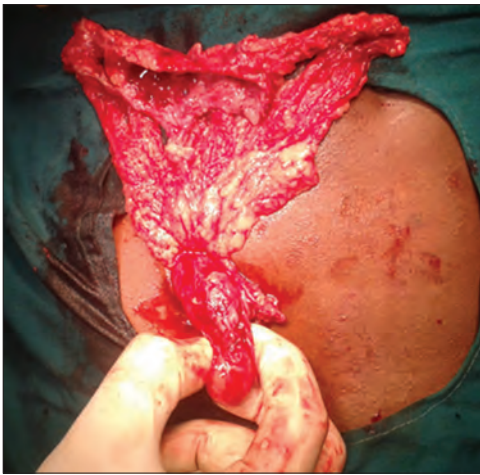

Figure 1: Intraoperative photograph of inflamed appendix with mass

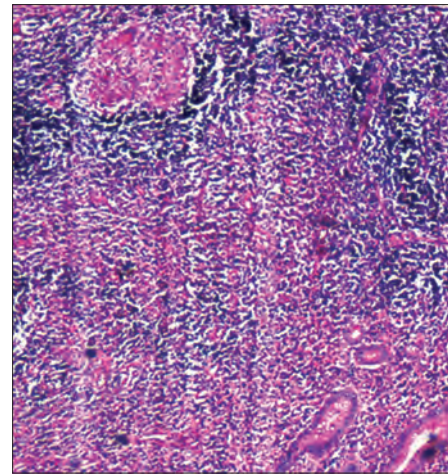


Figure 2: Histopathology showing epithelioid granuloma with Langhans giant cells and neutrophilic infiltrate in the lumen of appendix (x4 magnification)

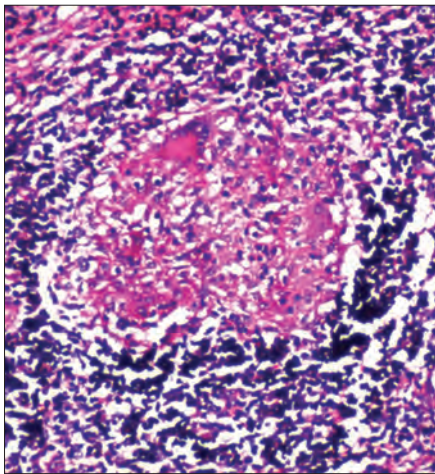


Figure 3: Histopathology showing epithelioid granuloma with Langhans giant cells and neutrophilic infiltrate in the lumen of appendix (x10 magnification)

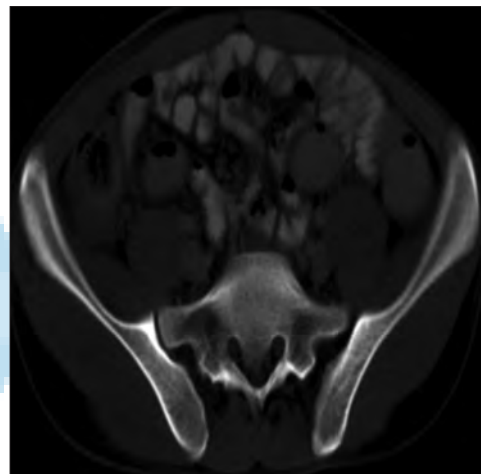


Figure 4: CT photograph showing normal abdomen

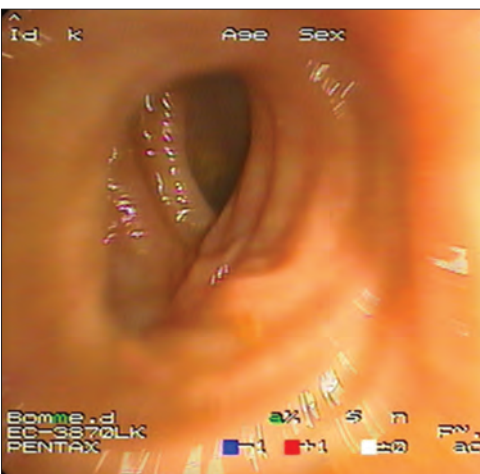


Figure 5: Colonoscopy photo showing normal ileum

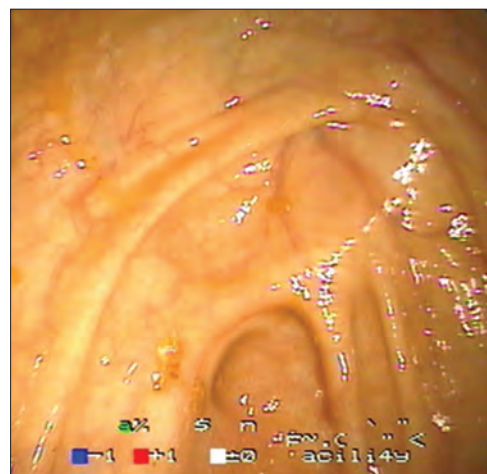


Figure 6: Colonoscopy photo showing normal caecum

practice, for 4 years, we reported one case of tuberculous appendicitis out of 229 cases operated for appendicitis.

TB may affect primarily all organs and tissues of the body. The most common forms of non-pulmonary TB are TB of bones

and joints (30%), urinary system (24%), lymph nodes (13%), sexual organs (8%), cerebrospinal meninges (4%), and alimentary system (3%). Appendicular TB can occur as a primary or secondary form: The first form is due to a primary infection of the intestinal mucosa by *Mycobacterium bovis*; the second form is usually a consequence and complication of primary pulmonary TB by *M. tuberculosis*. The infection of appendix by tuberculous bacillus can occur by local extension of ileocaecal or genital TB, hematogenous spread from a distant focus and contact with infected intestinal contents due to ingestion of food contaminated with tubercle bacilli.^[2]

The disease can present either as a chronic disease with recurrent episodes of fever, weight loss, right iliac fossa pain or as acute appendicitis, a latent type that is detected incidentally.^[2,8] The acute presentation occurs due to severe pyogenic infection that is superimposed on the tubercular appendix. This type of presentation is seen during the quiescent phase of pulmonary TB, if present.^[2] The presence of chronic abdominal pain of long duration in young adults, pulmonary TB, poor nutritional status and loss of weight, and the presence of chronic diarrhea have been said to be indicative of TB of the appendix,^[5,9] but these symptoms are of doubtful value. Since there are no clinical and radiological features that are pathognomonic of appendicular TB, diagnosis is usually made after histopathological examination of the appendectomy specimen.

Based on histopathology, TB appendix can be described as ulcerative (commonest form), hyperplastic and ulcer-hyperplastic form. Other causes of granulomatous appendicitis include parasite-related appendicitis, Crohn's disease, sarcoidosis and foreign body-induced inflammation.^[7] Signs and symptoms are nonspecific and similar to those of several other chronic abdominal diseases or it may simulate an acute appendicitis such as the present case. The diagnosis of a secondary localization by a pulmonary infection is usually simpler since the radiological aspects of pulmonary TB are often characteristic. Further evaluation is required to rule out primary intestinal TB. High levels of adenosine deaminase (ADA) in the ascitic fluid in peritoneal TB have been shown to be compatible with the diagnosis of TB^[10,11] with high sensitivity (100%) and specificity (97%). Ultrasound abdomen scan can be useful in detecting ascites and mesenteric lymph nodes.^[12]

Determination of serum CA-125 concentration can be used in tuberculous peritonitis, not only to make an accurate diagnosis and ascertain the activity of the disease but also to follow the response to treatment.^[13] The most accurate diagnostic alternative to surgery is endoscopic biopsy of the lesions, which depends on the localization of lesions. Histopathology shows caseating epithelioid cell granuloma with Langhan's giant cells.

Surgery followed by anti-tubercular therapy is the treatment of choice. Supplement with corticosteroid is required if associated with peritoneal TB. Standard anti-TB treatment with four antituberculous drugs (isoniazid 5 mg/kg/day, rifampicin 10 mg/kg/day, pyrazinamide 30 mg/kg/day, and ethambutal 20 mg/kg/day) for two months followed by isoniazid and rifampicin for 4 months is advocated.

REFERENCES

1. Available from: <http://whoindia.org/en/Section3/Section123.htm> [Last accessed on 2012 Dec].
2. Bobrow ML, Friedman S. Tubercular appendicitis. *Am J Surg* 1956;91:389-93.
3. Scott JR. Tuberculosis of the Appendix. *Ann Surg* 1917;66:648-53.
4. Deaver JB. A treatise on appendicitis. Philadelphia: P. Blakiston and Son; 1896. p. 186.
5. Shah RC, Mehta KN, Jalunhwala JM. Tuberculosis of the appendix. *J Ind Med Assoc* 1967;49:138-40.
6. Dymock RB. Pathological changes in the appendix. A review of 1000 cases. *Pathology* 1977;9:331-9.
7. Gupta SC, Gupta AK, Keswani NK, Singh PA, Tripathi AK, Krishna V. Pathology of tropical appendicitis. *J Clin Pathol* 1989;42:1169-72.
8. Singh MK, Arunabh, Kapoor VK. Tuberculosis of the appendix: A report of 17 cases and a suggested aetiopathological classification. *Postgrad Med J* 1987;63:855-7.
9. Drissen EM, Zollinger R. Acute tuberculous appendicitis. *Ann Surg* 1935;101:740-5.
10. Rasheed S, Zinicola R, Watson D, Bajwa A, McDonald PJ. Intra-abdominal and gastrointestinal tuberculosis. *Colorectal Dis* 2007;9:773-83.
11. Riquelme A, Calvo M, Salech F, Valderrama S, Pattillo A, Arellano M, *et al.* Value of adenosine deaminase (ADA) in ascitic fluid for the diagnosis of tuberculous peritonitis: A meta-analysis. *J Clin Gastroenterol* 2006;40:705-10.
12. Dinler G, Sensoy G, Helek D, Kalayci AG. Tuberculous peritonitis in children: Report of nine patients and review of the literature. *World J Gastroenterol* 2008;14:7235-9.
13. Mas MR, Cömert B, Sağlamkaya U, Yamanel L, Kuzhan O, Ateşkan U. CA-125: A new marker for diagnosis and follow-up of patients with tuberculous peritonitis. *Dig Liver Dis* 2000;32:595-7.

How to cite this article: Sharath Chandra BJ, Girish TU, Thrishuli PB, Vinay HG. Primary tuberculosis of the appendix: A rare cause of a common disease. *J Surg Tech Case Report* 2013;5:32-4.

Source of Support: Nil, **Conflict of Interest:** None declared.