

CASE  
REPORT

## The Use of a Nasolabial Island Flap in Vestibulo-sulcoplasty in a Patient with Recurrent Depressed Scar on the Modiolus

Umut Tuncel, Aydın Turan, Naci Kostakoğlu

Department of Plastic Reconstructive and Aesthetic Surgery,  
Gaziosmanpasa University, Faculty of Medicine 60100, Tokat,  
Turkey

### INTRODUCTION

The defects of the anterior oral cavity or the floor of the mouth may lead to significant functional and cosmetic problems. If the defect is under 2 cm in size, it may be effectively treated with primary closure. However, if it is larger, it may require local or distant flaps. Tongue, buccal mucosa, or other regional flaps have been used to solve the problem. Tongue flaps may interfere with the normal tongue mobility. Regional flaps are widely used to address the problem, but sometimes they may be too bulky for small defects.<sup>[1]</sup>

The nasolabial flap is a type C fasciocutaneous flap, based on the underlying angular artery.<sup>[2]</sup> Advantages of the flap are relatively easy and it is a short operative procedure compared to other reconstructive techniques, also the donor site morbidity is minimal.<sup>[3,4]</sup> The flap has widely been used in the reconstruction of the lip and floor of the mouth, however, there are few reports on the usage of this method in the reconstruction of the anterior oral cavity.<sup>[2]</sup> We hereby present this patient as a good example for the versatility of the nasolabial flap in anterior oral cavity defects.

### CASE REPORT

A 56-year-old woman presented with a scar in the

Access this article online	
Quick Response Code: 	Website: <a href="http://www.jstcr.org">www.jstcr.org</a>
	DOI: 10.4103/2006-8808.100358

**Address for correspondence:** Dr. Umut Tuncel,  
Department of Plastic Reconstructive and Aesthetic Surgery,  
Gaziosmanpasa University, Faculty of Medicine 60100, Tokat,  
Turkey. E-mail: [drumuttuncel@gmail.com](mailto:drumuttuncel@gmail.com)

### ABSTRACT

A 56-year-old woman with a recurrent depressed scar of the commissure, treated with a nasolabial island flap, is presented. On examination, the scar was located on the right modiolus involving the right upper gingivobuccal sulcus. A history of recurrent canine abscess was obtained. After excision of the scar and release of the vestibular fold, reconstruction of the defect was performed with a nasolabial island flap from the same side. The postoperative course was uneventful, with a good aesthetic and functional outcome.

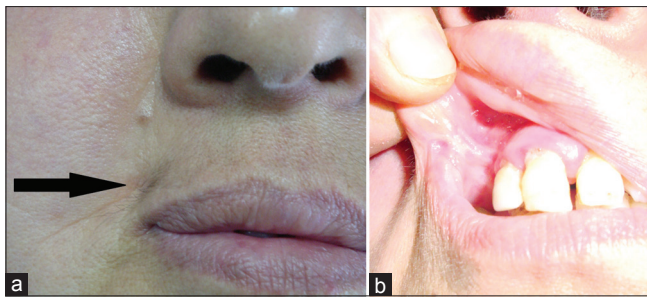
**Key words:** Gingivobuccal sulcus, island, modiolus, nasolabial flap, scar

right upper gingivobuccal sulcus, involving the right commissure of the mouth [Figure 1a and b]. In the history, she had a recurrent dental abscess after using a dental prosthesis, and she had a purulent wound on the right modiolus, involving the right upper gingivobuccal sulcus. She was previously operated twice for the same deformity elsewhere. In the first operation, a dermal fat graft was used. On account of the poor take of the graft, a second operation was performed combining the release of the contracture with a skin graft and lipofilling the depression in the soft tissue. This again failed to give a satisfactory result.

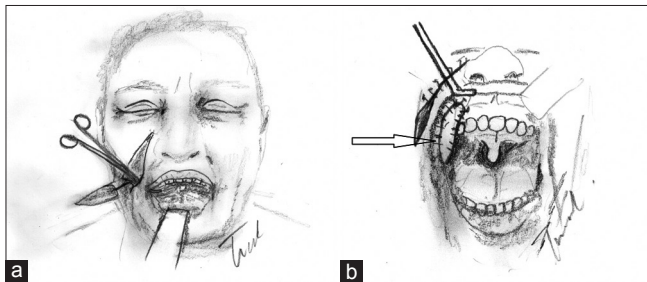
In our operation, after release of the scar, a nasolabial flap with a diameter of 2 cm was prepared on the same side [Figure 2a]. The flap was tunneled to fill up the defect, just superior to the commissure [Figure 2b]. The donor site was closed primarily without tension. After inset of the flap, the operation was concluded. The postoperative course was uneventful, neither flap necrosis nor infection developed. Three months postoperatively, the appearance of the flap in the mouth was good and aesthetic, and the functional outcome was satisfactory [Figure 3a and b].

### DISCUSSION

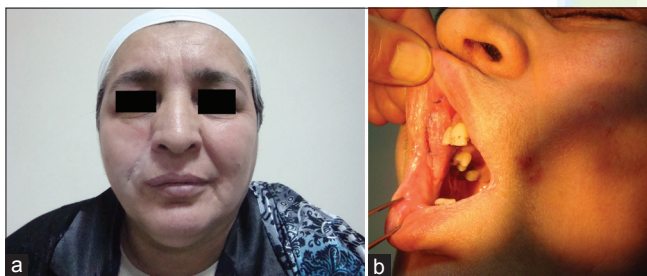The nasolabial flap has widely been used for an intermediate-sized defect of the cheek, upper and lower lip, palate, and especially, the anterior floor of the mouth.



**Figure 1:** (a,b) A 56-year-old woman presented with a scar in the right upper gingivobuccal sulcus, involving the right commissure of the mouth



**Figure 2:** (a) During the operation, after release of the scar a nasolabial flap with a diameter of 2 cm was prepared on the same side. (b) The flap was tunneled to fill up the defect, just superior to the commissure. The tunnel from the cheek skin through the buccal mucosa was made by blunt scissor dissection



**Figure 3:** (a) Early postoperative result at one month. Some edema is present around the modiolus. (b) The appearance of the flap in the mouth was considered to be satisfactory

The main advantages of the flap in facial reconstruction are its accessibility, ease of dissection, good color match, and minimal donor site morbidity. Evaluation of the depth of the sulcus is important for the mobility of the tongue, which is paramount in proper speech, therefore, integrity of the sulcus and sufficient reconstruction is necessary.

For larger defects of the floor of the mouth, it may be necessary to use a submental flap, platysmamyocutaneous flap, buccal mucosa flap, or a free flap.<sup>[5]</sup> However, especially in the case smaller-to-medium size defects that do not cross the midline, a nasolabial flap can be a sound option.<sup>[2]</sup> In our patient, the nasolabial flap was chosen as the best option for reconstruction, because of the limited size of the defect. The patient had no complaint when chewing or drinking postoperatively. She was able to speak clearly and the recurrent depressed scar was reconstructed satisfactorily.

One of the advantages of the nasolabial flap is its good vascularity. The flap is reliable even after facial artery ligation. Napolitano and Mast<sup>[6]</sup> have stressed the rich collateral blood supply of the cheek, deriving from the masseteric, buccal, infraorbital, and transverse facial arteries, and they have found the nasolabial flap to be quite reliable.

Conventional vestibuloplasty techniques require repositioning of the supportive musculature and adjacent mucosa, followed by resurfacing with a skin graft. Three basic treatment philosophies exist in vestibuloplasty; (1) submucosal vestibuloplasty, (2) secondary epithelialization vestibuloplasty, and (3) soft-tissue grafting vestibuloplasty.<sup>[7]</sup> Submucosal vestibuloplasty can be performed easily under local anesthesia, however, the outcomes are poor, because of the high incidence of relapse. Secondary epithelialization techniques rely on delayed healing of a remucosalized and denuded area. The Kazanjian vestibuloplasty, also known as the 'lip-switch,' involves utilization of a bipedicle labial mucosal flap, to resurface the prepared alveolus to the depth of the neovestibule. The labial component of the vestibule is left to heal secondarily. This technique is used mainly in the anterior mandibular region, but can be applied to the anterior maxilla as well.<sup>[8]</sup> A similar technique, the Edlan vestibuloplasty, places an incision at the alveolus, and supraperiosteal dissection is performed anteriorly, preserving a pedicled mucosal flap at the level of the lip. This mucosal flap is used to resurface the labial surface of the vestibule, and the alveolar component is left to heal secondarily.<sup>[9]</sup> The inherent problem with secondary epithelialization vestibuloplasty is the uninhibited wound contracture and relapse through loss of vestibular depth.

Understanding the principles of wound healing associated with this concept led to the development of soft-tissue grafting vestibuloplasty. Contemporary reconstruction of the oral vestibule is performed using keratinized or non-keratinized mucosa or split-thickness skin grafts applied to a de-epithelialized alveolar ridge.<sup>[10]</sup> In the present case, similar vestibuloplasties were attempted twice elsewhere, however, they failed to give a satisfactory result. We considered using a nasolabial flap in our patient, as the defect that occurred after release of the scar was not large. A possible disadvantage of the technique is that occasionally rotation of the hair-bearing tissue into the oral cavity is possible in the male.

In conclusion, the inferiorly based nasolabial island flap was found to be a good method, providing thin and pliable soft tissue coverage. The flap satisfactorily reconstructed the commissure and vestibular contracture. We recommend the utilization of the nasolabial flap in


reconstruction of small-to-medium sized defects of the anterior oral cavity.

## REFERENCES

1. Ikeda C, Katakura A, Yamamoto N, Kamiyama I, Shibahara T, Onoda N, *et al.* Nasolabial flap reconstruction of floor of mouth. *Bull Tokyo Dent Coll* 2007;48:187-92.
2. Hofstra EI, Hofer SO, Nauta JM, Roodenburg JL, Lichtendahl DH. Oral functional outcome after intraoral reconstruction with nasolabial flaps. *Br J Plast Surg* 2004;57:150-5.
3. Cohen IK, Edgerton MT. Transbuccal flaps for reconstruction of the floor of the mouth. *Plast Reconstr Surg* 1971;48:8-10.
4. Cohen IK, Theogaraj SD. Nasolabial flap reconstruction of the floor of the mouth after extirpation of oral cancer. *Am J Surg* 1975;130:479-80.
5. Rudkin GH, Carlsen BT, Miller TA. Nasolabial flap reconstruction of large defects of the lower lip. *Plast Reconstr Surg* 2003;111:810-7.
6. Napolitano M, Mast BA. The nasolabial flap revisited as an adjunct to floor-of-mouth reconstruction. *Ann Plast Surg* 2001;46:265-8.
7. St-Hilaire H, Mithani SK, Rodriguez ED. Microsurgical salvage of the intractable oral vestibule. *Plast Reconstr Surg* 2009;123:331-8.
8. Kazanjian VH. Surgery as an aid to more efficient service with prosthetic dentures. *J Am Dent Assoc* 1935;22:340.
9. Hillerup S, Solow B. Soft tissue profile changes after mandibular vestibuloplasty: A two-year follow up study comparing the Edlan flap, mucosal and skin graft methods. *Int J Oral Maxillofac Surg* 1990;19:12-7.
10. Froschl T, Kerscher A. The optimal vestibuloplasty in preprosthetic surgery of the mandible. *J Craniomaxillofac Surg* 1997;25:85-90.

**How to cite this article:** Tuncel U, Turan A, Kostakoglu N. The use of a nasolabial island flap in vestibulo-sulcoplasty in a patient with recurrent depressed scar on the modiolus. *J Surg Tech Case Report* 2012;4:58-60.

**Source of Support:** Nil, **Conflict of Interest:** The authors have no conflict of interest. We have no a financial relationship with the organization that sponsored the research.



### Announcement

#### Android App



Download  
**Android  
application**

FREE

A free application to browse and search the journal's content is now available for Android based mobiles and devices. The application provides "Table of Contents" of the latest issues, which are stored on the device for future offline browsing. Internet connection is required to access the back issues and search facility. The application is compatible with all the versions of Android. The application can be downloaded from <https://market.android.com/details?id=comm.app.medknow>. For suggestions and comments do write back to us.