

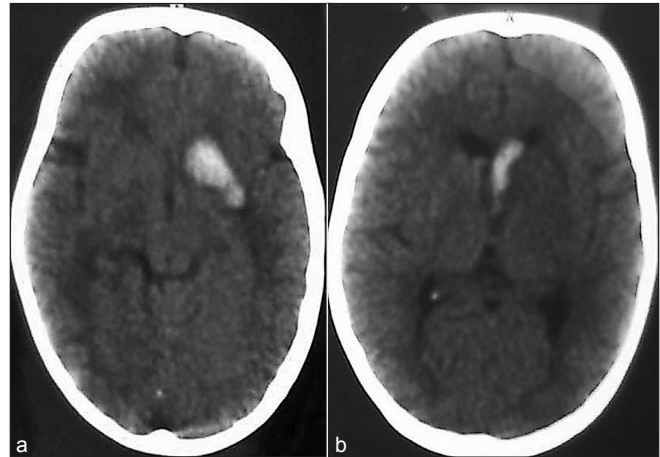
## Subarachnoid Hemorrhage in a Three-year-old-boy with Left Middle Cerebral Artery Aneurysm

Sir,

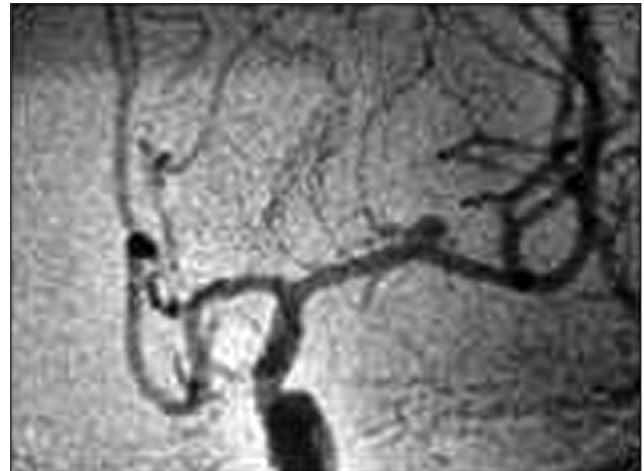
Intracranial aneurysms in the pediatric population (18 years old or younger) are rare, with reported prevalence ranging from 0.5 to 4.6%.<sup>[1]</sup> Intracranial aneurysms arising in early childhood (less than six years) are still rarer.<sup>[2]</sup>

We report a case of three-year-old boy, who presented with a history of sudden onset of headache and vomiting. Neurologically he was conscious, oriented, and with no neurological deficits (Hunt and Hess grade-2) at the time of admission. Computed Tomography (CT) scan of the brain revealed intracerebral hemorrhage [Figure 1a] and intraventricular hemorrhage [Figure 1b]. Four-vessel cerebral angiogram revealed left middle cerebral artery aneurysm in the M-1 segment [Figure 2]. Left pterional craniotomy and clipping of the aneurysm was done. The postoperative period was uneventful and the patient was discharged on the eighth postoperative day without any neurological deficit. At 55 month follow-up, his Glasgow Outcome scale score was 5 and he had no functional or cognitive deficit.

Pediatric cerebral aneurysms differ from adults, having male predilection, higher incidence of giant aneurysms, location at the internal carotid artery (ICA) bifurcation or posterior circulation, and less incidence of vasospasm.<sup>[2]</sup> The male / female ratio has been reported as 1.8 : 1, with the internal carotid artery (ICA) bifurcation accounting for 26% of the aneurysms in a review article.<sup>[1]</sup> Posterior circulation aneurysms are three times more common in children than in adults.<sup>[2]</sup> A higher incidence of middle cerebral artery aneurysms in the early childhood group has been noted.<sup>[2]</sup> Large size and giant aneurysms are more common in children than in adults, with the proportion increasing in the early childhood group up to 20 and 30%, respectively.<sup>[2]</sup> The exact pathophysiological mechanism of aneurysm formation is not known, although trauma, infection, and congenital disorders have been associated with few of these cases. In the author's experience of 90 intracranial aneurysms, the present case is the only one in the early childhood category. Treatment of aneurysms can be either by surgical clipping or by coiling.<sup>[3-5]</sup> Surgical dissection in children is different when compared to that in adults, as the sylvian fissure is not fully developed in them.



**Figure 1:** CT brain showing (a) intracerebral hemorrhage (b) intraventricular hemorrhage



**Figure 2:** Cerebral angiogram showing left middle cerebral artery aneurysm (M-1 segment)

Children seem to tolerate surgery better than adults, and with less incidence of vasospasm, majority of them have a good postoperative outcome.

**Rajesh K. Ghanta, Ameen Mohammad**

Department of Neurosurgery, Suraksha Hospital,  
Vijayawada, Andhra Pradesh, India  
E-mail: ghantarajesh@yahoo.co.in

### REFERENCES

- Huang J, McGirt MJ, Gailloud P, Tamargo RJ. Intracranial aneurysms in the pediatric population: Case series and literature review. *Surg Neurol* 2005;63:424-32.
- Aryan HE, Giannotta SL, Fukushima T, Park MS, Ozgur BM, Levy ML. Aneurysms in children: Review of 15 years experience. *J Clin Neurosci*

2006;13:188-92.

3. Mazza C, Pasqualin A, Da Pian R, Pezzotta S. Intracranial aneurysms and subarachnoid hemorrhage in children and adolescents. *Minerva Med* 1986;77:1145-51.
4. Sanaï N, Quinones-Hinojosa A, Gupta NM, Perry V, Sun PP, Wilson CB, *et al.* Pediatric intracranial aneurysms: Durability of treatment following microsurgical and endovascular management. *J Neurosurg* 2006;104:82-9.
5. Varela M, Gavra M, Andreou A, Karagianni I, Alexiou GA. Subarachnoid hemorrhage secondary to ruptured posterior communicating artery aneurysm in a child. *Childs Nerv Syst* 2011;27:1015-7.

Access this article online

Quick Response Code:



Website:

[www.jstcr.org](http://www.jstcr.org)

DOI:

10.4103/2006-8808.92807