

Unusual Giant Prostatic Urethral Calculus

A. Bello, H. Y. Maitama, N. H. Mbibu, G. D. Kalayi, A. Ahmed

Division of Urology, Ahmadu Bello University Teaching Hospital [ABUTH], Shika-Zaria, Nigeria

INTRODUCTION

Large stones in the prostatic cavity are uncommon, the usual varieties being those associated with chronic calculus prostatitis, or small multiple concretions corresponding to the corpora amylacea. Prostatic parenchymal calculi are usually incidental findings on a computed tomographic (CT) scan or transrectal ultrasound. They are typically asymptomatic and may be associated with benign prostatic hyperplasia, and prostatic cancer.^[1] Primary prostatic urethral calculi are usually associated with urethral strictures, posterior urethral valve or diverticula. Acute urinary retention might result secondary to a large urethral calculus.^[2] While urinating, a patient with a urethral calculus might experience a sudden stop, and therefore, be unable to empty the bladder.^[3] We report a case of a giant vesico-prostatic urethral stone causing sepsis and bladder outlet obstruction that was managed by open surgery, with a satisfactory outcome.

CASE REPORT

A 32-year-old male trader, referred from a peripheral hospital to our Emergency Department, presented with difficulty in passing urine since childhood, characterized by irritative and obstructive lower urinary tract symptoms. Occasionally there was associated pain on micturition with painful initial hematuria and urethral discharge. There was a history of recurrent urinary tract infection, but no history of passage of stone in the urine. He developed an inability to pass urine, necessitating presentation to the referring hospital, where urethral catheterization was attempted, but failed, and he subsequently had vesical exploration and a huge vesical stone was removed. He developed leakage of urine from the operating wound, necessitating referral. A Physical Examination revealed a febrile (38°C) young man, with a transverse suprapubic scar and a midline vesicocutaneous fistula, discharging turbid urine. Digital rectal examination revealed a huge stony hard

Address for correspondence: Dr. A. Bello, Division of Urology, Ahmadu Bello University Teaching Hospital [ABUTH] Shika-Zaria, Nigeria. E-mail: abellokarfi@yahoo.com

ABSTRACT

Giant vesico-prostatic urethral calculus is uncommon. Urethral stones rarely form primarily in the urethra, and they are usually associated with urethral strictures, posterior urethral valve or diverticula. We report a case of a 32-year-old man with giant vesico-prostatic (collar-stud) urethral stone presenting with sepsis and bladder outlet obstruction. The clinical presentation, management, and outcome of the giant prostatic urethral calculus are reviewed.

Key words: Collar-stud (vesico-prostatic), giant, obstruction, prostatic calculus

DOI: 10.4103/2006-8808.63721

mass in the region of the prostate, with smooth overlying rectal mucosa. A diagnosis of bladder outlet obstruction secondary to posterior urethral valves (PUV), with a prostatic urethral calculus was made.

A plain X-ray of the kidney, ureter, and bladder (KUB), showed a huge stone in the region of the prostatic urethra [Figure 1] and an abdominal ultrasound and urography showed bilateral hydronephrosis and a prostatic urethral stone. The urine culture grew *Escherichia coli*, which was treated based on sensitivity. The serum biochemistry was normal and a complete blood count revealed anemia and leucocytosis.

He was resuscitated with intravenous fluids and antibiotics

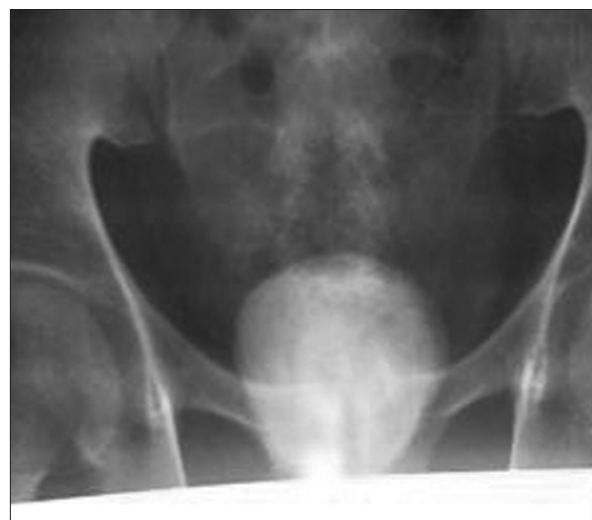

Figure 1: Plain pelvic X-ray showing prostatic urethral calculus

and the urine was diverted by suprapubic cystostomy. He later had transvesical prostate-urethrolithotomy facilitated by bladder neck incision, with the stone being manipulated bimanually, until it was delivered into the bladder, removed, and sent for analysis. The prostatic urethral stone in this patient was 7.0 cm × 6.5 cm × 6.0 cm and irregular shaped [Figure 2], while the bladder extension was round and 8.2 cm in diameter. The bladder neck was reconstructed and a urethral catheter left *in-situ*. Urethrocystoscopy was done and the valves were not visualized. A micturating cystourethrogram, (MCUG) done three weeks after the surgery revealed a huge cavity in the prostatic urethra, with vesicoureteric reflux. Subsequently the patient was able to void satisfactorily.

DISCUSSION

Urethral calculi are generally classified as native (those formed *de novo* in the urethra) or migratory (those formed in the bladder or kidney with secondary descent).^[2] Young divides the first type into four groups:^[3]

- Group I. Prostatic calculi associated with prostatitis
- Group II. Prostatic calculi associated with hypertrophy of the gland
- Group III. Prostatic calculi that simulate carcinoma
- Group IV. Calculi in both the prostatic urethra and the urinary tract

Swift Joly in his description of the stones lodged in the posterior urethra mentions three different conditions, which come under this heading, and distinguishes them as follows:^[4]

- a) Vesicourethral stones: These stones lie partly in the posterior urethra and partly in the bladder, and therefore lie astride the internal sphincter, the muscle that usually causes a constriction, clearly visible on the calculus.
- b) Urethral stones: These stones are localized to the urethra.
- c) Urethro-prostatic stones: These stones lie partly in the pre-formed cavity in the prostate gland.

The stone in this patient is vesicourethral (Young type IV, Jolly type a) *De novo* urethral stones are generally composed of magnesium ammonium phosphate (struvite).^[5] In contrast, migratory stones are often composed of calcium phosphate or calcium oxalate. The composition of the stone in our patient is magnesium ammonium phosphate. The possible etiological factors can be urethral stricture, stasis, or stagnation, with urinary infection, foreign bodies, debris, bladder neck obstruction, idiopathic factors, lithogenic diathesis, and schistosomiasis.^[6] Less than 20 cases of giant prostatic urethral calculi have been reported

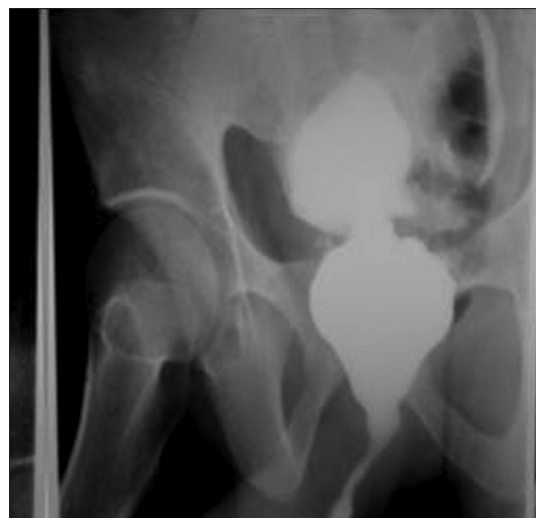

Figure 2: Micturating cystourethrogram (MCUG) showing huge prostatic cavity

in the English literature. They occur more frequently in younger men, unlike microscopic prostatic calculi, which are usually seen in men older than 50 years of age.^[7,8] This is the first case in our center and probably the largest giant collar-stud prostatic urethral calculus in English literature.

The main symptoms were acute urinary retention, frequency, burning sensation in the urethra on urination, burning sensation in the perineum and/or rectum, or stinging in the anus. Other less frequent symptoms were hematuria, dribbling or incontinence, interruption of the urinary stream, and a history of having passed a stone.^[9] Potential complications included bleeding, incontinence, impotence, and stricture formation.^[2] This patient presented with lower urinary tract symptoms, which cumulated in acute urinary retention.

Treatment was influenced by the size, shape, and the position of the calculus and status of the urethra. The stone in this patient was treated by open transvesical prostatolithotomy, bladder neck incision, and bladder neck reconstruction. The patient had good urinary stream and no retrograde ejaculation. Other methods of management of the giant prostatic calculus included radical prostatectomy, open retropubic prostatolithotomy and endoscopic lithotripsy.^[9]

This case was reported because of the size and the collar-stud nature of the stone. Giant urethral calculi should be treated with open surgery.


REFERENCES

1. Klimas R Bennett B, Gardner WA Jr. Prostatic calculi: A review. *Prostate* 1985;7:91-6.

Bello, *et al.*: Unusual giant prostatic urethral calculus

2. Shanmugam TV, Dhanapal V, Rajaraman T, Chandrasekar CP, Balashanmugam KP. Giant urethral calculi. *Hosp Med* 2000;61:582.
3. Young H. Prostatic urethral calculi. *J Urol* 1934;32:660.
4. Barrett JC. Giant prostatic calculi. *Br J Surg* 1957;45:267-9.
5. Usta MF, Baykara M, Erdoğan T, Köksal IT. Idiopathic prostatic giant calculi in a young male patient. *Int Urol Nephrol* 2005;37:295-7.
6. Larkin GL, Weber JE. Giant urethral calculus: A rare cause of acute urinary retention. *J Emerg Med* 1996;14:707-9.
7. Gawande AS, Kamat MH, Seebode JJ. Giant prostatic calculi. *Urology* 1974;4:319-21.
8. Bedir S, Kilciler M, Akay O, Erdemir F, Avcı A, Özgök Y. Endoscopic treatment of multiple prostatic calculi causing urinary retention. *Int J Urol* 2005;12:693-5.
9. Virgili G, Forte F, Sansalone S, Attisani F, De Carolis A, Di Stasi SM, *et al.* Radical prostatectomy as unique chance for huge prostatic stones. *Arch Ital Urol Androl* 2004;76:171-2.

Source of Support: Nil, Conflict of Interest: None declared.



Author Help: Online submission of the manuscripts

Articles can be submitted online from <http://www.journalonweb.com>. For online submission, the articles should be prepared in two files (first page file and article file). Images should be submitted separately.

- 1) **First Page File:**
Prepare the title page, covering letter, acknowledgement etc. using a word processor program. All information related to your identity should be included here. Use text/rtf/doc/pdf files. Do not zip the files.
- 2) **Article File:**
The main text of the article, beginning with the Abstract to References (including tables) should be in this file. Do not include any information (such as acknowledgement, your names in page headers etc.) in this file. Use text/rtf/doc/pdf files. Do not zip the files. Limit the file size to 1 MB. Do not incorporate images in the file. If file size is large, graphs can be submitted separately as images, without their being incorporated in the article file. This will reduce the size of the file.
- 3) **Images:**
Submit good quality color images. Each image should be less than 2048 kb (2 MB) in size. The size of the image can be reduced by decreasing the actual height and width of the images (keep up to about 6 inches and up to about 1800 x 1200 pixels). JPEG is the most suitable file format. The image quality should be good enough to judge the scientific value of the image. For the purpose of printing, always retain a good quality, high resolution image. This high resolution image should be sent to the editorial office at the time of sending a revised article.
- 4) **Legends:**
Legends for the figures/images should be included at the end of the article file.