

HOW
I DO IT

The Twin Amplatz Sheath Method: A Modified Technique of Percutaneous Cystolithotripsy for Large Bladder Stones in Female Patients

Amit Kumar, Deepansh Dalela, Divakar Dalela, Apul Goel, Sagorika Paul, Satya N. Sankhwar

Department of Urology, King George's Medical University
(erstwhile Chattrapati Shahuji Maharaj Medical University),
Lucknow, Uttar Pradesh, India

INTRODUCTION

Bladder stones currently account for 5% of all urinary stone diseases and approximately 1.5% of urologic hospital admissions in industrialized Western nations.^[1] Approximately 5% of all bladder stones occur in women.^[2] There are several established treatment modalities for bladder stones, for example, transurethral lithotripsy, percutaneous lithotripsy, and open surgery. To decrease the duration of the procedure, the use of the Amplatz sheath in female urethra and also in males has been described earlier.^[3,4] But in all these reports, urethral Amplatz was used as a working sheath through which the lithotripsy was performed and outflow maintained. We report a technique where a urethral Amplatz was used only as an outflow channel for stone fragments and irrigant.

MATERIALS AND METHODS

Technique

Three women with large bladder stones (>5 cm), as measured by longest diameter on plain X-ray of KUB (KUB: kidneys, urethra, and bladder), underwent

ABSTRACT

To minimize the operative time and to avoid open cystolithotomy in women with large bladder stone (>5 cm), we present here a modification of percutaneous cystolithotomy, a well-described standard procedure for urinary bladder stones. With this technique, suprapubic percutaneous access was achieved under cystoscopic guidance. The suprapubic tract was dilated and an Amplatz sheath of 30 Fr was placed. Simultaneously, the urethra was sequentially dilated with fascial dilators and a 28 Fr Amplatz sheath was guided into the bladder and the foot end of the table lowered to 20° to facilitate high-speed outflow of irrigant and stone particles. A 26.5 Fr nephroscope was passed through the suprapubic Amplatz sheath and the stone was fragmented by intracorporeal pneumatic device keeping the stone close to the proximal end of the urethral Amplatz. These maneuvers help in washing out stone fragments periurethrally and keeping the endoscopic vision clear while breaking the stone.

Key words: Amplatz sheath, bladder stone, percutaneous cystolithotripsy

percutaneous cystolithotripsy between September 2011 and August 2012. Under spinal anesthesia, the patients were placed in the lithotomy position. Suprapubic percutaneous access was achieved under cystoscopic guidance. The suprapubic tract was dilated using standard dilators and an Amplatz sheath of 30 Fr kept in the tract to serve as the main working port. Simultaneously, we sequentially dilated the urethra with fascial dilators and 28 Fr Amplatz sheath was guided into the bladder to serve as an outflow channel. The bevelled end of the Amplatz sheath was maintained at the bladder neck. After establishment of both Amplatz sheaths, the foot end of the table was lowered to 20° to facilitate high-speed outflow of the irrigant and stone particles. A 26.5 Fr nephroscope was passed through the suprapubic Amplatz sheath and the stone was fragmented by an intracorporeal pneumatic device [Figure 1]. During the fragmentation process, the stone rubble got washed away on account of the high-speed continuous outflow through the 28 Fr urethral Amplatz. Even the fragments up to a size of 9 mm came out themselves, sliding out through the urethral Amplatz [Figure 2]. We deliberately disintegrated the calculus into smaller fragments to enable

Access this article online

Quick Response Code:



Website:
www.jstcr.org

DOI:
10.4103/2006-8808.128757

Address for correspondence: Dr. Divakar Dalela,
Department of Urology, King George's Medical University
(erstwhile Chattrapati Shahuji Maharaj Medical University),
Lucknow - 226 003, Uttar Pradesh, India.
E-mail: drdalela@satyam.net.in

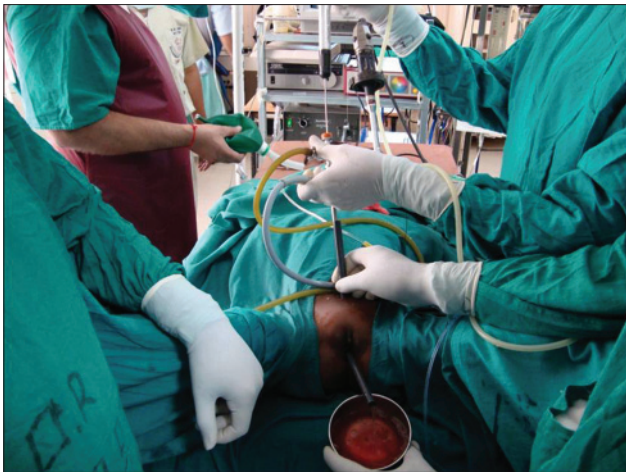

Figure 1: Twin Amplatz *in situ*, the one above as a working channel and the other in the urethra as an outlet

them to come out of the urethral Amplatz. Only a few fragments were picked up by forceps passed through the nephroscope in an antegrade manner. In the end, a Foley catheter was placed through the suprapubic tract which was removed after 48 hours. The patients were then followed up after one month, three months, and then yearly.

RESULTS

All three women included in this study had normal renal function parameters. There was no associated comorbidity in any of them. Two patients had calculus due to a neurogenic bladder, whereas the other had formed on account of a small long-standing Post-obstetric vesicovaginal fistula. The technique described was successful in all the women. The mean age of the patients was 40.10 years (39-43 years). All three patients had single bladder stones with sizes of 6.5, 5.5, and 5.2 cm, respectively. A pneumatic lithotripter was used for stone disintegration in all the patients. The stones were mainly composed of triple phosphate and disintegrated easily into rubble and chips. They were made stone-free successfully with a total operative time of 50 minutes, 45 minutes, and 40 minutes, respectively. No mucosal injury or other intraoperative/postoperative complications were observed. None of the patients experienced additional incontinence during the follow-up period of one year which was attributable to the urethral Amplatz.

DISCUSSION

Dilation of female urethra to ≥ 30 Fr has long been practiced for postmenopausal urethral stenosis or urethral syndrome.^[5] The female urethra is short; so, a straight Amplatz sheath can be placed through it. In earlier reports too, placing a 28 F

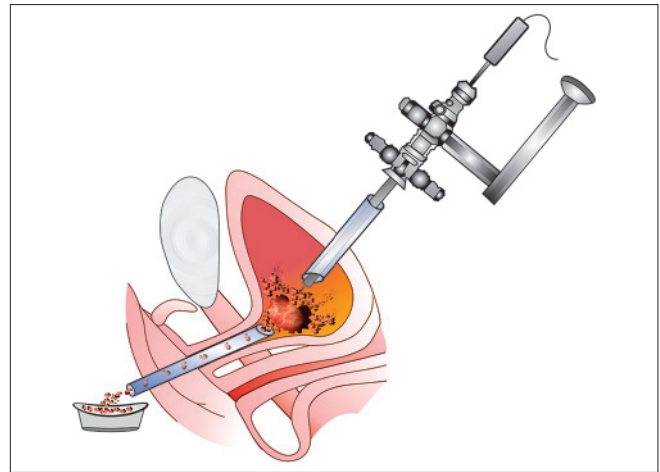


Figure 2: Fragmented stone particles slide out through the urethral Amplatz

Amplatz in the female urethra for about an hour did not lead to sphincteric dysfunction or incontinence. Kawahara *et al.*^[3] performed cystoscopic lithotripsy in women using a holmium: Yttrium-aluminium-garnet (Ho: YAG) laser. In their study, they used a urethral Amplatz sheath as the working channel and as an outlet; so, while breaking the stone, the nephroscope would obstruct the outflow of water, potentially leading to loss of clear vision. The stone rubble attempting to flow out by the side of scope may get stuck, forcing the operator to withdraw the nephroscope periodically. Here, we used a urethral sheath exclusively as a channel for the outflow. Maintenance of the beveled end of the sheath just up to the bladder neck and the 20° tilt of the foot end of the table were used as additional measures to further enhance outflow speed and let the Amplatz sheath function as a 'water slide' for larger stone particles. Therefore, the stone dust got washed away and a good endoscopic vision was maintained throughout. Fragments as large as 9 mm came out through the urethral sheath with the flow, curtailing time for picking up the fragments. So, by these maneuvers, we could reduce the operative time and obviate the need for open surgery even for stones larger than 5 cm.

CONCLUSION

The twin Amplatz sheath technique is a safe and effective way for accomplishing percutaneous cystolithotripsy in females expeditiously. In patients having large bladder stones, clear endoscopic vision and self-extrusion of stone fragments through a urethral Amplatz are potential benefits. A larger controlled study is needed further to validate this technique.

REFERENCES

1. Schwartz BF, Stoller ML. The Vesical calculus. *Urol Clin North*

Kumar, *et al.*: Twin Amplatz sheath technique of percutaneous cystolithotripsy for large bladder stone in females

- Am 2000;27:333-46.
2. Stav K, Dwyer PL. Urinary bladder stones in women. *Obstet Gynecol Surv* 2012;67:715-25.
 3. Kawahara T, Ito H, Terao H, Kato Y, Ogawa T, Kubota Y, *et al.* Amplatz Sheath for Cystolithotripsy Using Ho: YAG Laser in Female Patients. *Urology* 2012;80:1154-5.
 4. Okeke Z, Shabsigh A, Gupta M. Use of Amplatz sheath in male urethra during cystolitholapaxy of large bladder calculi. *Urology* 2004;64:1026-7.
 5. Maheshwari PN. The Amplatz sheath in the female urethra: A safe and effective approach for cystolitholapaxy. *Br J Urol* 1998;82:754.

How to cite this article: Kumar A, Dalela D, Dalela D, Goel A, Paul S, Sankhwar SN. The twin amplatz sheath method: a modified technique of percutaneous cystolithotripsy for large bladder stones in female patients. *J Surg Tech Case Report* 2013;5:109-11.

Source of Support: Nil, **Conflict of Interest:** None declared.