

CASE
REPORT

Axial Torsion of Gangrenous Meckel's Diverticulum Causing Small Bowel Obstruction

K. Sasikumar, Ravinder Naik Noonavath, G. S. Sreenath, Nanda Kishore Maroju

Department of Surgery, Jawaharlal Institute of Postgraduate Medical Education and Research, Puducherry, India

INTRODUCTION

Meckel's diverticulum (MD) is a commonly encountered congenital anomaly of the small intestine. Autopsy studies estimate overall incidence of 2%.^[1] About 4% of patients with an MD develop complications that include bleeding, perforation, inflammation, or obstruction.^[2] We report an extremely unusual case of an axially torted, gangrenous MD presenting as acute intestinal obstruction.^[3]

CASE REPORT

The present case is about a 26-year-old male patient who presented to our emergency department with 3 days history of abdominal pain, distention and bilious vomiting. He had no previous surgery and did not recollect similar episodes in the past. On examination, he was afebrile and hemodynamically stable. Blood counts and biochemical values were within the normal limits. On clinical examination, abdomen was distended with visible intestinal peristalsis, but without any guarding. There were no surgical scars and hernial orifices were free. Plain X-ray abdomen showed dilated small bowel loops with multiple air fluid levels [Figure 1]. Ultrasound abdomen suggested the possibility of an appendicular mucocele. He was taken up for urgent laparotomy with a clinical diagnosis of acute intestinal obstruction. Intra-operatively there was minimal

ABSTRACT

Meckel's diverticulum (MD) is a commonly encountered congenital anomaly of the small intestine. We report an extremely unusual case of an axially torted, gangrenous MD presenting as acute intestinal obstruction. A 26-year-old male patient presented to our emergency department with 3 days history of abdominal pain, distention and bilious vomiting. On laparotomy, there was minimal hemorrhagic fluid localized in right iliac fossa and small bowel loops were dilated. A MD was seen attached to the mesentery of nonadjacent small bowel by a peritoneal band. The diverticulum was axially torted and gangrenous. In addition, there was compression of ileum by the peritoneal band resulting in intestinal obstruction, which was relieved on dividing the band. Resection and anastomosis of the small bowel including the MD was performed. We hereby report a rare and unusual complication of a MD. Although treatment outcome is generally good, pre-operative diagnosis is often difficult.

Key words: Axial torsion, Meckel's diverticulum, small bowel obstruction

hemorrhagic fluid localized in right iliac fossa and small bowel loops were dilated. A MD was seen attached to the mesentery of nonadjacent small bowel by a peritoneal band, which was arising from its tip. The diverticulum was axially torted and gangrenous. In addition there was compression of ileum by the peritoneal band resulting in intestinal obstruction, which was relieved on dividing the band [Figure 2]. Resection and anastomosis of the small bowel including the MD was performed. Recovery was quick and uneventful and patient was discharged within a week.

DISCUSSION

MD is a true diverticulum derived from a persistent vitellointestinal duct and was first described by Johann Meckel in the year 1812.^[4,5] MD occurs on the antimesenteric border of the ileum and in the majority of the cases, within 90 cm from the ileocecal valve.^[1] A patient with MD has only 4% chance of developing a complication in his lifetime. Though the most common complication that occurs in MD is bleeding followed by obstruction and inflammation, a variety of presentations are described. Literature states that men are more likely than women to be

Access this article online	
Quick Response Code:	Website: www.jstcr.org
	DOI: 10.4103/2006-8808.128752

Address for correspondence: Dr. Nanda Kishore Maroju, Department of Surgery, Jawaharlal Institute of Postgraduate Medical Education and Research, Puducherry - 605 006, India. E-mail: nkmaroju@gmail.com

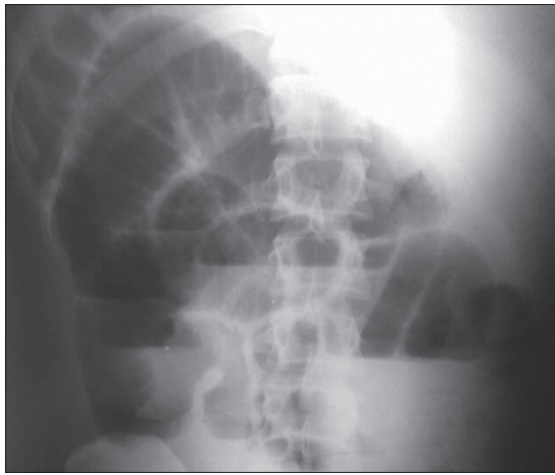


Figure 1: Plain X-ray showing small bowel obstruction

symptomatic (male/female ratio of 2:1 to 5:1).^[3] Bleeding and intestinal obstruction are the two most common presentations in children and are seen in 25-50% and 25% of children respectively.^[2,6] Bleeding is the most common complication in adults.^[7] When intestinal obstruction does occur, intussusception or volvulus are commonly implicated.^[6] Literature review states that peritoneal bands, Littre's hernias, diverticular strictures, enterolith or bezoars lodged in the diverticulum in a Y-shaped "pantaloons" fashion are other rare causes for intestinal obstruction.^[3,6]

Gangrene of MD, secondary to axial torsion is a rare phenomenon. A review of the literature identified a total of seven reported cases.^[1,3-6] We expected this combination of gangrenous Meckel's due to axial torsion and intestinal obstruction to be extremely rare, but a literature search on PubMed could unearth three similar reports.^[2,3,8] In a study by Cartanese *et al.*^[3] reported that the cause for obstruction was a peritoneal band arising from the tip of the diverticulum attaching to the surrounding mesentery. Studies describe that diverticular length and diameter of the base are the two important factors, which increase the risk for axial torsion.^[1,3,9] An elongated MD with a narrowed neck is far more likely to result in torsion. In our patient, the diverticulum was 6 cm long and 3 cm wide, perhaps predisposing it for torsion.

The varied clinical presentation of MD makes preoperative diagnosis often difficult, with only 6-12% of cases being diagnosed correctly.^[10] Most of the cases are misdiagnosed as acute appendicitis. Computed tomography scans and sonograms may aid in the diagnosis of such uncommon pathology and should be considered in cases of intestinal obstruction with no clear etiology. The use of Tc 99-m pertechnetate or Tc 99-m sulfur colloid is primarily for investigating gastrointestinal bleeding and may not

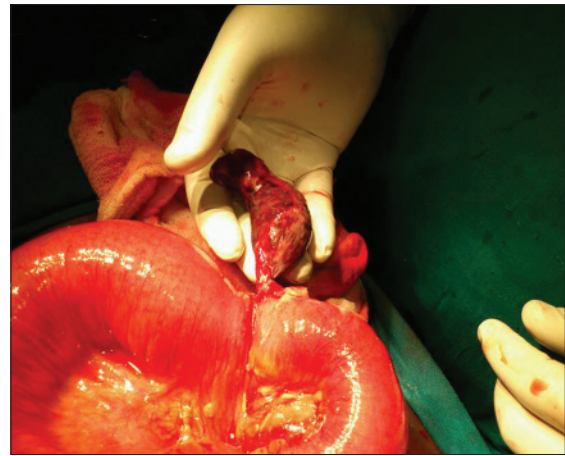

Figure 2: Gangrenous Meckel's diverticulum causing obstruction of small bowel (after releasing the peritoneal band causing obstruction)

be applicable in a case of intestinal obstruction.^[11] In patients with doubtful diagnosis laparoscopy is a safe and effective surgical modality for diagnosing MD and has a therapeutic role that results in an excellent cosmetic result.^[12] Treatment of MD is always surgical. A simple excision in the transverse axis of the ileum to avoid luminal stenosis is usually the recommended procedure. Segmental resection with anastomosis is mostly reserved for complicated MD.^[5]

CONCLUSION

We report here a rare and unusual complication of a MD. Although treatment outcome is generally good, pre-operative diagnosis is often difficult. It may be a rewarding experience to develop a high index of suspicion of MD in patients with atypical presentations of abdominal pain or obstruction.


REFERENCES

1. Kiyak G, Ergul E, Sarikaya SM, Kusdemir A. Axial torsion and gangrene of a giant Meckel's diverticulum mimicking acute appendicitis. *J Pak Med Assoc* 2009;59:408-9.
2. Prall RT, Bannon MP, Bharucha AE. Meckel's diverticulum causing intestinal obstruction. *Am J Gastroenterol* 2001;96:3426-7.
3. Cartanese C, Petitti T, Marinelli E, Pignatelli A, Martignetti D, Zuccarino M, *et al.* Intestinal obstruction caused by torse gangrenous Meckel's diverticulum encircling terminal ileum. *World J Gastrointest Surg* 2011;3:106-9.
4. Limas C, Seretis K, Soultanidis C, Anagnostoulis S. Axial torsion and gangrene of a giant Meckel's diverticulum. *J Gastrointest Liver Dis* 2006;15:67-8.
5. Cullen JJ, Kelly KA. Current management of Meckel's diverticulum. *Adv Surg* 1996;29:207-14.
6. Malhotra S, Roth DA, Gouge TH, Hofstetter SR, Sidhu G, Newman E. Gangrene of Meckel's diverticulum secondary to axial torsion: A rare complication. *Am J Gastroenterol* 1998;93:1373-5.
7. Arnold JF, Pellicane JV. Meckel's diverticulum: A 10-year experience. *Am Surg* 1997;63:354-5.

Sasikumar, *et al.*: Meckel's diverticulum causing small bowel obstruction

8. Sharma RK, Jain VK, Kamboj S, Murari K. Gangrenous Meckel's diverticulum causing acute intestinal obstruction in an adult. ANZ J Surg 2008;78:1046-7.
9. Tan YM, Zheng ZX. Recurrent torsion of a giant Meckel's diverticulum. Dig Dis Sci 2005;50:1285-7.
10. Rossi P, Gourtsoyiannis N, Bezzi M, Raptopoulos V, Massa R, Capanna G, *et al.* Meckel's diverticulum: Imaging diagnosis. AJR Am J Roentgenol 1996;166:567-73.
11. Ruiz VA, Camacho LA, Díaz DC. Giant Meckel's diverticula with necrosis due to axial torsion. Rev Col Gastroenterol 2010;25:398-400.
12. Ding Y, Zhou Y, Ji Z, Zhang J, Wang Q. Laparoscopic management of perforated Meckel's diverticulum in adults. Int J Med Sci 2012;9:243-7.

How to cite this article: Sasikumar K, Noonavath RN, Sreenath GS, Maraju NK. Axial torsion of gangrenous Meckel's diverticulum causing small bowel obstruction. J Surg Tech Case Report 2013;5:103-5.
Source of Support: Nil, **Conflict of Interest:** None declared.



Author Help: Reference checking facility

The manuscript system (www.journalonweb.com) allows the authors to check and verify the accuracy and style of references. The tool checks the references with PubMed as per a predefined style. Authors are encouraged to use this facility, before submitting articles to the journal.

- The style as well as bibliographic elements should be 100% accurate, to help get the references verified from the system. Even a single spelling error or addition of issue number/month of publication will lead to an error when verifying the reference.
- Example of a correct style
Sheahan P, O'leary G, Lee G, Fitzgibbon J. Cystic cervical metastases: Incidence and diagnosis using fine needle aspiration biopsy. Otolaryngol Head Neck Surg 2002;127:294-8.
- Only the references from journals indexed in PubMed will be checked.
- Enter each reference in new line, without a serial number.
- Add up to a maximum of 15 references at a time.
- If the reference is correct for its bibliographic elements and punctuations, it will be shown as CORRECT and a link to the correct article in PubMed will be given.
- If any of the bibliographic elements are missing, incorrect or extra (such as issue number), it will be shown as INCORRECT and link to possible articles in PubMed will be given.