

HOW

I DO IT

Construction of a Jejunal Pouch After Total Gastrectomy

Alexandre Doussot, Baptiste Borraccino, Patrick Rat, Pablo Ortega-Deballon, Olivier Facy

Department of Digestive Surgical Oncology, University Hospital of Dijon, Dijon, France

INTRODUCTION

Total gastrectomy results in a reduction of food intake, malnutrition, malabsorption, and weight loss. This is due in part to the loss of the secreting function of the stomach, but also to the loss of the reservoir function and the subsequent postgastrectomy syndromes (early dumping, late dumping, diarrhea, etc.). Different types of reconstruction have been proposed to reduce these postoperative adverse effects. Most of them attempted the creation of a pouch in order to improve the food intake and slow the transit. Reconstruction using a jejunal interposition is more complicated and less suitable than the simple classic Roux-en-Y reconstruction.^[1] According to several prospective randomized trials and a recent meta-analysis, the Roux-en-Y jejunal pouch reconstruction [Figure 1] appears to be the best technique for reconstruction; it improves the feeding, the weight recovery, and the quality of life after gastrectomy, particularly in patients with an expected survival longer than 6 months.^[2,3] Its beneficial effects are long lasting.^[4] However, it is not still widely used by western surgeons.

TECHNIQUE

After performing a total gastrectomy associated to a formal over-D1 lymphadenectomy and a systematic

Video available on www.jstcr.org

Access this article online

Quick Response Code:



Website:
www.jstcr.org

DOI:
10.4103/2006-8808.135152

Address for correspondence: Dr. Alexandre Doussot, Department of Digestive Surgical Oncology, University Hospital of Dijon, 14, Rue Gaffarel, 21079 Dijon Cedex, France. E-mail: lex.doussot@yahoo.com

ABSTRACT

Total gastrectomy for cancer results in many digestive troubles leading to an impairment of the quality of life. Different types of reconstruction have been proposed to improve the postoperative digestive functions. According to several prospective randomized trials and a recent meta-analysis, the Roux-en-Y jejunal pouch reconstruction appears to be the best technique for reconstruction concerning the postoperative quality of life. However, this safe reconstructive surgery is not still recognized as a gold standard.

Key words: Jejunal pouch, quality of life, surgical technique, total gastrectomy

cholecystectomy,^[5] a jejunal pouch is constructed according to the following technique [Video 1].

The jejunum is divided 20 cm distal to the Treitz ligament with a linear stapling device. The proximal end of the Roux limb is folded up to create an “inverted J”, 15 cm long. The future pouch is opened near the jejunal stump and the two limbs are side-to-side anastomosed together applying successive charges of 60-mm length linear stapler cephalad, as far as 1-2 cm from the intestinal bend. About two or three charges are usually required. A mucus bridge remains at the top of the pouch that it is not necessary to cut. The end-to-side esophagojejunostomy is performed with a 25 mm diameter circular stapler that is introduced through the same orifice used for the linear

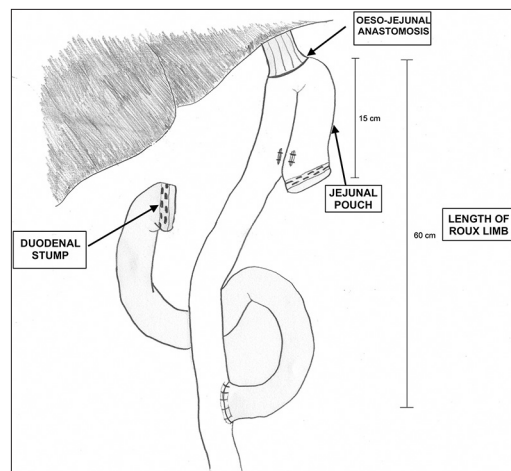


Figure 1: Roux-en-Y jejunal pouch reconstruction after total gastrectomy

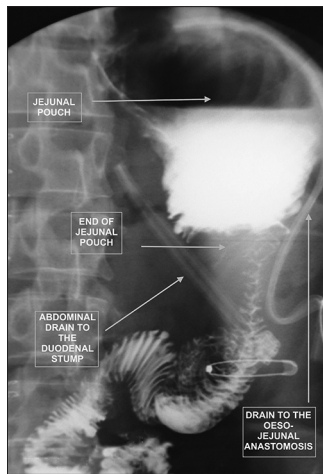


Figure 2: Water-soluble contrast swallow X-ray at POD 6

stapler. The enterotomy is then closed either manually or mechanically in the transversal plan. An end-to-side hand-sewn jejunojejunal anastomosis is performed with two absorbable running sutures 60 cm distally to the top of the pouch. This procedure could be performed laparoscopically-assisted; however, the construction of the jejunal pouch is challenging.

POSTOPERATIVE MANAGEMENT

A nasojejunal tube is not placed routinely. If it is, note that a whitish secretion coming from the secreting jejunal mucosa of the pouch is usually found in the first postoperative days and should not be mistaken for a postoperative complication.

Even if drains are not mandatory after total gastrectomy, we use to put a low-pressure aspirative drain in the vicinity of the esophagojejunal anastomosis, as well as another one close to the duodenal stump. Before restarting oral nutrition, the esophagojejunal anastomosis is controlled with a water-soluble contrast swallow X-ray 6 days after surgery [Figure 2 and Video 2]. The patients are usually discharged at the 9th postoperative day.

REFERENCES

1. Ishigami S, Natsugoe S, Hokita S, Aoki T, Kashiwagi H, Hirakawa K, *et al.* Postoperative long-term evaluation of interposition reconstruction compared with Roux-en-Y total gastrectomy in gastric cancer: Prospective randomized controlled trial. *Am J Surg* 2011;202:247-53.
2. Gertler R, Rosenberg R, Feith M, Schuster T, Friess H. Pouch vs. no pouch following total gastrectomy: Meta-analysis and systematic review. *Am J Gastroenterol* 2009;104:2838-51.
3. Iivonen MK, Mattila JJ, Nordback IH, Schuster T, Friess H. Long-term follow-up of patients with jejunal pouch reconstruction after total gastrectomy. A randomized prospective study. *Scand J Gastroenterol* 2000;7: 679-85.
4. Fein M, Fuchs KH, Thalheimer A, Freys SM, Heimbucher J, Thiede A. Long-term benefits of Roux-en-Y pouch reconstruction after total gastrectomy: A randomized trial. *Ann Surg* 2008;247: 759-65.
5. Kobayashi T, Hisanaga M, Kanehiro H, Yamada Y, Ko S, Nakajima Y. Analysis of risk factors for the development of gallstones after gastrectomy. *Br J Surg* 2005;92:1399-403.

How to cite this article: Doussot A, Borraccino B, Rat P, Ortega-Deballon P, Facy O. Construction of a Jejunal pouch after total gastrectomy. *J Surg Tech Case Report* 2014;6:37-8.

Source of Support: Nil, **Conflict of Interest:** None declared.