

CASE  
REPORT

## Bilateral Paratesticular Liposarcoma - A Rare Case Report

Mohammed Raza, Hagadur Gurureddy Vinay, Mirzeeshan Ali, Gurubasappa Siddesh

Department of General Surgery, JSS Medical College Hospital,  
JSS University, Mysore, Karnataka, India

### INTRODUCTION

Liposarcomas are soft tissue sarcomas that originate from adipose tissue. Paratesticular tumors are infrequent tumors that have a high incidence of malignancy; they are either soft-tissue tumors or mesothelial neoplasms. Paratesticular liposarcomas include all liposarcomas arising in the structures around the testis, including the lower end of the cord.<sup>[1]</sup> It is felt to arise from the extra peritoneal fat that becomes continuous distally with the fatty tissue of the cord.<sup>[2]</sup> They commonly present as painless, slowly growing masses that are usually diagnosed as being a lipoma or inguinal hernia. However, complete surgical resection offers the best chance of cure for these patients, and the established method for orchiectomy for testes/cord cancer is through an inguinal incision. Radiotherapy or chemotherapy is added for advanced disease or recurrences.

### CASE REPORT

A 65-year-old male patient presented with scrotal swelling of 2-year duration in both right and left hemiscrotum, which was gradually progressive in size and non-reducible. On examination, swelling was soft in consistency, testis was palpable posteriorly, and could not get above the swelling. Diagnosis of bilateral inguinal hernia was made and patient was planned for surgery. Intraoperative, a firm, well-defined tumor, about 20 × 14 × 5 cms on the left and 16 × 14 × 4 cms on the right side were found at the proximal spermatic

### ABSTRACT

Paratesticular liposarcomas are rare tumors and are often reported as isolated cases. Patients usually present with a painless scrotal or inguinal mass, mimicking inguinal hernia. They refer to liposarcomas arising from the spermatic cord, testicular tunics, and epididymis. We report a case of bilateral scrotal swelling which was misdiagnosed as inguinal hernia. Intraoperative diagnosis of testicular tumor was made. High inguinal orchiectomy was done. Histopathological examination revealed it to be liposarcoma of the cord. To our knowledge, there is no reported case of bilateral paratesticular liposarcoma in English literature, hence we report this case.

**Key words:** Epididymis, lipoma, testis

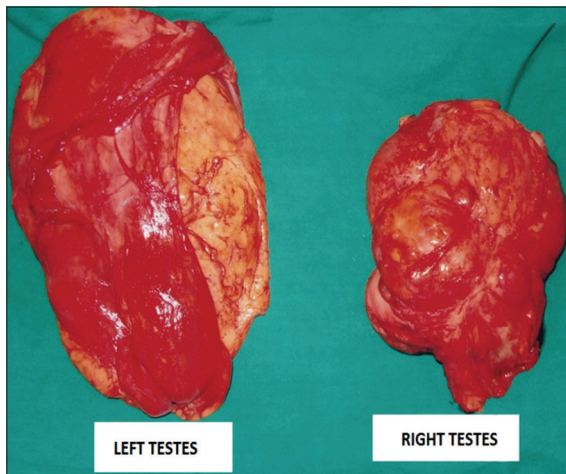
cord [Figure 1]; no hernia sac was noted at the inguinal canal. Bilateral high inguinal orchiectomy was performed. The gross appearance of the specimen revealed a large, soft, well-circumscribed, multilobulated, fat-containing mass adhering to the spermatic cord and testis. The cut surface of the tumor [Figure 2] showed yellowish and myxoid areas, but without hemorrhage or necrosis. Histopathological examination [Figures 3 and 4] showed sheets and nests of mature adipocytes, scattered atypical cells with hyperchromatic nuclei, and multivacuolated lipoblasts in between on a fibrous and myxoid background. Sections from the testes showed no significant pathology. The patient was counseled on plans for further chemotherapy and radiotherapy. He, however, refused further treatment because he did not have enough money to continue treatment. He has since been lost to follow-up. Informed consent has been taken from the patient regarding the publication of the case report.

### DISCUSSION

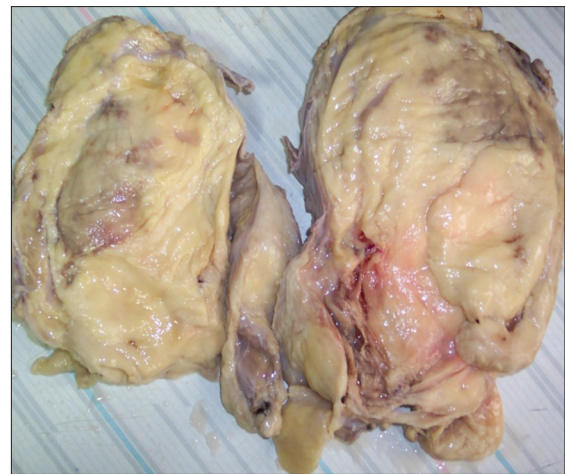
Dreyfuss and Lubash reported the first documented liposarcoma of the spermatic cord in a 54-year-old male in 1940.<sup>[3]</sup> Since then, cases have been published as individual case reports or case series. Liposarcomas are soft-tissue malignancies that are commonly found in the lower extremities and retroperitoneum. They are classified in four histology subtypes (well differentiated, myxoid, pleomorphic, and dedifferentiated).<sup>[4]</sup> Paratesticular tumors have a high incidence of malignancy, which is estimated as 30% in the documented literature, mostly arising from

Access this article online	
Quick Response Code:	Website: <a href="http://www.jstcr.org">www.jstcr.org</a>
	DOI: 10.4103/2006-8808.135140

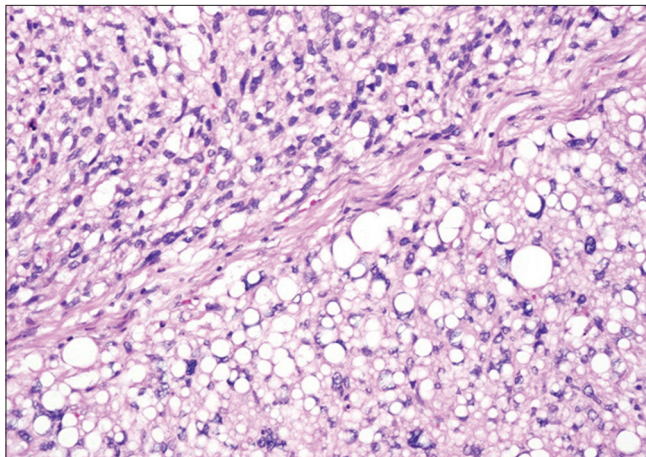
**Address for correspondence:** Dr. Hagadur Gurureddy Vinay,  
Department of General Surgery, JSS Medical College Hospital,  
JSS University, Mysore - 570 004, Karnataka, India.  
E-mail: [vinay\\_1771@yahoo.co.in](mailto:vinay_1771@yahoo.co.in)



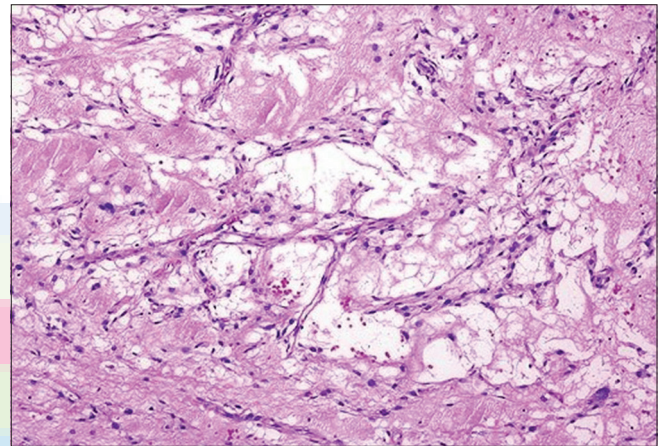
**Figure 1:** Gross specimen of the tumor mass measuring 20 x 14 x 5 cms on left and 16 x 14 x 4 cms on the right



**Figure 2:** Cut section of the specimen showing yellowish and myxoid areas



**Figure 3:** Microscopic examination of the mass revealed an encapsulated proliferation consisting of mature adipocytes accompanied by both spindle-shaped cells and multivacuolated lipoblasts



**Figure 4:** Microscopic photograph showing mature adipocytes, spindle-shaped cells with hyper chromatic nuclei within the stromal tissue and multivacuolated lipoblasts in between on a fibrous and myxoid background

the spermatic cord.<sup>[5]</sup> Most patients present with painless, slowly growing inguinal or scrotal masses, which are usually diagnosed as inguinal hernias or lipoma before surgical intervention. The majority of spermatic cord sarcomas begin their development just below the external inguinal ring and therefore, grows as a scrotal mass rather than as an inguinal mass.

The homogenous fatty pattern of well-differentiated paratesticular liposarcomas being similar to lipomas or omentum in the hernia sac makes the differential diagnosis of a liposarcoma difficult through ultrasonographic studies.<sup>[6]</sup> Hence, even though ultrasonography is the most helpful and commonly used diagnostic tool for differentiating cystic and solid lesions, an abdominal CT scan may be helpful.

A radical orchiectomy remains the mainstay of initial treatment for paratesticular liposarcomas. Since they have

the tendency for local recurrence after inadequate resection, complete resection, including high ligation of the spermatic cord, is indicated.<sup>[7]</sup> An intralesional biopsy or surgery should be avoided to prevent spillage of malignant cells. The role of adjuvant radiotherapy or chemotherapy remains controversial and is only limited in cases of metastatic tumors or in cases following incomplete resection. Radiation therapy may be employed as an adjunct to surgical resection in an attempt to avoid local recurrence.<sup>[8]</sup> Some authors have even discussed the possibility of the dedifferentiation.<sup>[9]</sup>

The prognosis of paratesticular liposarcomas depends on the histological cell type, among well- differentiated, dedifferentiated pleomorphic, and myxoid/round cell types. The well-differentiated and myxoid/round cell types have a better prognosis, but they tend to have a high incidence of local recurrence.<sup>[10]</sup> Malignant spermatic cord tumors are more frequently sarcomas. Radiotherapy is controversial for

local control of liposarcomas. Liposarcomas are the most radiosensitive of all sarcomas and in some cases remission has been achieved with radiotherapy alone.<sup>[10]</sup>

## CONCLUSION


In conclusion, liposarcomas of the spermatic cord represent a rare type of tumors, which are often misdiagnosed preoperatively. Being a rare disease and varied type of presentation, paratesticular liposarcoma should be considered as a possibility during the differential diagnosis of fat containing inguino-scrotal mass. The best chance of cure is by radical orchiectomy.

## REFERENCES

1. Bissada NK, Finkbeiner AE, Redman JF. Paratesticular sarcomas: Review of management. *J Urol* 1976;16:198-200.
2. Datta NS, Singh SM, Bapna BC. Liposarcoma of the spermatic cord: Report of a case and review of the literature. *J Urol* 1971;106:888-9.
3. Dreyfuss ML, Lybash S. Malignant mixed tumor of the spermatic cord. *J Urol* 1940;44:314-24.
4. García Morúa A1, Lozano Salinas JF, Valdés Sepúlveda F, Zapata H, Gómez Guerra LS. Liposarcoma of the spermatic cord: Our experience and review of the literature. *Actas Urol Esp* 2009;33:811-5.
5. Khoubehi B, Mishra V, Ali M, Motiwala H, Karim O. Adult paratesticular tumors. *BJU Int* 2002;90:707-15.
6. Montgomery E, Fisher C. Paratesticular liposarcoma: A clinicopathologic study. *Am J Sur Pathol* 2003;27:40-7.
7. Ulbright TM, Amin MB, Young RH. Miscellaneous primary tumors of the testis, adnexa, and spermatic cord," in Atlas of Tumor Pathology. In: Rosai J, Sobin LH, editors. Washington, DC, USA: Armed Forces Institute of Pathology Press; 1999. p. 235-66.
8. Murphey MD, Arcara LK, Fanburg-Smith J. From the archives of the AFIP: Imaging of musculoskeletal liposarcoma with radiologic-pathologic correlation. *Radiographics* 2005;25:1371-95.
9. Weiss SW, Rao VK. Well-differentiated liposarcoma (atypical lipoma) of deep soft tissue of the extremities, retroperitoneum, and miscellaneous sites. *Am J Surg Pathol* 1992;16:1051-8.
10. Stranne J, Hugosson J, Lodding P. Post-radical retropubic prostatectomy inguinal hernia: An analysis of risk factors with special reference to preoperative inguinal hernia morbidity and pelvic lymph node dissection. *J Urol* 2006;176:2072-6.

**How to cite this article:** Raza M, Vinay HG, Ali M, Siddesh G. Bilateral paratesticular liposarcoma - A rare case report. *J Surg Tech Case Report* 2014;6:15-7.

**Source of Support:** Nil, **Conflict of Interest:** None declared.



## Author Help: Online submission of the manuscripts

Articles can be submitted online from <http://www.journalonweb.com>. For online submission, the articles should be prepared in two files (first page file and article file). Images should be submitted separately.

- 1) **First Page File:**  
Prepare the title page, covering letter, acknowledgement etc. using a word processor program. All information related to your identity should be included here. Use text/rtf/doc/pdf files. Do not zip the files.
- 2) **Article File:**  
The main text of the article, beginning with the Abstract to References (including tables) should be in this file. Do not include any information (such as acknowledgement, your names in page headers etc.) in this file. Use text/rtf/doc/pdf files. Do not zip the files. Limit the file size to 1 MB. Do not incorporate images in the file. If file size is large, graphs can be submitted separately as images, without their being incorporated in the article file. This will reduce the size of the file.
- 3) **Images:**  
Submit good quality color images. Each image should be less than 4096 kb (4 MB) in size. The size of the image can be reduced by decreasing the actual height and width of the images (keep up to about 6 inches and up to about 1800 x 1200 pixels). JPEG is the most suitable file format. The image quality should be good enough to judge the scientific value of the image. For the purpose of printing, always retain a good quality, high resolution image. This high resolution image should be sent to the editorial office at the time of sending a revised article.
- 4) **Legends:**  
Legends for the figures/images should be included at the end of the article file.