

JOURNAL OF RADIOGRAPHY



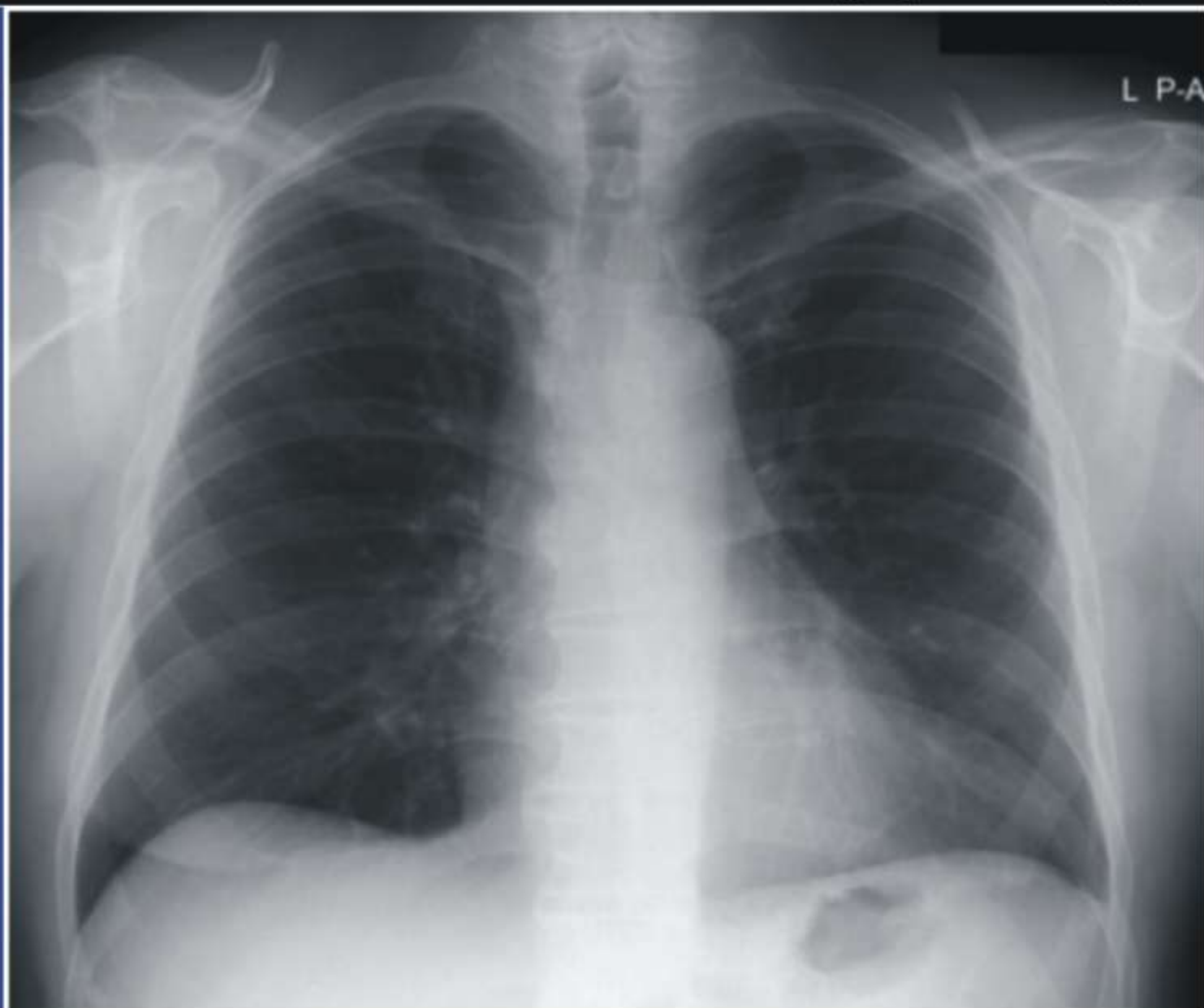
& RADIATION SCIENCES

ISSN: 1115- 7976

Vol 32, Issue 1, May 2018

The Official Journal of The Association of Radiographers of Nigeria

J
R
R
S



Journal homepage: www.jarnigeria.com

Variation of Prenatal Ultrasound-Estimated Cephalic Index; A Comparative Study of Igbo, Hausa and Yoruba Ethnic Groups in Nigeria

Ayang, O. Lawrence* and Abonyi, L. Chibuzo¹

Radiology Department, Duro Soley Hospital, Lagos, Nigeria

¹Radiography Department, University of Lagos, Lagos, Nigeria

*Correspondence: obenghana@gmail.com, +2347033384891

Received: 25 January, 2018. Received in revised form: 24 April, 2018. Accepted: 29 May, 2018

ABSTRACT

Background: Fetal ultrasound-estimated cephalic index refers to the ratio of the fetal biparietal diameter (BPD) to the occipito-frontal diameter (OFD) by means of ultrasound estimation. The cephalic index is regarded as a useful anthropometric variable in medicine, forensic science and anthropology. There is limited data on the cephalic indices of Nigerian fetuses

Objective: To check for variations of prenatal ultrasound-estimated cephalic indices between fetuses of Igbo, Yoruba and Hausa ancestry.

Methodology: In a cross sectional study carried out in ultrasound diagnostic centres in Lagos, Enugu and Kano, all in Nigeria, fetal biparietal and occipitofrontal diameters were obtained from 200 fetuses each of Igbo, Yoruba and Hausa ethnic groups. The cephalic index was calculated for each group. The values were statistically analysed after deriving the relevant indices.

Result: The fetal cephalic indices for Igbo, Yoruba and Hausa ethnic groups were observed to be 80 ± 3.4 , 79.1 ± 5.1 and 78.4 ± 2.6 %, respectively.

Conclusion: The results showed that fetuses of Igbo ancestry had a different cephalic index categorization from other ethnic groups. This knowledge will be useful to sonographers and researchers.

Keywords: Cephalic index, brachycephaly, mesocephaly, dolichocephaly

Introduction

Fetal ultrasound-estimated cephalic index refers to the ratio of the fetal biparietal diameter (BPD) to the occipito-frontal diameter (OFD) by means of ultrasound estimation. The cephalic index was first defined by Anders Retzius (1796-1860), a Swedish Professor of Anatomy and first used in physical anthropology to classify ancient human remains found in Europe into races, based on similar measurements [1]. The cephalic index has since been regarded as a useful anthropometric variable used in physical anthropology to determine variations in gender, age, race and ethnicity [2].

A range of cephalic indices have been compiled and currently regarded as international standard to describe various head shapes which include dolichocephaly (long head, ≤ 75 %), mesocephaly (medium size head, 76 - 79 %), brachycephaly (broad head, 80 - 85%), hyperbrachycephaly (very broad head, > 85 %) [3].

Several physical anthropometric studies conducted in Nigeria suggest variations in cephalic indices among adults and adolescents of ethnic groups including the Yoruba, Igbo and Hausa [4, 5].

Ayang and Abonyi: Ultrasound-estimated fetal cephalic index

The adult Yorubas were considered largely dolichocephalic with sexual dimorphism; the males having a higher cephalic index than the females [2]. Adult Igbos were reported to be brachycephalic [6]. Adult Hausas were seen as mesocephalic [7].

A recent study of 1,500 adult subjects comprising equal number of Igbo, Yoruba and Hausa ethnic groups however, indicated that all three were brachycephalic [8]. It is also noted that there is significant variation between the cephalic indices of Nigerian and Caucasian fetuses [9]. The purpose of this present study was to compare, using ultrasound, the cephalic indices of Igbo, Yoruba and Hausa fetuses.

Materials and methods

This was a prospective, cross sectional, clinical study involving volunteers who came for obstetrical ultrasound scan. Four private diagnostic centres in Lagos, Kano and Enugu were used for the study which took place between March and October 2016. The volunteers were recruited consecutively and only dropped if they withheld consent. Ethical committee approval from one of the centres was obtained prior to the study.

Data was eventually collected from 600 pregnant participants in second and third trimesters who met the inclusion criteria. These criteria included ethnicity that was limited to Yoruba, Igbo and Hausa fetuses without anomaly, and singleton gestations. Participants with history of obstetric complications, intrauterine growth retardation and foetal cranial anomaly were excluded.

The measurements were performed by the investigator and other sonographers using a Hitachi EU 525, Sonoline SI 450, Toshiba Tian Yi machine and Mindray DC-6 expert ultrasound machines with a 2.5 to 3.5 curvi-linear probe. Fetal Biparietal diameter (BPD) measurements were taken in an axial plane as described by Hadlock et al. [12] at the level of the thalami, where the continuous midline echo is broken by the cavum septum pellucidum.

Measurement of BPD was taken from the outer edge to the outer edge of the parietal bone.

The occipito-frontal diameter (OFD) was measured in the same plane between the leading edge of the frontal bone and the outer border of the occiput. The cephalic index was calculated as a percentage of the ratio of biparietal diameter to the occipitofrontal diameter ($BPD/OFD \times 100$). Statistical analyses were performed with the aid of Microsoft excel statistical package.

Results

The throughput (Table 1) and demographic characteristics of subjects are shown (Table 2). Table 3 Shows the mean cephalic indices of the Igbo, Yoruba and Hausa ethnic groups, while Table 4 compares the present study with previous ones. Figure I is distribution of cephalic index with increasing gestational age, while Figure II compares cephalic indices between paediatrics and adults among the Igbo, Yoruba and Hausa ethnic groups.

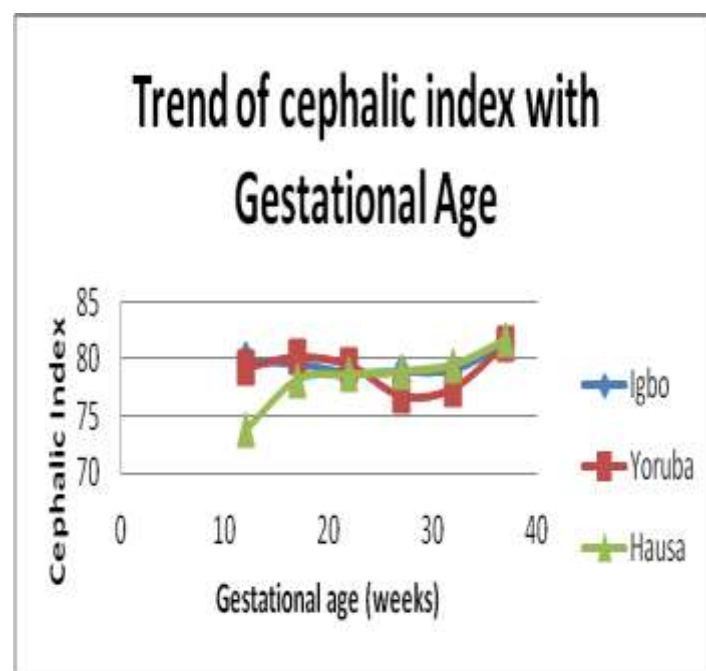


Figure I: Mean cephalic indices of Igbo, Yoruba and Hausa fetuses from 12 to 40 weeks gestational age

Ayang and Abonyi: Ultrasound-estimated fetal cephalic index

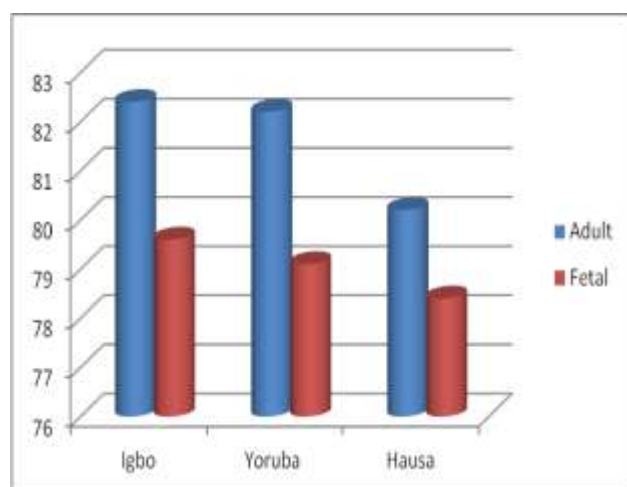


Figure II: Comparison between adult and fetal cephalic indices of the Igbo, Yoruba and Hausa ethnic groups

Table 1. Throughput of participants in the study centres

Parameter	Centres			
	A	B	C	D
Throughput	218	140	121	206
Excluded	18	31	30	6
Sample size	200	109	91	200

Table 2. Characteristics of participants

Parameter	Centres			
	A	B	C	D
Mean age (years)	32±3.6	30±5.2	32±4.1	29±3.1
2 nd trimester	102	58	42	119
3 rd trimester	98	51	49	81

Table 3. Cephalic indices of fetuses

GA groups	Ethnic group		
	Igbo (%)	Yoruba (%)	Hausa (%)
12-16	79.9±4.9	79.3±6.8	73.7±0.6
17-21	79.6±4.0	80.2±4.2	78.2 ±1.2
22-26	78.8±2.9	79.5±5.5	78.6±3.3
27-31	78.9±2.5	76.7±5.5	78.9±3.4
32-36	79.1±2.8	77.4±5.5	79.5±2.8
37-41	81.4±3.3	81.4±3.0	81.7±4.0
Mean	80.0±3.4	79.1±5.1	78.4±2.6

Discussion

The present study provides valuable data pertaining to the cephalic indices of the Igbo, Yoruba and Hausa ethnic groups of Nigeria.

There were 600 participants for this study comprising 321 (53.5%) who were in second trimester, and 279 (46.5%) in third trimester. All the participants had age ranging from 29 ± 3.1 to 32 ± 4.1 years.

The findings of this study puts the cephalic indices of the Igbo, Yoruba and Hausa fetuses at 80 ± 3.4 , 79.1 ± 5.1 and 78.4 ± 2.6 , respectively. On comparison with their adult counterparts, the findings of this study affirms those of Chisom [6], and Ewunonu [8], on brachycephalization of the Igbo tribe, and Oladipo [2], which ascribes a mesocephalic head shape for Hausa and Yoruba.

If the values of the fetal cephalic indices from this study are compared with the those of adult of Igbo, Yoruba and Hausa ancestry, described by Ewunonu [8], One can predict that the fetal cephalic indices of the Yoruba and Hausa ethnic groups will progress to the brachycephalic head shape in post-natal life. One can also suggest genetic transmission of traits such as head shapes and sizes.

It was observed that the cephalic indices of all groups changed several times between 12 weeks to term. This finding tallies with those of Mador et al [10] and Gray et al [13], which relates the change in the cephalic indices to increase in gestational age. It is noted however, that the change in cephalic indices between the three groups in various gestational ages also varied.

These variations of head shapes among the Yoruba and Hausa fetuses are lost at term where both groups are known to demonstrate mesocephalic head shape. The Igbo foetuses assume the brachycephalic head shape, thus agreeing with the findings of Ugwu et al. [11] on brachycephalization of Igbo foetuses. There is however no current publication on fetal cephalic indices of Yoruba and Hausa foetuses.

Ayang and Abonyi: Ultrasound-estimated fetal cephalic index

It is therefore, our conclusion that fetal cephalic index of Igbo, Yoruba and Hausa foetuses are 80 ± 3.4 , 79.1 ± 5.1 and 78.4 ± 2.6 respectively. The Igbo foetuses have brachycephalic head shapes. The Yoruba and Hausa foetuses have mesocephalic head shapes.

Recommendation

Further studies should attempt to capture the relationship between fetal and maternal/paternal cephalometric parameters.

Acknowledgement

My supervisor and colleagues who contributed to the success of this work are deeply appreciated.

References

1. Anitha M, Vijayanath V, Raju G, et al. Cephalic index of north Indian population. *Anatomica Karnataka* 2011, 5(1):40-43.
2. Oladipo G. S., Anugweje K. C. and Bob-Manuel I. F., Dolicocephalization in Cephalic Indices of Adult Yorubas of Nigeria, *Journal of Anthropology*, 2014, 5 (1):1-6
3. Williams, P.; Dyson, M.; Dussak, J.E.; Bannister, L.H.; Berry, M.M.; Collins, P. & Ferguson, M.W.J. *Gray's anatomy in Skeletal system*. 38th Ed. London, Elbs with Churchill Livingstone, 1995. Pp. 607-12.
4. Anupama M, Baljeet S., Seema D. Arvinder P. The study of cephalic index in Punjabi students, *Journal of Punjab Academy of Forensic Medicine & Toxicology*, 2009, 9 (10): 24-27.
5. Obaje S.G, Hamman W.O, Ibegbu A.O and Waitieh-Kabehl A.K, Anthropometric study of cephalometric indices among Idoma and Igede ethnic groups of Benue State, Nigeria, *Int J Med Biomed Res*, 2015, 4(1):21-34
6. Chisom E. I, Eghort O,T, Mesembe, O.E. Cephalofacial Indices of the Ibo and Yoruba Ethnic groups in Southern Nigeria, *Journal of Biology, Agriculture and Healthcare*, 2012, 2 (11):144-148
7. Umar, M. B.; Ojo A.S.; Asala, S.A. Comparison of Cephalometric Indices Between the Hausa and Yoruba Ethnic Groups of Nigeria. *Research Journal of Medical Sciences* 2011, 5(2): 83-89
8. Ewunonu E.O. Incidence of brachycephalization among Nigerians *Journal of Scientific and Innovative Research* 2016; 5(2): 43-45
9. Okupe, R. F., Coker, O. O. & Gbajumo, S. A. Assessment of biparietal diameter during normal pregnancy in Nigerian women. *Br. J. Obstet. Gynaecol.*, 1984, 99 (7):629-632.
10. Mador E. S, Goncim H. Y, P am I. C, Mutihir J. T, Adoga G. I, Ogunranti J. O. Cephalic index: A fetal Gestational Age dependent biometric parameter. *Asian journal of Medical Sciences* 2011,1 (10): 45-48
11. Ugwu A. C.; Ewunonu O. E.; Ovuoba K. N. Sonographic Assessment of Fetal Cephalic Index in a Nigerian Population: A Novel Paradigm. *Journal of Diagnostic Medical Sonography* 2007.23(2):87-90
12. Hadlock FP, Deter RL Carpenter RJ, Parker SK. Estimating fetal age: Effect of head shape on BPD. *American Journal of Roentgenology* 1981; 137 (1):83- 85
13. Gray D. L, Songster G. S, Parvin C. A and Crane J. P. Cephalic Index; A gestational age-dependent biometric parameter. *Obstetrics and Gynaecology* 1989;74(4):600-603
14. Cambell, S. The prediction of foetal maturity by ultrasonic measurements of biparietaldiameter. *Journal of Obstetrics and Gynecology, British commonwealth*, 1969, 76 (7): 603-609

Ayang and Abonyi: Ultrasound-estimated fetal cephalic index

15. Chudleigh, T. and Thilaganathanm, B. Obstetric ultrasound, How, Why and When. Elsevier Churchill Livingstone. Third edition 2004, page 99-100. ISBN 0 443 054711
16. Esomonu U. G. and Badamasi M. I, Cephalic anthropometry of Ndi Igbo of Abia State of Nigeria. Asian Journal of Scientific research, 2012, 5(3): 178-184
17. Jervas E, Anele TI, Iwuoha G, Eke, CC, Osuchukwu IW. Cephalic index of the Igbos, Nigeria. Anthropol Open J. 2016; 1(1): 23-26.
18. Layperuma, I. Evaluation of cephalic indices: a clue for racial and sex diversity. Int. J. Morphol., 2011. 29(1):112-117.
19. Yagain, V. K.; Pai, S. R.; Kalthur, S. G.; Chethan, P. &Hemalatha, I. Study of cephalic index in Indian students. Int. J. Morphol., 2012. 30(1):125-129.
20. Rajlakshmi Ch, Shyamo Singh M., Bidhumukhi Devi Th. Chandramani Singh L. Cephalic Index of Foetuses of Manipuri Population—A Baseline Study, Anat. Soc. India 2001, 50(1) 8-10

How to cite: Ayang, OL and Abonyi, LC. Variation of Prenatal Ultrasound-Estimated Cephalic Index; A Comparative Study of Igbo, Hausa and Yoruba Ethnic Groups in Nigeria. J Rad & Radiat Sci, 2018; 32 (1): 76 - 80