

CASE REPORT

Cosmetic Gynecology

## Extensive rectovaginal space hematoma causing urine retention as a complication of vaginoplasty: A case report

Francis Were<sup>1\*</sup>, Kristina Sule<sup>2</sup>, James Njiru<sup>1</sup>, Nyakinyua Kiruku<sup>3</sup>, Victoria Muviku<sup>1</sup>

<sup>1</sup> Department of Obstetrics and Gynecology, Kenyatta University, Nairobi, Kenya

<sup>2</sup> Allora Medical Practice, Nairobi, Kenya

<sup>3</sup> School of Health Sciences, Kenyatta University, Nairobi, Kenya

\*Correspondence: werefrancis62@gmail.com

Received: 23 November 2023; Revised: 7 January 2024; Accepted: 24 January 2024; Available online: January 2024

Copyright © 2024, The authors. Published by JOGECA. This is an open access article under the terms of the Creative Commons Attribution 4.0 International License (<http://creativecommons.org/licenses/by/4.0/>), which permits unrestricted reuse, distribution, and reproduction in any medium provided the original author(s) and the source are properly cited.

### Abstract

**Background:** Rectovaginal space hematoma following vaginoplasty is a rare complication that can lead to serious morbidity and disability. In the literature, reported cases remain few, especially in low-income countries where cosmetic gynecology consultations are increasing.

**Case presentation:** We present a case of extensive rectovaginal space hematoma presenting with urine retention following vaginoplasty. The patient had anemia, hypotension, tachycardia, vulval swelling, and

a suprapubic mass from the overdistend bladder. She was surgically managed and did well postoperatively.

**Conclusion:** Rectovaginal space hematomas are rare and associated with significant morbidity if inappropriately managed. Cosmetic gynecological surgeons should be aware of this complication.

**Keywords:** hematoma, rectovaginal space, urine retention, vaginoplasty

### Introduction

Nonobstetric vulvovaginal hematomas are rare and have an incidence of <1% of all gynecological admissions (1). Rectovaginal space hematomas are rarer. Our literature search did not encounter any rectovaginal space hematoma following vaginoplasty. Vaginal hematomas can reach massive size because the subcutaneous tissue in the vagina is quite pliable (2). The rectovaginal space is the space adjacent to the vaginal wall mucosa extending from the vulva inferiorly to the extraperitoneal space superiorly bound by the peritoneal reflections on the bladder, uterus, rectum, and broad ligament constitutes a large potential space that can accumulate and conceal a

large amount of blood (3). It is an important anatomical landmark in gynecological surgery. The space is made up of loose areolar tissue, which makes dissection in pelvic surgeries easier. In addition, it contains blood vessels such as the presacral veins, middle rectal artery, and vaginal veins (3). These vessels may be injured because of trauma or surgery through the rectovaginal space. Small rectovaginal hematomas may be managed conservatively; however, extensive hematomas require surgical drainage (4). Large hematomas can result in significant morbidity including pain, disability, anemia and hypovolemic shock, necrotizing fasciitis, infection, and urine retention (1, 4). The external female genitalia is well vascularized and derives arterial blood supply from the internal iliac artery through several branches of

the pudendal artery, whereas venous drainage is by labial veins, which drain into the external and internal pudendal veins (1). Hematoma formation following vaginoplasty or perineoplasty is rare. These vaginal tightening procedures are associated with <2% of complications (5).

### Case presentation

A para 4+0 presented with loss of sexual drive and anorgasmia during coitus. She also complained of vaginal flatulence and complete loss of vaginal grip during coitus. She had a history of delivering large babies. In two deliveries, the patient sustained third- and fourth-degree perineal tears. Upon assessment, the introitus admitted five fingers very comfortably, and an old third-degree perineal tear was noted. The patient requested vaginal tightening to restore her self-esteem. The patient was counseled for planned and performed surgery with no intraoperative complications. Forty-eight hours later, the patient reported heavy bleeding and difficulty in passing urine despite the urge. On examination, the patient was noted to be pale and in pain, and the bladder was distended up to the level of the umbilicus. Her hemoglobin levels were 6.7g/dl. Ultrasound revealed a large rectovaginal clot 8.3 x 6.5 x 8.1 cm approximately 227mls (Figure 1). An indwelling Foley catheter was inserted, and the patient was taken to the theatre. Intraoperatively, rectovaginal clots filling a large kidney dish were evacuated. Rugged vaginal edges where the sutures had given way were noted. We flushed the rectovaginal space with normal saline, hemostatic sponges were inserted in the areas where the clots were removed and plication sutures were inserted. A vaginal pack was inserted and left in situ for 24 hours. The patient was transfused with four units of packed red cells. Check hemoglobin levels at discharge were 11g/dl.

### Discussion

Rectovaginal hematomas are rare and potentially morbid gynecological complications (6). There are very few case reports on rectovaginal hematomas in the literature, which limits awareness of diagnosis and management. In most cases, they are attributed to trauma to the vaginal wall. This is because the subcutaneous tissue of the vaginal wall is prone to injury and bleeding. In addition, the pliability of the tissue gives room for the expansion of the concealed hematomas to massive sizes (2,4). Rectovaginal hematomas develop in the loose areolar tissue containing space below the rectouterine pouch (7,8). Anatomically, this space is formed by the posterior vaginal wall ventrally,

the anterior wall of the rectum dorsally, and the uterosacral ligaments laterally (7). The cranium of the space is formed by the peritoneal reflections of the pouch of Douglas, whereas the caudal boundary is formed by the levator ani muscle (6, 7). The space is formed by loose areolar tissue that allows for bleeding and the formation of large hematomas. Small hematomas are usually managed conservatively, whereas large ones require prompt diagnosis and immediate surgical management.

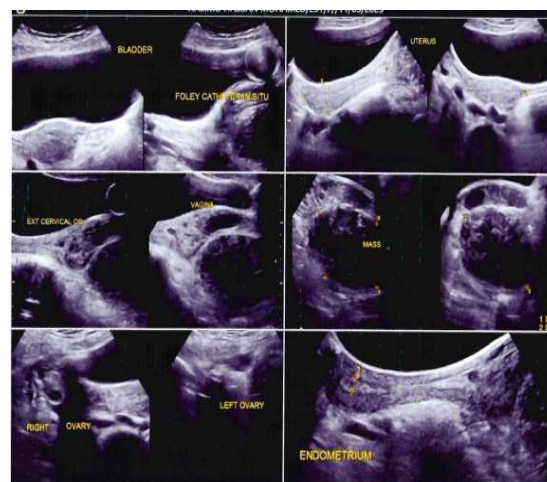


Figure 1: Ultrasound showing a large rectovaginal space mass

Massive hematomas are potentially life-threatening. They are associated with major complications such as hemodynamic instability, urine retention, vulvovaginal swelling, rectal tenesmus, and pelvic pain (4). Slow bleeding may lead to the development of extensive hematomas that occlude the vaginal orifice, leading to urine retention. Urine retention is a key diagnostic feature of large rectovaginal hematomas (4). Most of the time, it may go unnoticed, but severely affected patients may present with bladder distention and inability to urinate despite the urge. Patients with urinary retention should be catheterized to empty the bladder before any surgical procedure is performed to prevent bladder injuries. The diagnosis of rectovaginal hematomas is mostly clinical. In our case, the patient presented postoperatively after a vaginoplasty procedure with symptoms of inability to urinate despite the urge, heavy per vaginal bleeding, pain, vulval swelling, and bladder distention. On ultrasound, a large rectovaginal hematoma was observed, which necessitated prompt surgical evacuation and blood transfusion to stabilize her hemodynamic status. There is little information to support the occurrence of rectovaginal hematomas following gynecological procedures (7). However, trauma to

the vaginal wall and vessels following radical hysterectomy has been associated with the development of massive rectovaginal hematomas (5). Moreover, as an important pelvic landmark, the avascular rectovaginal space is exposed to bleeding during gynecological procedures such as rectocele, fistula, and vaginal vault prolapse repairs (7,8).

Vaginoplasty is a procedure performed either for gender reaffirmation or to tighten the vaginal muscles in cases of laxity, as in our patient (9). It involves ligating the redundant perineal tissue and suturing the remaining tissues together using plication sutures (5). As a surgical procedure, it bears the risk of injuring the pudendal vessels and causing bleeding. Small hematomas are common postoperatively and rarely require management. However, large hematomas are rare following the procedure (9). In most cases, bleeding in the rectovaginal space involves the vaginal veins, presacral veins, and the middle rectal artery or vein (7). Blood may also seep slowly into the space through suture lines and edges, as in our patient. Female cosmetic gynecological procedures such as vaginoplasty, labioplasty, and perineoplasty are on the rise in low- middle-income countries. This has not only led to cultural but also increased the number of medical implications. As a new and developing subspecialty in low-resource centers, there is minimal research and reports in the literature on the potential gynecological complications of these procedures (10). Therefore, cosmetic gynecologists should invest in research to enhance awareness and prepare them to manage complications as they arise.

## Conclusion

Rectovaginal space hematomas are rare and can be associated with significant morbidity if inappropriately managed. Cosmetic gynecological surgeons should look out for this complication.

## Consent for publication

Informed consent for publication was obtained from the patient.

## Declarations

## Conflict of interest

The authors declare no conflicts of interest.

## Funding

None

## References

1. Mangwi AA, Ebasone PV, Aroke D, Ngek LT, Nji AS. Non-obstetric vulva haematomas in a low resource setting: two case reports. *Pan Afr Med J.* 2019;33:314. Published 2019 Aug 20. doi:10.11604/pamj.2019.33.314.19488
2. Awoleke JO, Ipinnimo OM. Vulvovaginal Infralevator Haematoma Mimicking the Second Stage of Labour. *Case Rep Obstet Gynecol.* 2017;2017:8062793. doi:10.1155/2017/8062793
3. Stobie W, Krishnan D. Large concealed paravaginal haematoma: A case report of an occult postpartum haemorrhage. *Case Rep Womens Health.* 2021;30:e00311. Published 2021 Mar 26. doi:10.1016/j.crwh.2021.e00311
4. Sinha S, Agarwal M, Singh S. Large Vaginal Hematoma in a Puerperium Patient: Treating a Delayed Diagnosis & Management Caused by an Incomplete Clinical Examination. *Cureus.* 2023;15(1):e33386. Published 2023 Jan 5. doi:10.7759/cureus.33386
5. Furnas HJ, Canales FL. Vaginoplasty and Perineoplasty. *Plast Reconstr Surg Glob Open.* 2017;5(11):e1558. Published 2017 Nov 9. doi:10.1097/GOX.0000000000001558
6. Di Donato V, De Medici C, Fischetti M, Perniola G, Palaia I, Benedetti Panici P. Rectovaginal septum hematoma: conservative management of a rare complication after radical hysterectomy. *Eur J Obstet Gynecol Reprod Biol.* 2013;167(1):119-120. doi:10.1016/j.ejogrb.2012.12.004
7. Kostov S, Slavchev S, Dzhakov D, Mitev D, Yordanov A. Avascular Spaces of the Female Pelvis-Clinical Applications in Obstetrics and Gynecology. *J Clin Med.* 2020;9(5):1460. Published 2020 May 13. doi:10.3390/jcm9051460
8. García-Gausí M, García-Armengol J, Mulas Fernández C, et al. Surgical Anatomy of the Rectovaginal Space: Does a Standalone Rectovaginal Septum or Denonvilliers Fascia Exist in Women?. *Dis Colon Rectum.* 2021;64(5):576-582. doi:10.1097/DCR.0000000000001912
9. Li JS, Crane CN, Santucci RA. Vaginoplasty tips and tricks. *Int Braz J Urol.* 2021;47(2):263-273. doi:10.1590/S1677-5538.IBJU.2020.0338
10. Barbara G, Facchin F, Buggio L, Alberico D, Frattaruolo MP, Kustermann A. Vaginal rejuvenation: current perspectives. *Int J Womens Health.* 2017;9:513-519. Published 2017 Jul 21. doi:10.2147/IJWH.S99700