

MORPHOLOGICAL PRESENTATION OF THE AMELIORATIVE EFFECTS OF BRYOPHYLLUM PINNATUM ON ALCOHOL-INDUCED GASTRIC INJURY IN ADULT WISTAR RATS

G. I. Eze¹ and E. Aideyan²

ABSTRACT

Bryophyllum pinnatum is a plant, reported for its variety of ethno-medicinal uses. This study was undertaken to determine the morphological changes brought about by *Bryophyllum pinnatum* on alcohol-induced gastric injury. Whole plant of *Bryophyllum pinnatum* was successfully extracted with water. Low dose aqueous extract of the plant (150 mg/kg body weight), moderate dose (300 mg/kg body weight) and high dose (600 mg/kg body weight) were administered. Thirty (30) healthy adult wistar rats of both sexes were divided into six (6) groups (A to F) of five rats each. Group A received feeds and water only. Gastric mucosal injury was induced in Group B to F using 80% ethanol after 24 hours fasting with free access to water. Group C, D and E received aqueous extracts of the *Bryophyllum pinnatum*, (150, 300, 600 mg/kg body weight respectively). Group F received 20mg Omeprazole. The treatment lasted for a duration of twenty-eight days. Weekly weight measurement of individual rats was carried out. The rats were sacrificed an hour after the last dose and the stomach harvested and processed for histological analysis. The study established the anti-ulcer properties of *Bryophyllum pinnatum*, and demonstrated that the aqueous extracts of *Bryophyllum pinnatum* restored the histological integrity of the stomach mucosa, with the group given 600 mg/kg body weight extract achieving the best ameliorative effect. The groups given the extract also demonstrated increase in weight.

KEY WORDS: *Bryophyllum pinnatum*, morphological presentation, alcohol induced gastric injury, aqueous extracts.

INTRODUCTION

Bryophyllum pinnatum is a widely used perennial herb in folk medicine in tropical Africa, tropical America, India, China, Australia and southern part of Nigeria. The plant flowers in November-March and fruits in April^[1].

The leaves and bark are bitter tonic, astringent to the bowels. In common with other Crassulaceae, *Bryophyllum pinnatum* has been found to contain bufadienolide^[2]. Bufadienolide compounds isolated from *Bryophyllum pinnatum* include Bryophyllin A, which has shown strong anti-tumor promoting activity in vitro. Bryophyllin C has also shown insecticidal properties^[3]. Reviews highlight the various ethnopharmacological uses of *B. Pinnatum* and also pinpoint its

G. I. Eze¹ and E. Aideyan²

¹Department of Anatomy, School of Basic Medical Sciences,
College of Medical Sciences,
University of Benin, Benin City, Nigeria.
ikechi.eze@uniben.edu +2348033750269

Corresponding author: E. Aideyan

²Department of Medical Laboratory Science, School of Basic
Medical Sciences, College of Medical Sciences, University of
Benin, Benin City, Nigeria.
emmanuel.aideyan@bmedsci.uniben.edu +2348033695996

unexplored potentials^[4]. There is growing interest in the use of this plant's herbal formulations because of their effectiveness, minimal side effects and relative low cost^[5].

In traditional medicine, the leaves of this plant have been used for their antimicrobial, antifungal, anti-inflammatory, sedative, antihypertensive, analgesic, carminative, anti-allergic, anti-histamine, and of course anti-ulcer activities^[6-12]. Besides its well-known haemostatic and wound healing properties, it is also traditionally used for the treatment of ear ache, in ophthalmic preparations, sprains and in dysmenorrhea^[13]. A water extract of *Bryophyllum* leaves administered topically and internally has been shown to prevent and treat Leishmaniasis^[14], diarrhoea and vomiting^[11] as well as stomach ulcers^[15]. Gastric ulcer is a lesion occurring at a site where the mucosal epithelium is exposed to acid, alcohol and pepsin. Gastrointestinal disorders (such as ulcers, hyperacidity and inflammation) are very common, causing tremendous human suffering worldwide. Ulcerative lesions of gastrointestinal tract are some of the major side effects associated with alcohol consumption^[16]. These disorders are mostly due to an imbalance between damaging factors within the lumen and protective mechanisms within the gastrointestinal mucosa^[17]. This work evaluated the morphological presentations of the therapeutic effects and healing properties of *Bryophyllum pinnatum* on alcohol induced gastric ulcer in wistar rats.

METHODOLOGY

Study design

This study involved both the use of experimental and observational methods.

Collection and identification of Plant

Fresh leaves of *Bryophyllum pinnatum* were collected from the Junior Staff Quarters of University of Benin, Benin City, Nigeria, in June 2015. It was identified and authenticated by a taxonomist / Senior Laboratory supervisor of Pharmacognosy Department, University of Benin, Benin City, Nigeria. A voucher specimen was deposited at the herbarium.

Preparation of extract

Adulterants were carefully picked out and the leaves thoroughly rinsed in tap water. The leaves were chopped, shade-dried and the plant extract was prepared by pulverizing 500g of the fresh leaves of *Bryophyllum pinnatum* in a mechanical grinder. The chopping, drying and pulverization was to enable the sample enter the Soxhlet apparatus and also to provide a large surface area for the extraction. The pulverized leaves were extracted exhaustively in 100ml. of distilled water and kept at 40 °C for 24 hours to obtain the aqueous extract. The resulting mixture was filtered. Fresh preparation was used for each experimental run. The dried sample was stored in amber-coloured bottles in a fridge (40 °C) until it was ready to be used. Samples used throughout the period of the study were weighed from the stored sample.

10g of the dried *Bryophyllum pinnatum* was weighed out daily and diluted in 100ml of distilled water to give a concentration of 100mg/ml (0.1g/ml).

For administration, the aqueous extract was reconstituted in distilled water and administered orally to the animals according to the experimental protocol. Any unused diluted sample was discarded at the end of each experiment.

Experimental animals

Thirty adult healthy Wistar rats of both sexes weighing between 150-250g were used for this study. The animals were procured from the animal holding of Anatomy department, University of Benin, Nigeria. They were divided into six groups of five animals each and maintained at room temperature. The rats were kept in plastic cages (a group per cage) for two weeks before the commencement of the experiment to allow the animals acclimatize to the environment. They were allowed free access to clean drinking water and were fed on standard rat pellets throughout the period of study. The animals were handled according to the guidelines for animal research as outlined in the NIH Guidelines for the Care and Use of Laboratory Animals [18].

Experimental protocol and alcohol-induced gastric injury

The rats were randomly divided into six groups. The animals in group A were fed orally with feed and water only. Those in groups B, C, D, E and F were administered with 1ml of 80% ethanol orally after 24 hours fasting

with free access to water for the purpose of inducing gastric mucosal injury [19,20]. Twenty four hours later, the animals in the groups C, D and E were orally administered with aqueous extracts of the *Bryophyllum pinnatum* [21] at doses of 150, 300 and 600mg/kg body weight respectively, while those in group F were then administered with 20mg Omeprazole, a standard anti-ulcer agent [22]. These treatments were administered daily for twenty-eight days. The dosages of the alcohol and plant extract used resulted from acute toxicity studies and reviewed literature. The plant extract was usually administered after reconstitution in distilled water. The weights of individual rats from each group were measured weekly, using electronic weighing scale and the values recorded. One hour after the last dose, the rats were sacrificed by an overdose of anaesthesia with chloroform. The abdominal region of each wistar rat was dissected and the stomach carefully harvested.

Tissue processing

The stomach was removed, and immediately fixed in 10% Neutral Buffered Formalin. After fixation, the tissues were transferred into an automatic processor where they went through a process of dehydration in ascending grades of alcohol (ethanol) 70%, 80%, 95% and absolute alcohol for two (2) changes each. The tissues were then cleared in xylene and embedded in paraffin wax. Serial sections of five (5) micron thick were obtained using a rotary microtome. The tissue sections were deparaffinised, hydrated and stained

using the routine haematoxylin and eosin staining method (H&E) described by Drury and Wallington, 1980^[23].

Histology and photomicrography

After staining tissues for histological studies, sections were viewed and examined with an Olympus XSZ-107BN microscope by an Anatomist and Consultant Histopathologist, and photomicrographs were taken by an attached Eakins 1080P microscopic camera at the Department of Anatomy, University of Benin, Benin City.

RESULTS

As shown in figure 1, there was significant increase ($P < 0.05$) in the body weight of Groups A, C, D, and E, while Groups B and F showed no significant increase ($P > 0.05$).

Figure 2 shows the gross demonstration of gastric ulcer following dissection of the harvested stomach of the adult wistar rat, as well as the comparatively normal gastric mucosa of rat from the control group.

Histologically, it was demonstrated that rats in Group A which served as the negative control showed normal gastric mural architecture (Plates 1 and 2). Plates 3 and 4 show stained tissue sections from Group B given ethanol only and depicting irregularly shaped mucosal ulcers. Plates 5 and 6 showed fairly normal mucosa following ethanol induction and subsequent administration of a standard anti-ulcer agent (Omeprazole 20 mg). When low dose of aqueous extract of *Bryophyllum pinnatum* (150 mg/kg body weight) was administered to animals in Group C after induction

using 80% ethanol, the mural architecture also showed fairly normal mucosa (Plates 7 and 8). When moderate dose of aqueous extract of *Bryophyllum pinnatum* (300 mg/kg body weight) was administered to animals in Group D after induction with 80% ethanol, the mucosa also appeared fairly normal (Plates 9 and 10). Plates 11 and 12 which are H & E stained tissue sections depicting the group administered high dose (600 mg/kg) aqueous extract of *Bryophyllum pinnatum* following the induction with ethanol revealed normal architecture of the gastric mucosa.

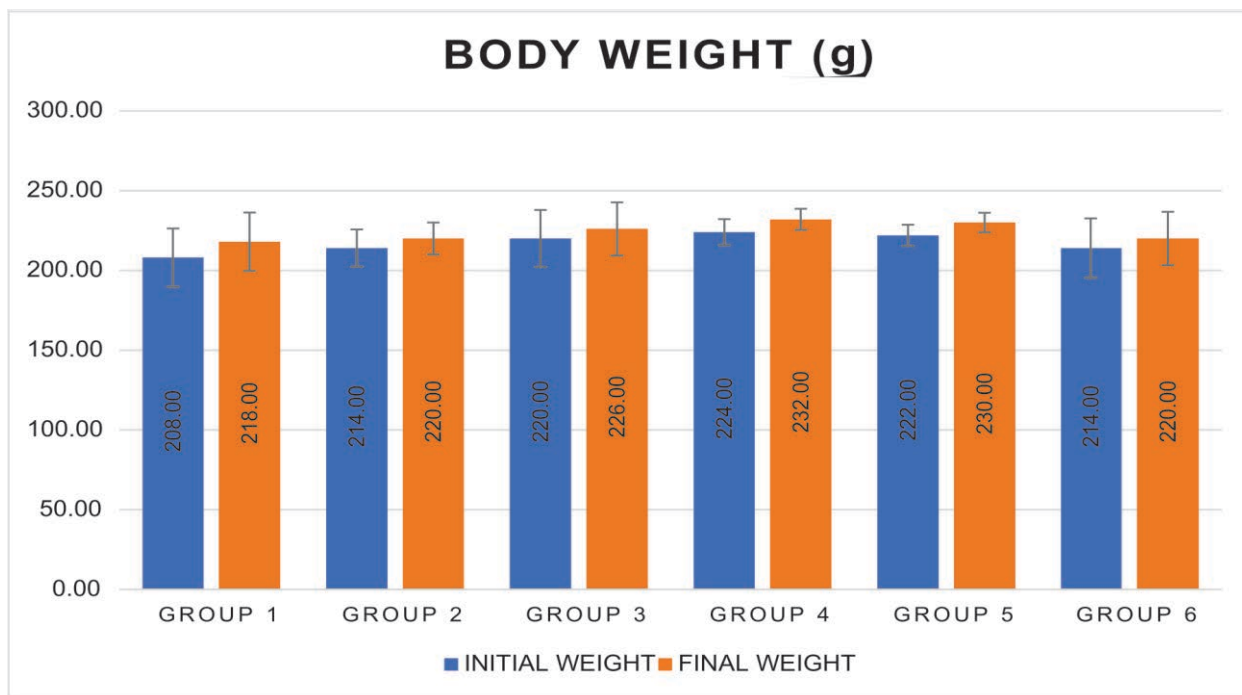


FIGURE 1: Chart showing changes in body weight across the experimental groups.

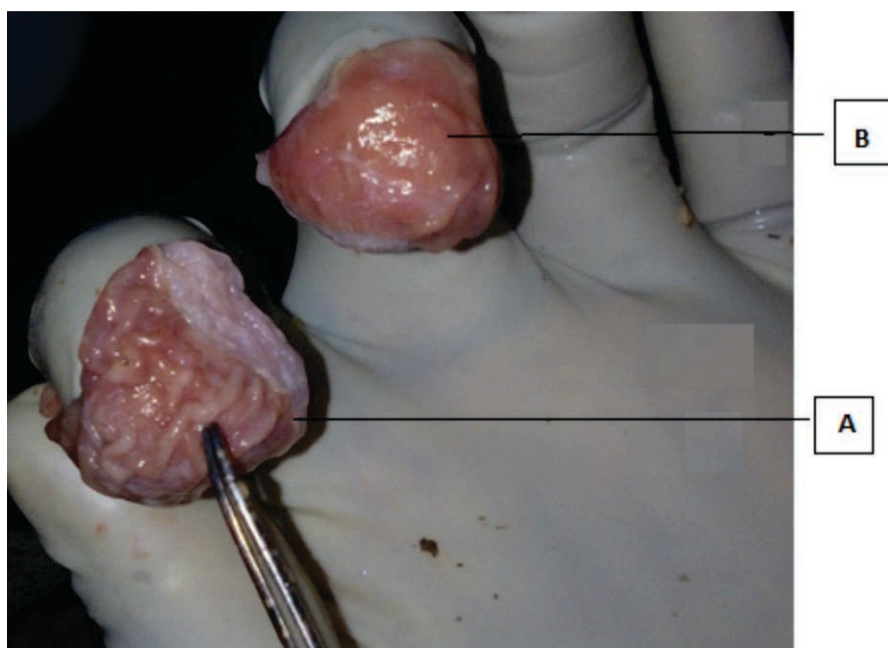


FIGURE 2: Photograph of harvested rat stomachs showing alcohol induced mucosal injury (A) and normal mucosa from negative control (B) Sections were microscopically viewed and examined after staining tissues for histological studies and confirmatory results were reported as shown by the following photomicrographs.

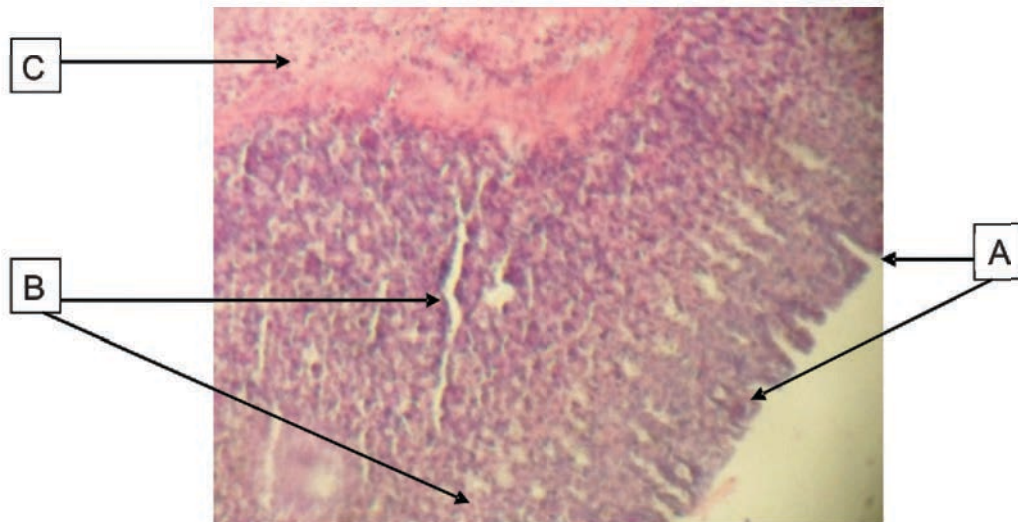


Plate 1: Group A, served as control and shows rat stomach composed of A, gastric pits, B, mucosal glands and C, muscularis mucosa (H&E x 40)

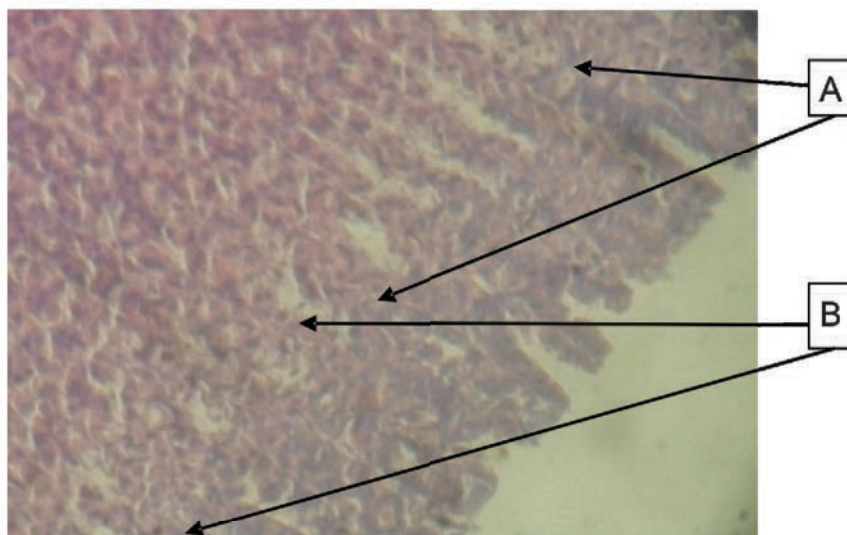


Plate 2: The same group (Control group) with higher magnification (H&E x 100)

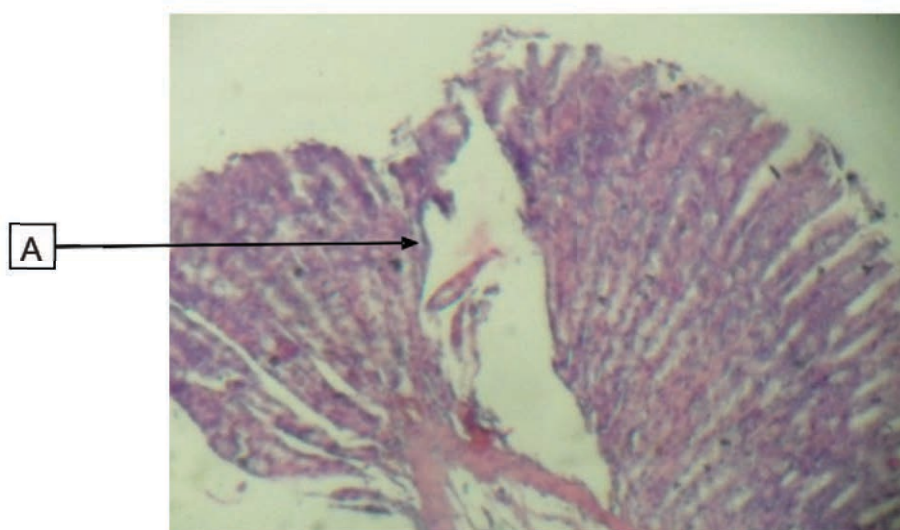


Plate 3: Presented as group B, depicting rat stomach given ethanol only showing A, irregularly shaped mucosal ulcer (H&E x 40)

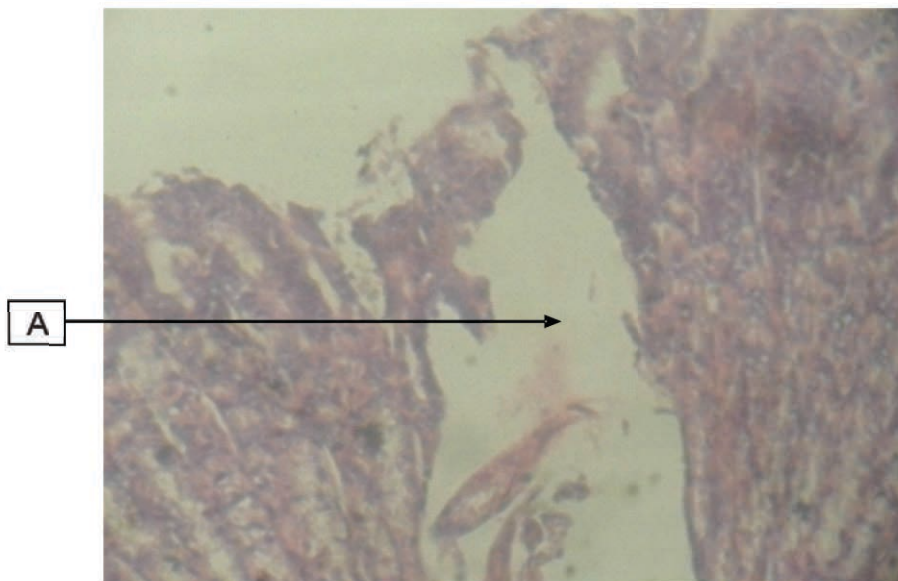


Plate 4: The same group (B) with higher magnification, depicting rat stomach given ethanol only showing A, irregularly shaped mucosal ulcer (H&E x 100)

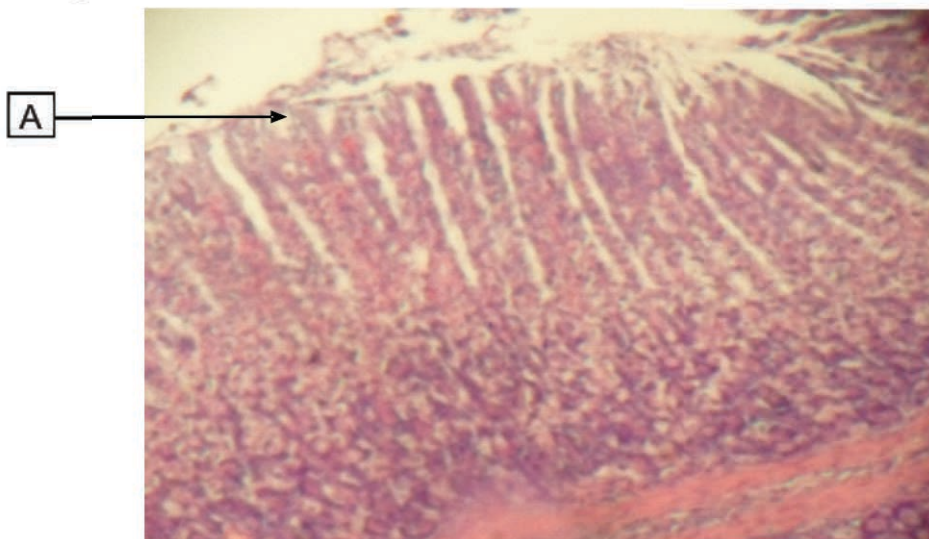


Plate 5: Group F, depicting rat stomach given ethanol followed by omeprazole showing A, fairly normal mucosa (H&E x 40)

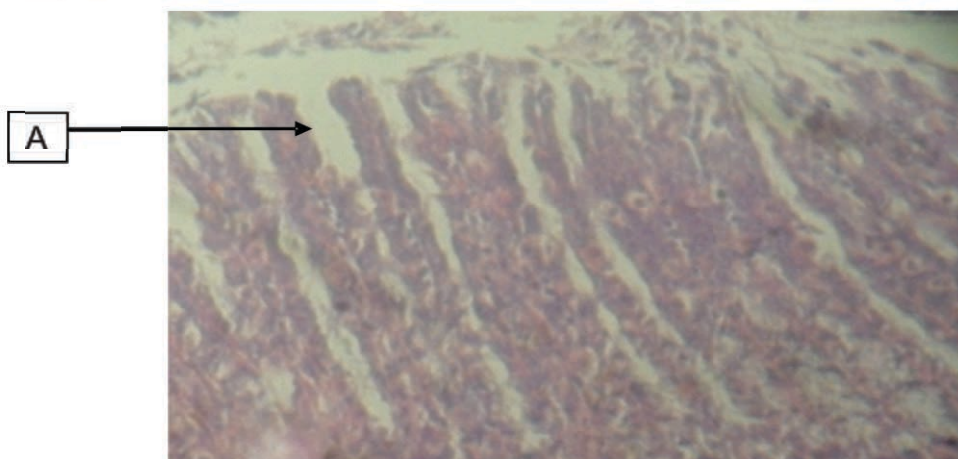


Plate 6: The same group (F) with higher magnification depicting rat stomach given ethanol and omeprazole showing A, fairly normal mucosa (H&E x 100)

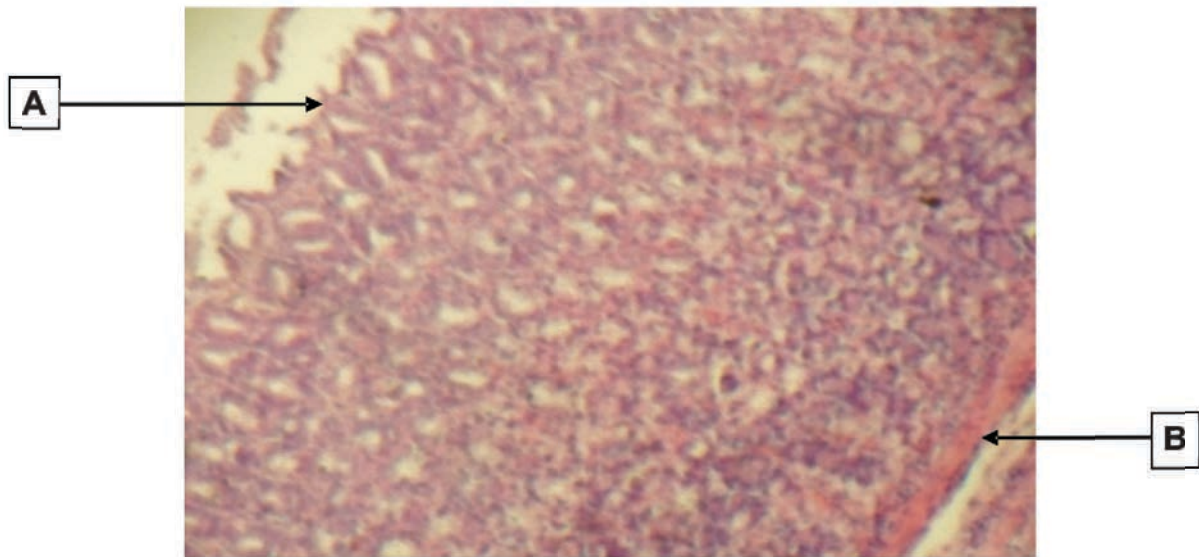


Plate 7: Rat stomach given ethanol, then 150 mg/kg extract (group C) showing A, fairly normal mucosa and B, muscularis mucosa (H&E x 40)

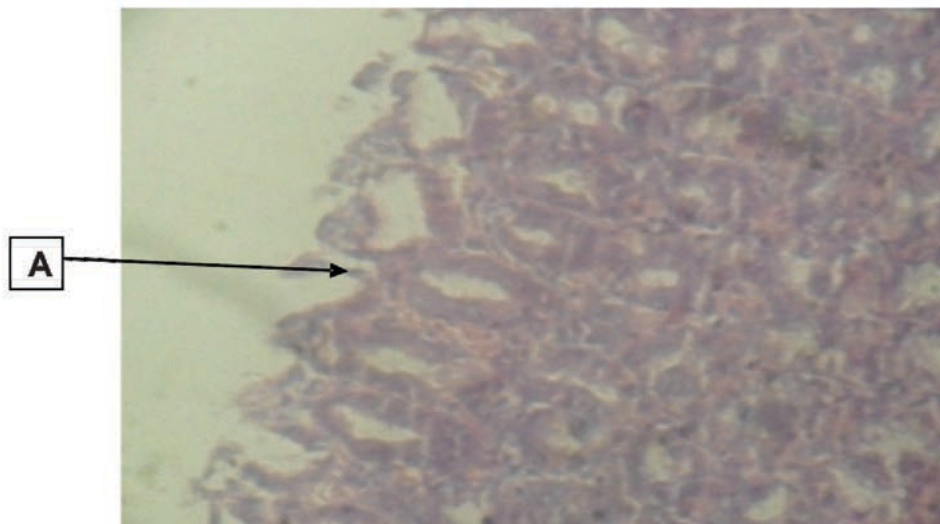


Plate 8: The same group (C) with higher magnification depicting rat stomach given ethanol then 150 mg/kg extract showing A, fairly normal mucosa (H&E x 100)

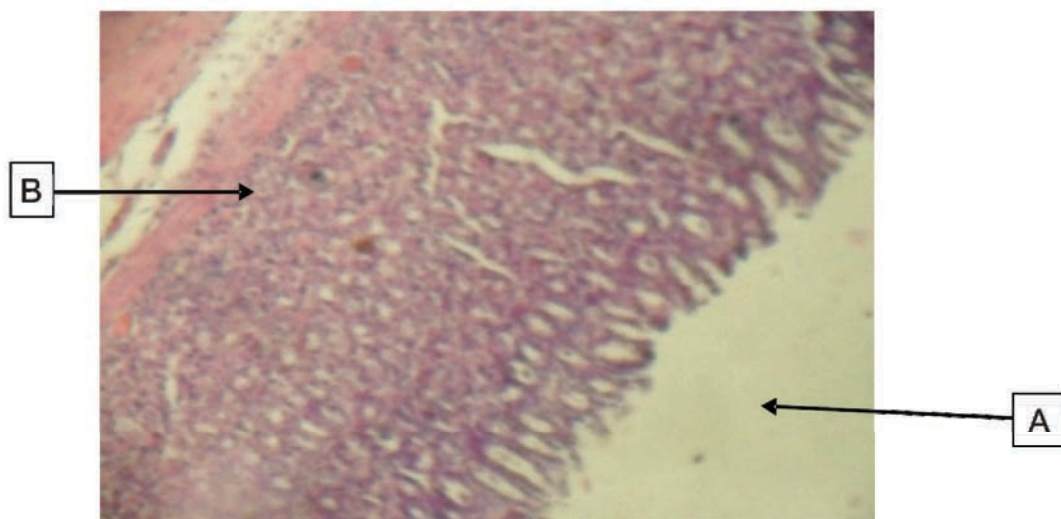


Plate 9: Rat stomach given ethanol, then 300 mg/kg extract (group D) showing A, fairly normal mucosa and B, muscularis mucosa (H&E x 40)

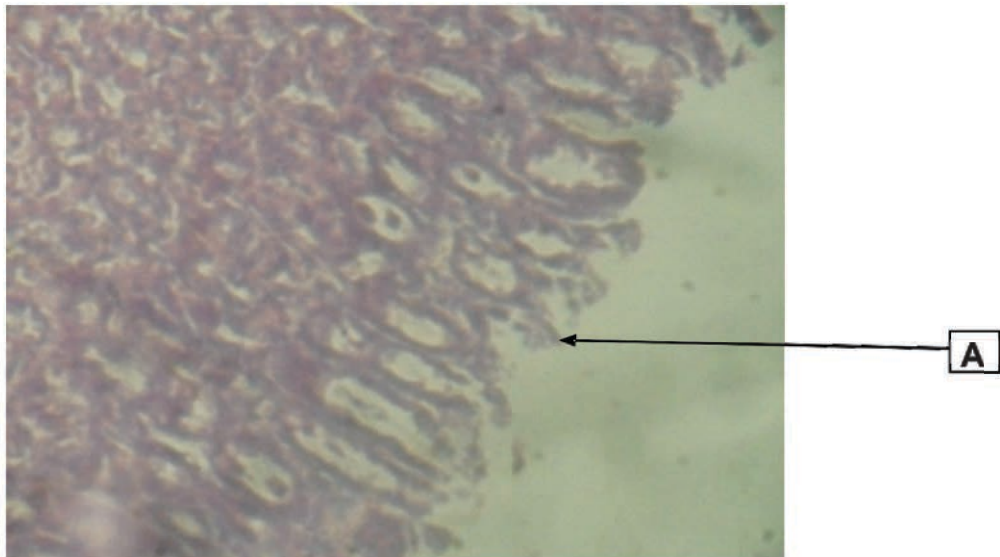


Plate 10: The same group (D) with higher magnification depicting rat stomach given ethanol, then 300 mg/kg extract showing A, fairly normal mucosa (H&E x 100)

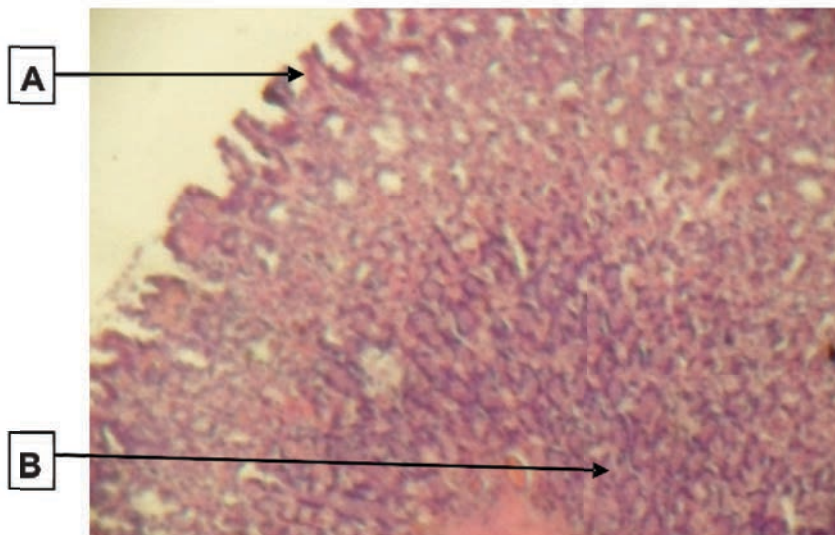


Plate 11: Rat stomach given ethanol, then 600 mg/kg extract (group E) showing A, normal mucosa and B, muscularis mucosa (H&E x 40)

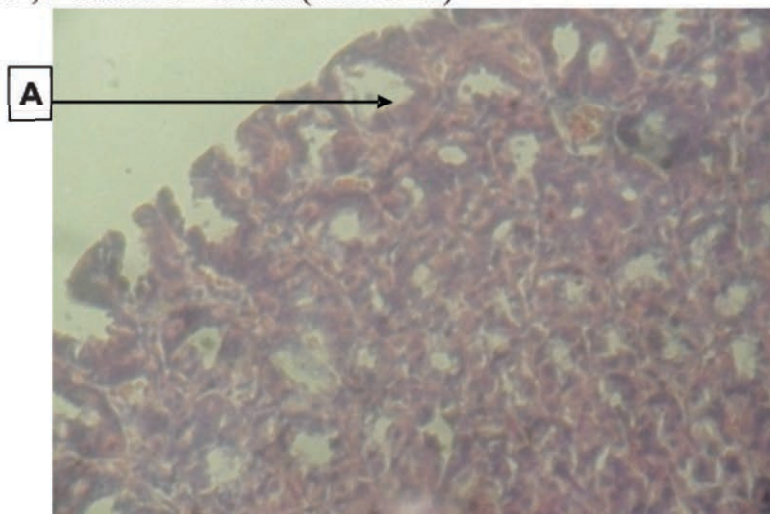


Plate 12: The same group (E) with higher magnification depicting rat stomach given ethanol, then 600 mg/kg extract showing A, normal mucosa (H&E x 100)

DISCUSSION

Alcohol is one of the most commonly abused substances in the world, and it also has a role in the development of tumors of the gastrointestinal tract^[20]. Several studies have shown that alcohol could adversely affect the gastric mucosa. One of such is a descriptive endoscopic study of the action of pure ethanol on the gastric mucosa in healthy humans carried out by Knoll et al^[25] which reported that the effects of alcohol on the gastric mucosa are dose-dependent, and the damage becomes visible as early as 30 minutes after ingestion.

On the other hand, pharmacological investigations of the leaf extract of *B. pinnatum* have indicated anti-inflammatory and analgesic activity^[26]. Thus, this informed the decision of the researchers to carry out this study, assessing the morphological presentation of the effects of *Bryophyllum pinnatum* on alcohol-induced gastric injury in the adult wistar rat. To establish gastric mucosal injury; the lumen, mucosa and the lining epithelium were examined.

Gastric mucosal injury was induced by alcohol and this appeared as an irregularly shaped tear, as revealed by photomicrographs in plates 3 and 4, representing the group administered with alcohol only. The gastric mucosal injury induced appeared as an excavation which extended through the muscularis mucosa into the submucosa and even deeper. This confirmed the induced gastric injury to be an ulcer and agrees with reports by Abdel-Salam et al^[27].

Both acute and chronic alcohol

consumption can interfere with stomach functioning in several ways. Alcohol has been known to alter gastric acid secretion as well as induce acute gastric mucosal injury. It is a widely known fact that alcohol consumption can cause mucosal inflammation, which may lead to mucosal damage^[28].

The present study demonstrated that gastric injury can be induced on the stomach mucosa of Wistar rats treated with ethanol. This is in harmony with results from the work carried out by Hollander et al^[29], who also induced gastric injury, using alcohol. However, it is evident from the results of the present investigation that the aqueous leaf extract of *B. pinnatum* ameliorated the acute ulcers induced by alcohol in the stomach of adult Wistar rats.

Ingestion of aqueous extracts of *Bryophyllum pinnatum* at different doses (150mg/kg bw, 300mg/kg bw and 600mg/kg bw) ameliorated the acute ulcers induced in the stomach of rat, although the highest dose of the extract (600mg/kg b.w) achieved the best ameliorative effect and restored the histoarchitecture of the gastric mucosa the most. This finding is in agreement with Sharma et al^[30] who carried out a similar study.

The morphological changes revealed that the leaf extract gave better ameliorative effect than that seen with the standard anti-ulcer agent (Omeprazole). This is comparable to an earlier study by Mozafar and Hossein^[31] who reported that various doses of a similar plant, *Falcaria vulgaris* (50, 100, 150 mg/kg) produced a greater protection than

ranitidine (50mg/kg) against the necrotizing effect of ethanol, when given intragastrically to rats.

All the experimental groups administered with *B. pinnatum* also showed a statistically significant ($P < 0.05$) increase in body weight, while the groups administered with alcohol only, and that of the standard drug (omeprazole) showed no statistically significant ($P > 0.05$) body weight gain. According to Wong^[32], alcohol has been known to prevent weight gain. That the rats in the groups administered with *B. pinnatum* were able to gain weight, despite being induced by alcohol, is suggestive of the ameliorative and nutritional properties of *B. pinnatum* on the stomach and whole body of adult wistar rats.

CONCLUSION

Alcohol induced ulcer in the gastric mucosa. When Omeprazole was given as well as graded doses of the *Bryophyllum pinnatum*, there was amelioration of the ulcer, with amelioration by the extract being slightly better than that of Omeprazole and with 600 mg/kg achieving the best effect. The implication of this is that *B. pinnatum* is of better pharmacological effect for the amelioration of gastric toxicity hence recommended for pharmaceutical utilization as routine anti-ulcer drugs.

REFERENCES

1. Kamboj A, Saluja AK. *Bryophyllum pinnatum* (Lam.) Kurz.: Phytochemical and pharmacological profile: A review. *Pharmacognosy Reviews*. 2009 Jul 1;3(6):364.
2. Steyn PS, van Heerden FR. Bufadienolides of plant and animal origin. *Natural Product Reports*. 1998;15(4):397-413.
3. Supratman U, Fujita T, Akiyama K, Hayashi H. New insecticidal bufadienolide, bryophyllin C, from *Kalanchoe pinnata*. *Bioscience, biotechnology, and biochemistry*. 2000;64(6):1310-2.
4. Varier VP. Indian medicinal plants a compendium of 500 species Orient Longman. Publication Madras India. 1996;134.
5. Dutta A, Chimi H, Lahkar M. Evaluation of Anticonvulsant Potential of *Bryophyllum Pinnatum* in Experimental Animals. *Asian Journal of Biomedical and Pharmaceutical Sciences*. 2015 Jan 12;5(41):0-.
6. Oliver-Bever B. Medicinal plants in tropical West Africa III. Anti-infection therapy with higher plants. *Journal of ethnopharmacology*. 1983 Nov 1;9(1):1-83.
7. Misra SB, Dixit SN. Antifungal activity of leaf extracts of some higher plants. *Acta Botanica Indica*. 1979;7(2):147-50.
8. Quazi MA, SayyedN, Shaikh S, Shaikh A, Patel MS. Pharmacognostic evaluation of *Kalanchoepinnata* roots. *International ResJournal of Pharmacy*. 2011;2(4):93-95.
9. Akpantah AO, Kebe EO, Edung ES, Mokutima AE. The effect of ethanolic extract of *Bryophyllum pinnatum* on the

- micro anatomy of the testes of adult males Wistar rats. *European Journal of Biology and Medical Science Research*. 2014 Jun;2(2):37-44.
10. Ojewole JA. P-2: Antihypertensive properties of *Bryophyllum pinnatum* (Lam) Oken leaf extracts. *American Journal of Hypertension*. 2002 Apr 1;15(S3):34A.
 11. Kirtikar KR, Basu BD. *Indian Medicinal Plants, periodical experts*. 2nd ed. Delhi; 1975.
 12. Pal S, Sen T, Chaudhuri AN. Neuropsychopharmacological profile of the methanolic fraction of *Bryophyllum pinnatum* leaf extract. *Journal of Pharmacy and pharmacology*. 1999 Mar;51(3):313-8.
 13. Ufelle SA, Ukaejiofo EO, Neboh EE, Achukwu PU, Ghasi S, Ikekpeazu EJ, Maduka IC. The Effect of Crude Methanolic Leaf Extract of "*Bryophyllum pinnatum*" on Some Haematological Parameters in Wistar Rats. *Asian Journal of Medical Sciences*. 2011 Jun 20;3(3):121-4.
 14. Ghasi S, Egwuibe C, Achukwu PU, Onyeanusu JC. Assessment of the medical benefit in the folkloric use of *Bryophyllum Pinnatum* leaf among the Igbos of Nigeria for the treatment of hypertension. *African journal of pharmacy and pharmacology*. 2009 Jan 31;5(1):83-92.
 15. Da Silva SA, Costa SS, Mendonça SC, Silva EM, Moraes VL, Rossi-Bergmann B. Therapeutic effect of oral *Kalanchoe pinnata* leaf extract in murine leishmaniasis. *Acta Tropica*. 1995 Dec 1;60(3):201-10.
 16. Harvey AL. Natural products in drug discovery. *Drug discovery today*. 2008 Oct 1;13(19-20):894-901.
 17. Bhattacharya A, Naik MR, Agrawal D, Sahu PK, Kumar S, Mishra SS. CNS Depressant and muscle relaxant effect of ethanolic leaf extract of *Moringa oleifera* on albino rats. *Int J PharmTech Res*. 2014;6:1441-9.
 18. National Research Council. *Guide for the care and use of laboratory animals*. National Academies Press; 2010 Dec 27.
 19. Hawk PB, Ostor BL. *Hawk's Physiological Chemistry*. 14th ed. New York: McGrawHill; 1995.
 20. Stermer E. Alcohol consumption and the gastrointestinal tract. *IMAJ-RAMAT GAN*-. 2002 Mar 1;4(3):200-2.
 21. Alkofahi A, Atta AH. Pharmacological screening of the anti-ulcerogenic effects of some Jordanian medicinal plants in rats. *Journal of Ethnopharmacology*. 1999 Nov 30;67(3):341-5.
 22. Arafa HM, Sayed-Ahmed MM. Protective role of carnitine esters against alcohol-induced gastric lesions in rats. *Pharmacological Research*. 2003 Sep 1;48(3):285-90.
 23. Drury RA, Wallington EA. Preparation and fixation of

- tissues. Carleton's histological technique. 1980;5:41-54.
24. Mizui T, Sato H, Hirose F, Doteuchi M. Effect of antiperoxidative drugs on gastric damage induced by ethanol in rats. *Life sciences*. 1987 Aug 10;41(6):755-63.
 25. Knoll MR, Kölbel CB, Teyssen S, Singer MV. Action of pure ethanol and some alcoholic beverages on the gastric mucosa in healthy humans: a descriptive endoscopic study. *Endoscopy*. 1998 Mar;30(03):293-301.
 26. Pal S, Nag Chaudhuri AK. Preliminary studies on the anti-inflammatory and analgesic activities of bryophyllum pinnatum (Lam.). *Med Sci Res*. 1989;17:561-2.
 27. Abdel-Salam OM, Czimmer J, Debreceni A, Szolcsányi J, Mózsik G. Gastric mucosal integrity: gastric mucosal blood flow and microcirculation. An overview. *Journal of Physiology-Paris*. 2001 Jan 1;95(1-6):105-27.
 28. Zatorski H. Pathophysiology and Risk Factors in Peptic Ulcer Disease. In *Introduction to Gastrointestinal Diseases Vol. 2* 2017 (pp. 7-20). Springer, Cham.
 29. Hollander D, Tarnawski A, Krause WJ, Gergely H. Protective effect of sucralfate against alcohol-induced gastric mucosal injury in the rat: macroscopic, histologic, ultrastructural, and functional time sequence analysis. *Gastroenterology*. 1985 Jan 1;88(1):366-74.
 30. Sharma AL, Bhot MA, Chandra N. Gastroprotective effect of aqueous extract and mucilage from *Bryophyllum pinnatum* (Lam.) Kurz. *Ancient science of life*. 2014 Apr;33(4):252.
 31. Khazaei M, Salehi H. Protective effect of *Falcaria vulgaris* extract on ethanol induced gastric ulcer in rat. *Iranian Journal of Pharmacology and Therapeutics*. 2006 Sep 15;5(1):43-0.
 32. Wong CJ. Involuntary weight loss. *Medical Clinics*. 2014 May 1;98(3):625-43.