

HISTOPATHOLOGICAL EFFECTS OF ORAL AND SUBCUTANEOUS ADMINISTRATION OF ROSELLE CALYX (RC) EXTRACT ON THE LIVER AND KIDNEY OF ALBINO RATS: A COMPARATIVE STUDY

ODIGIE BE^{1,2}, ERAMEH OT²

ABSTRACT

Roselle (*Hibiscus sabdariffa* L., family Malvaceae) is consumed in Nigeria as a refreshing drink and for therapeutic purposes. This study was to examine the histopathological effects of *H. sabdariffa* calyx extract on the liver and kidney of albino rats. The second goal was to compare the effects exerted on the target organs via routes of administration (oral against subcutaneous) in rats. Sixty albino rats of both sexes and an average weight of 204.14 ± 2.1 g (Mean \pm SEM) were assigned by sex, age and weight to a control group (VA and VB) and test groups (IA to IVA and IB to IVB). They were administered with varying concentrations (50 to 200mg/kg) for 40 days at 2 days intervals. On day 41, all rats were sacrificed by anaesthetization. The liver and kidney were excised, grossed and fixed in Bouin's solution for 48hrs prior to histological processing. Sections were obtained at 3-5microns and stained with Mayer's haematoxylin and eosin for light microscopy. No comparable changes were observed grossly and histologically. However, effects on body weight of experimental animals showed significant reduction in Group IB to IVB respectively. In comparison, with the oral administration, empirical measurement showed negligible weight loss in the high dose treated animals (Group IIIA and IVA). Histopathology of the liver and kidney in this study showed no comparable effects exerted via the routes of administration in albino rats by RC extract. This study suggests that oral administration remains the choice for consumption of RC (as pleasure drink or for therapeutic use).

INTRODUCTION

Since ancient times, plants have been employed in the treatment of a number of diseases. Several experimental studies and to a lesser extent, clinical trials have also emphasized the roles of plants in the treatment of a variety of disorders¹. Some archeological evidence shows that some

plants like (*Hibiscus sabdariffa* L.), has been employed in the past to function as a cytoprotective agent and as a natural source of antioxidant². Attention was shifted away from plant medicine with the evolution of synthetic drugs and modern medicine³. However, due to the high cost and side effects of prescription medications, there is a renewed interest in natural remedies⁴. Recently, much attention has been focused on the protective impact of antioxidants and naturally occurring substances against oxidative stress damage⁵.

In line with the above, Roselle Calyx (RC) is a nature's generosity which provides mankind with

KEYWORDS: Roselle, Calyx, Decoction, Concoction, Histology, Liver, and Kidney

¹Department of Medical Laboratory Sciences, School of Basic Medical Sciences, College of Medical Sciences, University of Benin, Benin City, Nigeria.

²Department of Medical Laboratory Sciences, Faculty of Health Sciences and Technology, College of Medicine, University of Nigeria, Enugu, Nigeria.

* Correspondence

ODIGIE BE

Department of Medical Laboratory Sciences, School of Basic Medical Sciences, College of Medical Sciences, University of Benin, P.M.B. 1154, Benin City, 30001, Edo State, Nigeria.
Email: bolaji.odigie@uniben.edu, Tel: 07036858986/08023345132

cheap and natural bioactive materials⁵. Thus, the exploitation of this natural gift is necessary to overcome the unwanted side effects of some essentially used medications⁵. RC (*Hibiscus sabdariffa* L., family Malvaceae) is an annual shrub commonly used to make jellies, jams, and beverages⁵. *H. sabdariffa* grows in all parts of the world, and it is taken as an ordinary local drink popularly known as "Zobo" in Nigeria. It is a medicinal herb, used in folk medicine in the treatment of hypertension^{6, 7}. In folk medicine, RC has commonly been known for its antihypertension properties⁸. *H. sabdariffa* has been reported to be an antioxidant², antiseptic⁹, aphrodisiac⁹, astringent⁹, cholagogue⁹, demulcent⁹, digestive⁹, diuretic⁹, emollient⁹, purgative⁹, refrigerant⁹, sedative⁹, stomachic⁹, and tonic⁹. Botanically, it is described as a thick red fleshy, and a cup-shaped RC plant⁵. The calyxes are rich in phenolic compounds with marked physiological activities⁵. Details of the bio-functions, biochemical properties and general health benefit of the RC plant have been documented in literatures¹⁰ with the most recent being its anthocyanin protective properties^{2, 5}.

There may be little or no documentation on the long term effects of herbal preparations in Nigeria, as well as lack of standard measurement on the dose regimen in circulation which usually comes in large volumes that are difficult to immediately quantify before consumption. In spite of the numerous works, on the effects of *H. sabdariffa* in man and animals, there remains dearth of literature supporting the effects of the calyx extract, decoction, and or concoction on the histology of the liver and kidney of albino rats from this part (Benin City) of Nigeria. In light of this, the present study was designed to examine the effects of *H. sabdariffa* calyx extract in animal models and a secondary goal was to compare the effects exerted on the liver and kidney via routes of administration (oral versus

subcutaneous) in albino rats at varying concentrations.

MATERIALS AND METHODS:

Location and Duration of Study

This study was conducted at the Department of Medical Laboratory Science, School of Basic Medical Sciences, College of Medical Sciences, University of Benin, Benin City, Nigeria. Animal acclimatization, extract preparation and administration, Grossing, Tissue processing, Sectioning, Staining, Microscopy, and Photomicrography lasted for three months (August, September and October, 2014).

Plant Material and Extraction

The samples of *H. sabdariffa* calyxes were obtained at New Benin market, Oredo Local Government in Edo state of Nigeria in the month of September, 2014. The Calyx was authenticated in Department of Pharmacognosy, Faculty of Pharmacy, University of Benin, Nigeria where a voucher specimen already existed. Extraction was conducted using the maceration method in the same Department. One hundred (100) gram of the powdered calyx was soaked in 2L of distilled water, and the mixture was agitated for twelve hours with a mechanical shaker (GFL No 3017 MBH, Germany). The mixture was filtered through a plug of cotton wool, and the process was repeated for a complete extraction. The extract filtrate was concentrated over the water bath at the temperature of 40°C-45°C and an amber solid extract weighing 10.6g was obtained. The extraction procedure in this study was a modified version of Okasha et al.,¹¹.

Experimental Animal

Sixty (60) inbred albino rats of both sexes, between 2 to 3months old and an average weight of 204.14± 2.1g (Mean± SEM) were obtained from the animal house of

the Faculty of Pharmacy, University of Benin, Nigeria. The animals were selectively assigned according to sex, age and weight to 5 groups of 6 rats per group and were housed in a stainless steel metal cage with sawdust as beddings to acclimatize in the animal care unit for 2 weeks under standard condition of temperature ($25 \pm 5^{\circ}\text{C}$) and 12hr dark/light cycle. They were fed with commercial feeds and tap water ad libitum. The animal study was used in accordance with National Institute of Health (NIH) Guide for the care and use of laboratory Animals¹². (Note: the rats were obtained by a predetermined weight, sex and age from the animal housekeeper).

Experimental Design

Each rat in group IA, IIA, IIIA and IVA (n=6) were picked one at a time with a hand towel and a dose of 50, 100, 150 and 200mg/kg body weight (b.w.) respectively were administered orally using a 5ml syringe while group IB, IIB, IIIB and IVB (n=6) were treated subcutaneously with the same dose as the former. Nonetheless, group V (A and B) served as the control. Each animal was weighed before and after administering the test extract. The experiment lasted for 40 days, oral and subcutaneous treatment were given at an interval of 2days while on day 41; all animals were sacrificed by using cotton wool soaked in chloroform vapor (anaesthetization). The kidney and liver of the animals (treated and untreated groups) were excised and examined grossly. After

that, it was processed histologically by the automatic tissue processor (Hestion - ATP7000 tissue processor-Germany).

Histological preparation for light microscopy

Four Pieces of liver and kidney tissues from each group were fixed in Bouin's solution for 48hrs following grossing at 3-5mm in diameter. Subsequently, they were dehydrated in graded concentration of ethanol (ascending grades), cleared in xylene, and embedded in paraffin wax for sectioning. After that, sections of about 3-5 μm in thickness were obtained using the Hertz rotary microtome (Leica RM2255, Cambridge mode) and mounted on glass slides. Staining of the section was according to haematoxylin and eosin technique and was examined using Swift^(R) binocular microscope with an inbuilt lighting system (Olympus, England). All histopathology changes observed in liver and kidney sections were confirmed by a pathologist.

Photomicrography and Statistical Analysis Olympus photomicroscope (Opticshot- 2; Nikon, Tokyo, Japan) was used at X40 magnification. Data were presented as Means \pm SEM and significance were determined at $p < 0.05$ using one-way analysis of variance (ANOVA) and differences between pairs of means within the five groups of rats (treated and untreated) were made by using the Student's Newman- Keuls test.

Table 1: Comparative and Experimental design for oral and subcutaneous administration of RC extract in 60 albino rats

Group	Number of rats	Average Weight	Dosage mg/kg Body Weight	Route of Administration	No of Days
IA	6	190.42	50	Oral	40 Days
IIA	6	199.80	100	Oral	40 Days
IIIA	6	208.18	150	Oral	40 Days
IVA	6	219.24	200	Oral	40 Days
VA	6	182.42	-	Oral	40 Days
IB	6	202.16	50	Subcutaneous	40 Days
IIB	6	209.10	100	Subcutaneous	40 Days
IIIB	6	218.40	150	Subcutaneous	40 Days
IVB	6	226.14	200	Subcutaneous	40 Days
VB	6	186.16	-	Subcutaneous	40 Days

Average weight of rats =204.14g

Note: Physiological status of the animals was not considered in this study. However, the study was able to maintain a steady physiological attribute of the animals from day 1 to 40 by assigning the animals selectively via the weight, age, and sex (males separated from the females).

RESULTS:

No significant difference was observed in organ weight when compared to the untreated groups both in oral and subcutaneous administration (Table 3). Upon grossing, the liver and kidney organs (oral and subcutaneous) showed no difference in their anatomical features in terms of the sizes, colours and consistencies. Comparison between the effects on target organs via routes of administration revealed that there were

relatively no comparable effects observed in the liver and kidney sections of animals treated orally and subcutaneously (Figure 1). Greater comparative effects exerted upon by the subcutaneous and oral treatment of albino rats were recorded in this study. It ranges from a significant reduction in body weight marked severely in all treated animals in (Group IB to IVB), to negligible weight loss in the high dose treated animals (Group IIIA and IVA).

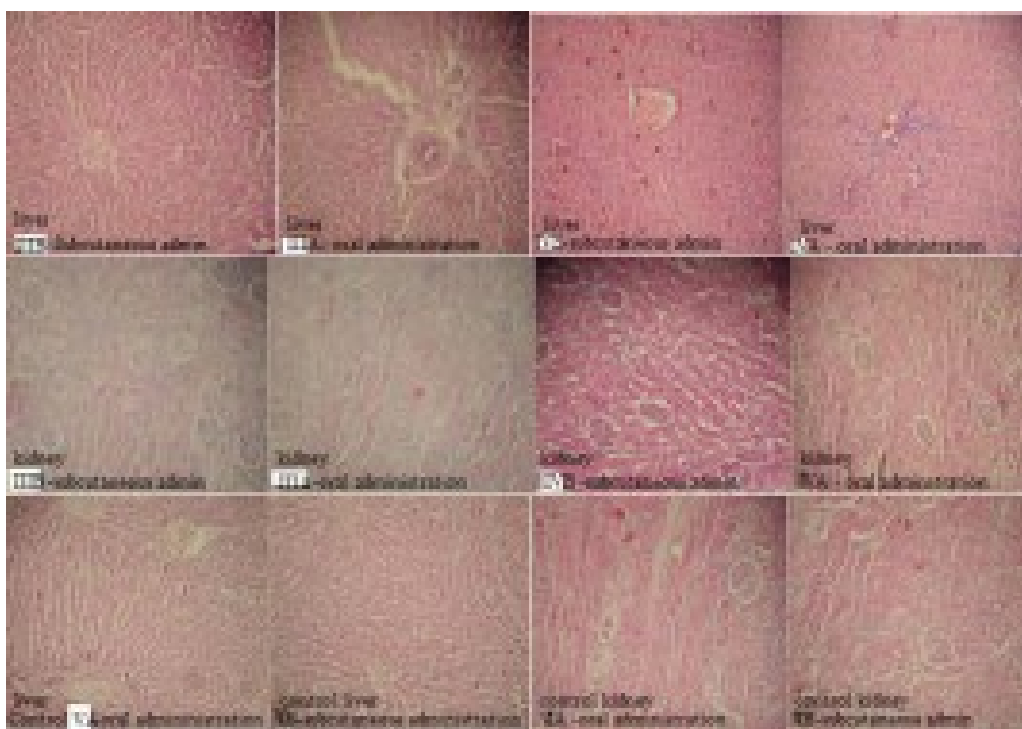


Figure 1: showed liver and kidney sections from untreated group (VA-oral, VB-subcutaneous) and high dose treated rats (IIIA-150mg/kg oral, IIIB-150mg/kg subcutaneous, IVA-200mg/kg oral, and IVB- 200mg/kg subcutaneous administration) all with regular cytoarchitectural appearance. Stain uptake: Mayer’s haematoxylin and eosin, X40magnification.

Table 2: Toxicity analysis of albino rats treated with RC extract for 40 days by oral and subcutaneous administration.

Group	Dose in mg/kg	Average weight before extract administration	Average weight after extract administration of decoction	Physical Weight loss / or gain	Activities / or dullness
IA	50	190.42± 1.4	196.32± 1.1	?	±
IIA	100	199.80± 1.8	208.56 ± 4.7	?	+
IIIA	150	208.18± 2.3	199.23 ± 3.4	?	++
IVA	200	219.24± 3.0	211.10 ± 3.8	?	++
VA	000	182.42± 1.4	202.66 ± 1.5	±	-
IB	50	202.16± 1.2	184.12± 1.4	±	+
IIIB	100	209.10± 1.1	183.24 ± 2.1	±	++
IIIB	150	218.40± 2.2	190.12 ± 4.2	±	++
IVB	200	226.14± 1.2	176.24 ± 1.6	±	++
VB	000	186.16± 1.4	208.66 ± 2.6	±	-

Table 3: Effects of RC extracts on organ weight at varying concentrations in albino rats

Organ	Control	Test IIIA	Test IVA	Test IIIB	Test IVB
Weight	grams	grams	grams	grams	grams
Liver (Oral)	2.80 ± 0.10	2.82 ± 0.24	2.20± 0.22	2.66 ± 0.26	2.62 ± 0.66
Liver (Sub)	2.60 ± 0.18	2.60 ± 0.11	2.48± 0.24	2.68 ± 0.21	2.62 ± 0.26
Kidney (L-O)	1.22 ± 0.32	1.02 ± 0.42	1.18± 0.12	1.22 ± 0.04	1.06 ± 0.16
Kidney (R-O)	0.98 ± 0.14	0.96 ± 0.24	0.98± 0.40	0.96 ± 0.44	0.96 ± 1.41
Kidney (L-S)	1.06 ± 0.12	1.00 ± 0.21	1.02± 0.22	1.12 ± 0.26	1.04 ± 1.14
Kidney (R-S)	0.94 ± 0.12	0.98± 0.18	0.96± 0.22	0.96 ± 0.66	0.98 ± 0.61

DISCUSSION:

The kidney, in addition to urine formation, helps in the maintenance of the internal environment, homeostasis, and haemopoietic functions. Others include regulation of arterial blood pressure, regulation of blood calcium level and endocrine function¹³. On the other hand, the liver being the largest organ and one of the vital organs in the body has many functions. Omonkhua and Onoagbe¹⁴ enumerated the vast roles of the liver as follows: It performs many important metabolic and homeostatic functions. Drugs and other foreign substances are metabolized and inactivated in the liver and are, therefore, susceptible to the toxicity from these agents. Certain medicinal agents, when taken in overdoses and sometimes even when introduced within therapeutic ranges, may injure the liver¹⁴. More so, millions of people in various traditional systems, including Nigeria, have resorted to the use of medicinal plants to treat their ailments; this could be as a result of the high cost of orthodox health care, or lack of faith in it, or maybe as a consequence of

the global shift towards the use of natural, rather than synthetic products¹⁴.

Hala et al.⁵ reported that the glomerulus is a globular network of densely packed anastomosing capillaries while the numerous nuclei in the glomerulus were those of the capillary endothelial cells, mesangial cells and podocytes. The Bowman's capsule was formed of the parietal layer characterized by its flat nuclei of the squamous cells lining it while the visceral layer was formed of podocytes. The Bowman's space was the space between the parietal layer and the glomerular tuft. This study thus corroborated the findings earlier reported⁵ in that the kidneys of the control rats and Roselle calyx treated rats (oral and subcutaneous routes) showed that the normal renal corpuscle consisted of glomerulus and Bowman's capsule without deleterious effects compares. In this study, all examined kidneys (treated with RC extract) were similar to the control group. Abbas et al.¹⁵ revealed that RC is a safe herbal preparation to the kidney with significant anti-oxidative

stress effects. Abbas et al.¹⁵ further iterated that there wasn't significant harmful change in cholesterol, triglyceride, blood urea nitrogen (BUN), and serum creatinin as well as sodium and potassium levels estimated in experimental rats. Though, the reported observation was drawn from a biochemical point of view.

In light of the ongoing, the present study corroborates the reported claims in some literatures^{10, 16} that the calyx extract of *H. sabdariffa* has hepatoprotective functions going by the results obtained in the liver sections (oral and subcutaneous administrations). Conversely, routes of administration, concentration, dosage and duration of administration have an extended role in a comparative study. Recall that a very low concentration and dosage with a prolong duration of administration for 40 days were used in the present study. It was earlier reported that the chemistry of the dried calyx contains calories, water, protein, fat, carbohydrates, fiber, ash, and calcium, phosphorus, iron, and ascorbic acid¹⁰. Ascorbic acid has been known to be able to protect the liver from injurious bio-substances¹⁰. Moreover, ascorbic acid is a strong antioxidant which activates the functions of all the cells, protects and removes toxic substances from the body and intervenes in the regeneration of damaged tissues¹⁷. Hence, the vast functions of ascorbic acid, duration and routes of administration, concentration and dosage may have contributed in parts to the hepatoprotective effects of *H. sabdariffa* observed in this study.

The only apparent comparative effect between oral and subcutaneous administration of *H. sabdariffa* l. drawn from the present study appears to be in terms of weight loss (subcutaneous treatment) in experimental animals. Therefore, this study is in line in parts with

Orisakwe et al.¹⁸ by which weight gain was observed in the group (IA and IIA). Orisakwe et al.¹⁸ further suggested that weight gain in laboratory animals as a result of exposure to *H. sabdariffa* calyx extract may be due to retention of water and sodium and the expansion of the extracellular fluid caused by excessive intake of sodium chloride content in the calyx extract of the RC plant. In addition, this observation is in agreement with earlier report¹⁹ which showed that the RC plant extract was able to control weight gain in experimental animals.

Irrespective of the ongoing, the administration of the extract resulted in appreciable weight loss in the group (IIIA and IVA) and a more severe weight loss in groups (IB, IIB, IIIB, and IVB). The reasons for the severe weight loss in rats treated subcutaneously may be attributed to the mode of administration (subcutaneous). Though, the present study observed that animals treated subcutaneously had reduced activities as well as some degree of anorexia (withdrawal from feeds). Subcutaneous administration in this study may have inflicted some degree of pains on the test animals which in turn may be responsible for the decrease in feeding habit by the animals and ultimately led to the resultant weight loss or emaciation marked in groups (IB, IIB, IIIB and IVB) respectively. Anorexia was observed to be an important factor in this study. It became apparent from the mid duration of extract therapy (Day 20 onward) which led to starvation. It is important to note that during starvation, glucose reserve is empty mostly in a longer period of starvation; glucose must, therefore, be formed from a non-carbohydrate source such as glycerol and amino acid for survival²⁰. Starvation in turn led to severe loss of weight observed

in the group of rats treated subcutaneously.

CONCLUSION:

This study revealed that there are no histo-comparable effects in the mode of administration of the test substance in animal models. Notwithstanding, comparative effects on body weight of experimental animals (oral against subcutaneous route) were observed. Therefore, our study suggests that oral administration remains the choice for consumption of *H. sabdariffa* calyx extract (as pleasure drink or for therapeutic use) as it appears to exert no histopathological effects on the histology of the liver and kidney of albino rats.

REFERENCES

1. Yahaya I, Okpuzor J, Oladele EO. The Bio Protective Efficacy of Hibiscus sabdariffa (Roselle), Moringa oleifera (Moringa) Zingiber officinale (Ginger) and Telfairia occidentalis ('Ugwu') in the Livers and Kidneys of Rattus norvegicus (Albino rats) Exposed to Cement dust. IOSR, JESTFT 2013; 7(1): 24-30.
2. Rossi A, Serraino I, Dugo P. Protective effects of anthocyanins from blackberry in the rat model of acute lung inflammation. Free Radical Res 2003; 37(8): 891-900.
3. Wu CG, Chamuleau RA, Bosch KS. Potential Effects of Silymarin on Rat Liver injury induced by Ischemia. Virchow Archives B 1996; 64(5): 259-263.
4. Steven DE. Herbal Medicine Overview. 2011; University of Maryland Medical Center, 22S. Greene Street, Baltimore. www.umm.edu/altmed/articles/herbal-medicine-000351.htm [Accessed on 24/03/2013].
5. Hala HM, Olfat AAA, Enas AM, Sahar MSY, et al. Biochemical and Ultra Structure Studies of the Antioxidant Effect of Aqueous Extract of Hibiscus Sabdariffa on the Nephrotoxicity Induced by Organophosphorous Pesticide (Malathion) on the Adult Albino Rats. J Am Sci 2011; 7(12):407-421.
6. Wang CJ, Wang JM, Lin WL, Chu CY, et al. Protective effect of Hibiscus anthocyanins against tert-butyl hydroperoxide-induced hepatic toxicity in rats. Food Chem. Toxicol 2000; 38(5): 411-416.
7. Odigie IP, Ettarh RR, Adigun SA. Chronic administration of aqueous Hibiscus sabdariffa attenuates hypertension and reverses cardiac hypertrophy in 2k-1c hypertensive rats. J. Ethnopharmacol 2003; 86(2-3): 181-185.
8. Herrera-Arellano A, Flores-Romero S, Chávez-Soto MA, Tortoriello J. Effectiveness and tolerability of a standardized extract from Hibiscus sabdariffa in patients with mild to moderate hypertension: a controlled and randomized clinical trial. Phytomedicine 2004; 11: 375-382.
9. Morton JF. Roselle. In: Fruits of warm climate. Dowling, C. F. (Ed). Media Inc. Greensboro, NCP 1998; 281-286.
10. Emelike CU, Obike CJ, Nwandikor UU, Ifediora AC, et al. Physicochemical constituents, phytochemical and morphological effects of oral administration of aqueous extract of Hibiscus sabdariffa on kidney and liver of Wistar albino rats. Am J Res Comm 2014; 2(7): 101-112.
11. Okasha MAM, Abubakar MS, Bako IG. Study of the Effect of Aqueous Hibiscus Sabdariffa Linn Seed Extract on Serum Prolactin Level of Lactating Female Albino Rats. Eur J Sci Res 2008; 22 (4):575-583
12. National Research Council, Guide for the Care and Use of Laboratory Animals, National Academic Press, Washington DC, USA. 1996; pp: 65.
13. Sembulingam K, Sembulingam P. Essentials of Medical Physiology. 5th Edition, JAYPEE Brothers Medical Publishers (P), Ltd. New Delhi, India. 2010; pp: 680.
14. Omonkhua AA, Onoagbe IO. Effects of Irvingia grandifolia, Urena lobata and

- Carica papaya on the Oxidative Status of Normal Rabbits. *Internet J. Nutr. Wellness* 2008; 6(2): 193-197
15. Abbas M, Shirin M, Patricia K, Mohammad GK. The Effect of Hibiscus Sabdariffa on Lipid Profil Creatinine and Serum Electrolytes: A Randomized Clinical Trial. *Gastroenterology* 2011; 20(11):24-39
 16. Amin A, Hamza AA. Hepatoprotective effects of Hibiscus, Rosmarinus and Salvia on azathioprine-induced toxicity in rats. *Life Sci* 2005; 77: 266–278.
 17. Poornima GN, Ravishankar RV. Evaluation of phytonutrients and vitamin contents in a wild yam, *Dioscorea belophylla* (P.). *Afri. J Biotech* 2009; 8(6): 971-973.
 18. Orisakwe OE, Hussaini DC, Orish VN, Obi E. et al. Nephrotoxic effects of Hibiscus Sabdariffa calyx in Rats. *Eur. Bull. Drug Res* 2003; 11: 99-103.
 19. Repetto MG, Lesuy SF. Antioxidant properties of natural compounds used in popular medicine for gastric ulcers. *Braz. J. Med. Biol. Res* 2002; 35: 523-534.
 20. Stryer L. *Biochemistry*. 4th Edition, Freeman WH and Co. NY. 1995; pp: 569.