

ASSESSMENT OF THE EFFECTS OF PARENTERAL QUININE ON TESTICULAR HISTOLOGY AND SPERM PARAMETERS IN WISTAR RATS

¹J. E. ATAMAN, ²D. BAXTER-GRILLO, ³A.A.A. OSINUBI

ABSTRACT

Twenty-four week duration experiment was conducted with twenty-one male Wistar rats (200 - 250 g) to investigate the effects of quinine on the testis. The rats were divided into three groups- the control, saline and the quinine; each comprised of seven rats. The control group and others were fed on feed mash (Growers) and water ad libitum. The saline group had physiological saline intramuscularly. The quinine group had intramuscular 20 mg/kg body weight of quinine daily (5 days/week), for eight weeks. The effects of quinine treatment caused reduced total and motile sperm count, significantly different ($p < 0.05$) from control, but sperm motility was unaffected. The sections on quinine treatment showed seminiferous tubules with vacuolated lumens, disrupted seminiferous epithelium, arrested spermatogenesis, and moderate spermatozoa in epididymis. Quinine in this study caused morphological changes in the testis and significant reduction ($p < 0.05$) in epididymal total and motile sperm count, but no detectable effects on sperm motility.

INTRODUCTION

Quinine is a quinoline-methanol derivative obtained from the bark of Cinchona tree and found in Peru¹. It is widely used in the management of cerebral malaria and chloroquine-resistant malaria^{2,3}. It was discovered by two French scientists Joseph B. Caventou and Pierre-Joseph Pelletier in 1820. The production of spermatozoa in the testis is

largely influenced by hormonal factor. Gonadotropin-releasing hormone (GnRH) from the hypothalamus, which is released in pulsatile manner, stimulates luteinizing hormone (LH) and follicle stimulating hormone (FSH) release from the anterior pituitary⁴. They both bind to specific receptors in the Leydig cells and Sertoli cells within the testis. The Leydig cells of the testis produce testosterone, while the Sertoli cells are said to provide the nutritional and structural support of germ cells⁵. Testosterone can be converted to oestradiol during aromatization and this influences fertility. This occurs under the influence of the enzyme aromatase (CYP19 or cytochrome P450arom)⁶. This hormone essentially controls the physiologic balance between the sex steroid hormones^{7,8}. Quinine is a widely used drug in the tropics. This study aims to evaluate its effect on the testicular histology and sperm parameters and by inference, on male fertility.

RESEARCH DESIGN AND METHODOLOGY

KEYWORDS: Quinine, Testicular Histology, Sperm parameters, Wistar Rats

¹Dr. Jacob E. Ataman
Department of Anatomy, School of Basic Medical Sciences, College of Medical Sciences, University of Benin, Benin-City, Nigeria.
Phone: + 2348033874644, e-mail: atamanje@yahoo.com, ehiagwina.ataman@uniben.edu

²Prof. D. Baxter-Grillo
Department of Anatomy, School of Basic Medical Sciences, College of Medical Sciences, University of Benin, Benin-City, Nigeria.
Phone: + 2348022614233

³Dr. Abraham A. A. Osinubi
Department of Anatomy, College of Medicine of the University of Lagos, Nigeria.
Phone: + 2348062818337, E-Mail: aaosinubi@cmul

* Correspondence

Dr. Jacob E. Ataman
Department of Anatomy, School of Basic Medical Sciences, College of Medical Sciences, University of Benin, Benin-City, Nigeria.
Phone: + 2348033874644 e-mail: atamanje@yahoo.com, ehiagwina.ataman@uniben.edu

Drug Procurement and Administration

A pack of Quinine dihydrochloride, manufactured by Wuhan Grand Pharmaceutical group Co., Ltd., was purchased from Monic Tee Pharmacy opposite the University of Benin Teaching Hospital, Benin-City. An ampoule of 2 ml containing 600 mg/kg of quinine was diluted with 58 ml of physiological saline to obtain 10 mg/ml. Using an Insulin syringe, the drug was administered to the rats at 20 mg/kg body weight intramuscularly.

Animals and Intervention

Experimental procedures involving the animals and their care were conducted in conformity with International and Institutional guidelines for the care of laboratory animals in Biomedical Research, as promulgated by Canadian Council on Animal Care⁹. Further, the animal experimental models used were in conformity with the guiding principles for research involving animals as recommended by American Physiological Society¹⁰ and Saalu et al.,¹¹.

The animals were procured from a standard breeding stock and housed in well ventilated wire-gauged wooden cages in the Animal facility of the Department of Anatomy University of Benin, Benin City. An approval to conduct the research was sought and obtained from the Post Graduate Committee of the Department. The rats were maintained under standard natural photoperiodic condition of 12 hr of light alternating with 12 hr of darkness (i.e. L:D;12:12) with room temperature of between 25 to 26°C and humidity of 65±5%. They were given water ad libitum and unrestricted access to feeds (Growers mash) obtained from Bendel feeds and flour mill, Ewu, in Edo State, Nigeria. They were allowed to acclimatize for three weeks (21 days) before the commencement of the experiments. The experimental animals were categorized into the following treatment groups:

1. Control Group: Received Feed mash and water only ad libitum throughout the duration of experiment before sacrifice at the end of the twenty-fourth week.
2. Saline Group: This group served as negative control. They received the volume of physiological saline equivalent to the volume of it used as diluents to administer 20mg/kg quinine to the rats in the quinine group (Osinubi et al., 2004). Sacrifice was done at the end of the twenty-fourth week.
3. Quinine Group: This group was treated with intramuscular 20mg/kg body weight of quinine daily (5 days/week excluding Saturdays and Sundays so as to minimize risk of injection abscess). Treatment was for eight weeks (week 12-20) and sacrifice was done at the end of the twenty-fourth week.

Animal sacrifice and collection of sample:

The rats at the time of sacrifice were weighed and then anaesthetized by placing them in a closed jar containing cotton wool soaked with chloroform anaesthetic. The abdominal cavity was opened up through a midline abdominal incision to expose the reproductive organs. The testes were excised and trimmed of all fatty tissues before being weighed using an electronic analytical and precision balance (Mettler Pm 4800 Delta RangeR).

Sperm count and Motility

The estimation of the sperm count and the motility were achieved using the new improved Neubauer's counting chamber (Heamatocytometer). The epididymal fluid from both epididymides was diluted with physiological solution by adding 0.9 ml to 0.1

ml of the crushed epididymis. Smear of the sperm fluid was prepared with a pipette drop, sliding a cover slip in front of it in the counting chamber before being placed under a binocular light microscope. Using an adjustable light source, the ruled part was focused and the number of spermatozoa counted in five 16-celled squares. The total sperm cells were added and multiplied by 10^6 and expressed as $(X) \times 10^6/\text{ml}$, where X is the total number of sperm cells in the five 16-celled square^{12,13}. The degree of sperm progressivity was assessed following the modified procedure of Saalu et al.,¹¹.

Routine histological preparation

The histology of the testes was carried out following the modified method of Drury and Wallington¹⁴. The organs from the rats were harvested and fixed in 10% buffered formalin for 24 hours after which they were transferred to 70% alcohol for dehydration. The tissues were passed through 90% and absolute alcohol and xylene for different durations before they were infiltrated with molten paraffin wax for an hour in an oven at 50-65°C. This act was repeated for another 1 hour before embedding the tissues in an embedding mould. Thereafter, they were serially sectioned using rotary microtome at 5 microns. The tissues were picked up with albumenised slides and allowed to dry on hot plate for 2 min. The slides were dewaxed with xylene and passed through absolute alcohol (2 changes); 70% alcohol, 50% alcohol and then to water for 5 min. They were then stained with haematoxylin and eosin before being mounted in Distrene (a polystyrene), a plasticizer (tricresyl phosphate) and xylene (D. P. X). Photomicrographs were at magnifications of $\times 400$.

Data Analyses

Data are presented as Mean \pm SEM using Microsoft excel package. Means separation was by Duncan multiple range test^{15,16} and significant differences between the means were determined by student t-test ($p < 0.001$)^a, ($p < 0.005$)^b, ($p < 0.05$)^c.

RESULTS

Sperm Parameters

From the constant volume of the sperm (0.5ml) used, the pH value for the sperm samples collected was 6.0. The results of the total and motile sperm count in the Table revealed as follows: For the control group, mean total sperm count was $55.8 \pm 4.7 \times 10^6/\text{ml}$, mean motile sperm count was $50.2 \pm 4.3 \times 10^6/\text{ml}$ and % motile sperm was 80.2 ± 10.8 . For the saline group, total sperm count was $53.0 \pm 4.2 \times 10^6/\text{ml}$, motile sperm count was $46.3 \pm 3.7 \times 10^6/\text{ml}$, and % motile sperm was 87.7 ± 2.2 . For the quinine group, total sperm count was $32.5 \pm 4.5 \times 10^6/\text{ml}$, motile sperm count was $23.8 \pm 3.7 \times 10^6/\text{ml}$ and % motile sperm was 72.1 ± 3.7 . The degree of sperm progressivity was rapidly motile and forward in all the groups.

The control sections of the testes essentially showed the lumen of the seminiferous tubules with spermatogenic cell series in progression from the basement membrane towards the adluminal compartment. (Fig. 1). The testicular interstitium were essentially normal containing the interstitial cells (of Leydig). The sections of the epididymis contained matured spermatozoa stored in clusters in the lumen, and the epididymal lining comprised of tall columnal cells (Fig. 4). The testicular sections of the saline treatments were normal, with normal progression of the germ cell series and normal testicular interstitium (Fig. 2). The epididymis of saline treatment, just as the control section, had normal lumen

containing stored spermatozoa and the epididymal lining comprised of tall columnal cells with no abnormality seen (Fig. 5). The sections on quinine treatment contained seminiferous tubules with some of their lumen appearing vacuolated due to arrested

spermatogenesis occurring from disruption of the seminiferous epithelium (Fig. 3). The epididymis were moderately filled with spermatozoa, not in clusters as seen in the controls (Fig. 6).

Table: Effects of Quinine Treatment on the Sperm Parameters of Wistar Rats

Groups	Total Sperm	Motile Sperm	% Motile Sperm	Progressivity
	Count X10 ⁶ /ml	Count X10 ⁶ /ml		
Control	55.8±4.7	50.2±4.3	80.2±10.8	**
Saline	53.0±4.2	46.3±3.7	87.7±2.2	**
Quinine	32.5±4.5 ^c	23.8±3.7 ^c	72.1±3.7	**

* Means with alphabetic remarks are significantly different from control:

($p < 0.001$)^a, ($p < 0.005$)^b, ($p < 0.05$)^c. Vertical comparisons only.

Control: Received feed mash and water only

Saline: Received equivalent volume of normal saline

Quinine: Treated with 20 mg/kg quinine.

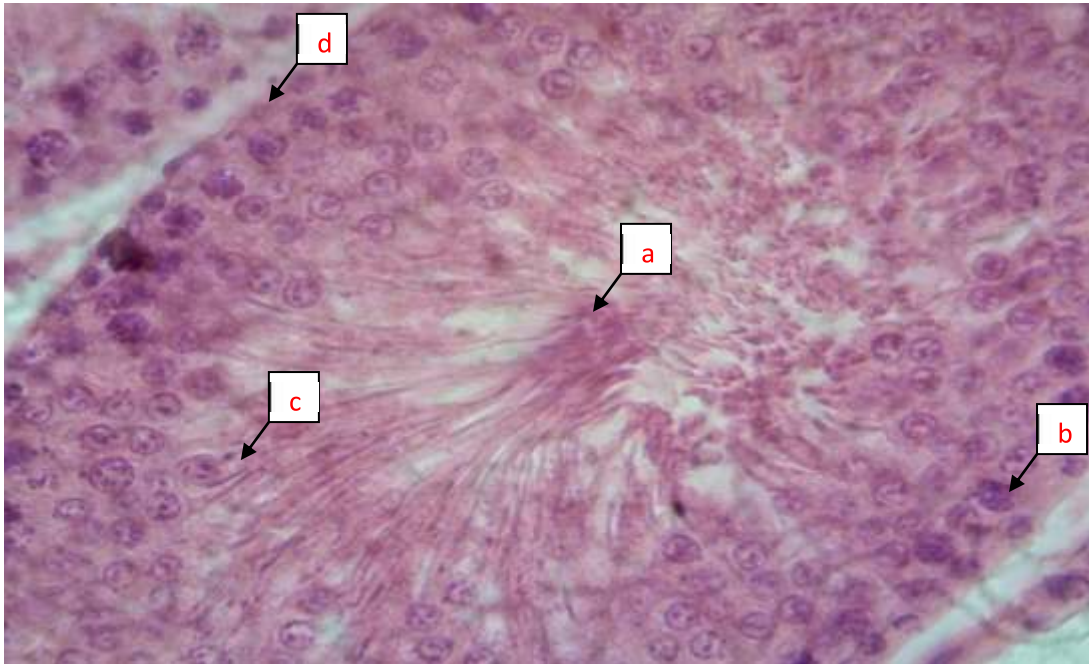


Fig. 1: Section of the control testis (a) normal seminiferous tubule with tails of spermatozoa abutting the lumen (b) early germ cells of the spermatogenic series (c) late germ cells of the spermatogenic series differentiating into spermatids (d) basement membrane [H&E x400]

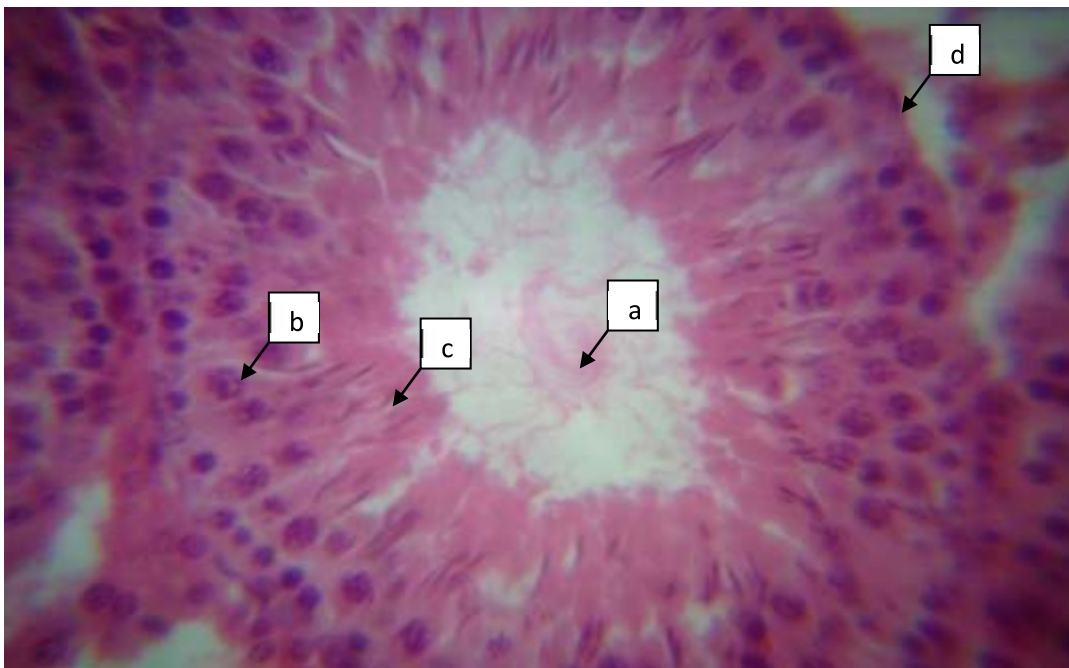


Fig. 2: Section of the saline testis (a) lumen of the seminiferous tubule containing spermatozoa (b) early germ cells of the spermatogenic series (c) late germ cells of the spermatogenic series (d) basement membrane [H&E x400]

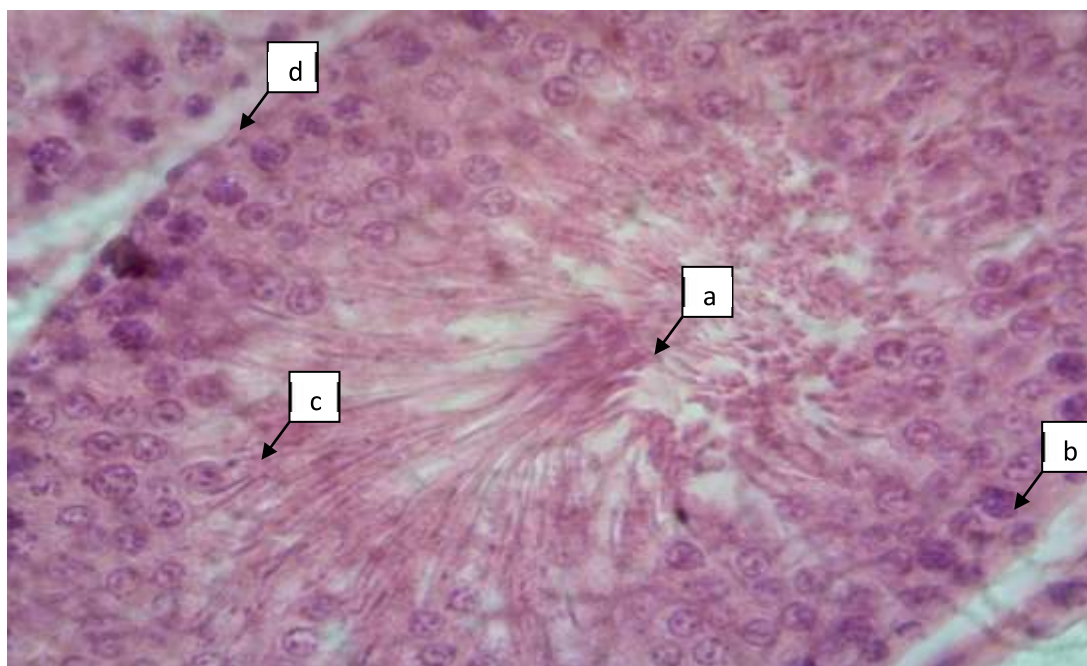


Fig. 1: Section of the control testis (a) normal seminiferous tubule with tails of spermatozoa abutting the lumen (b) early germ cells of the spermatogenic series (c) late germ cells of the spermatogenic series differentiating into spermatids (d) basement membrane [H&E x400]

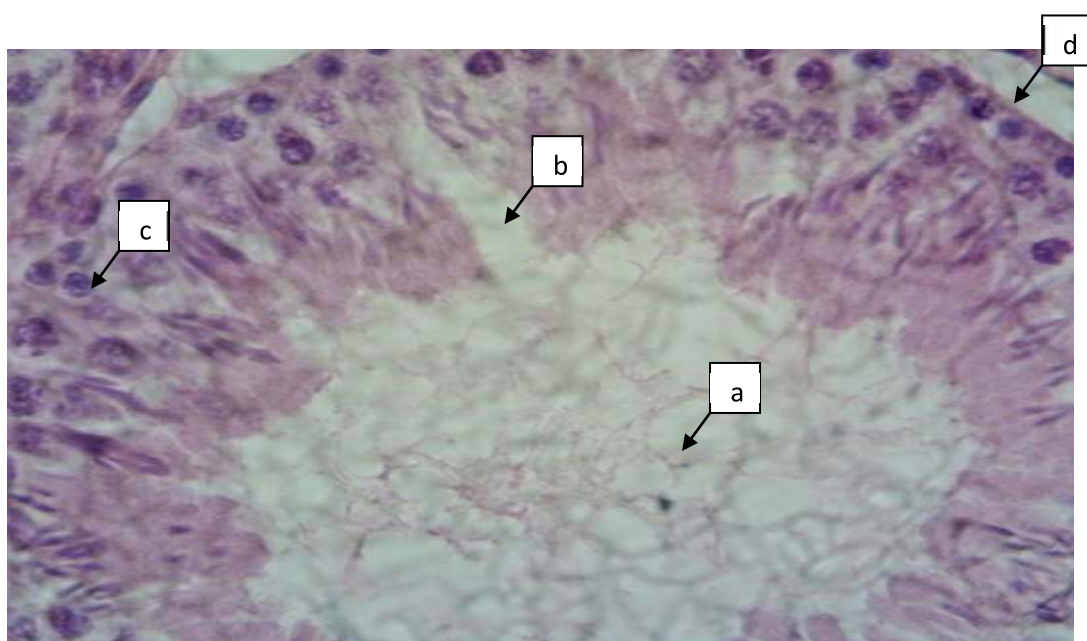


Fig. 3: Section of the Quinine testis (a) lumen of the seminiferous tubules depleted of spermatozoa due to necrotic changes (b) arrested differentiation of germ cells of the spermatogenic series and disruption of the seminiferous epithelium (c) early germ cells of the spermatogenic series (d) basement membrane [H&E x400]

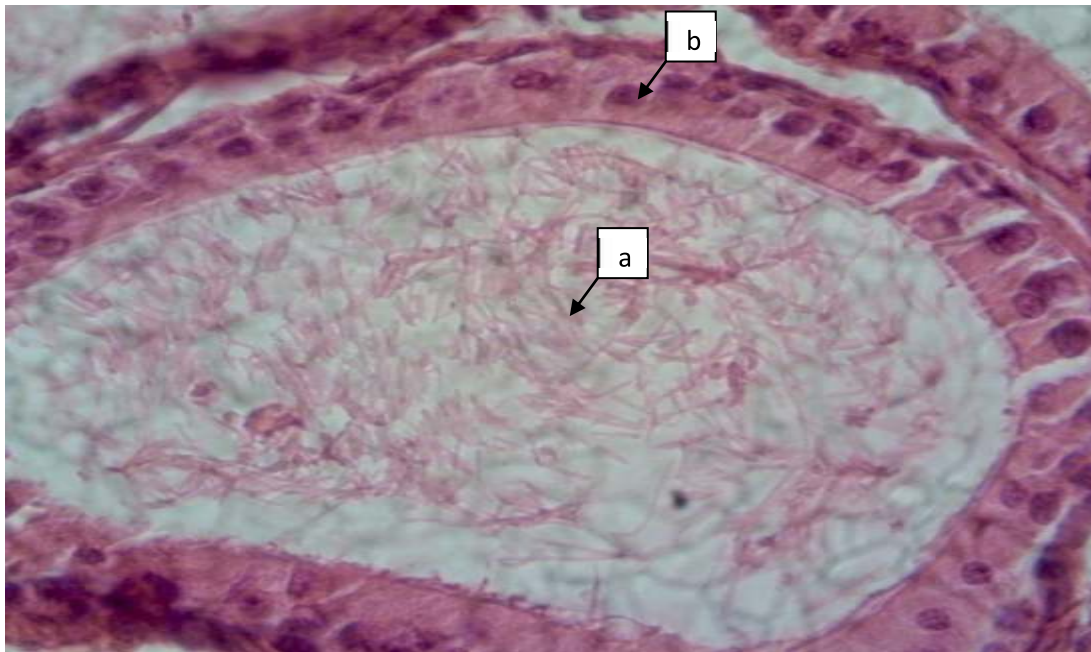


Fig. 4: Section of the control epididymis (a) clusters of spermatozoa in the lumen (b) normal epithelial lining of the epididymis [H&E x400]

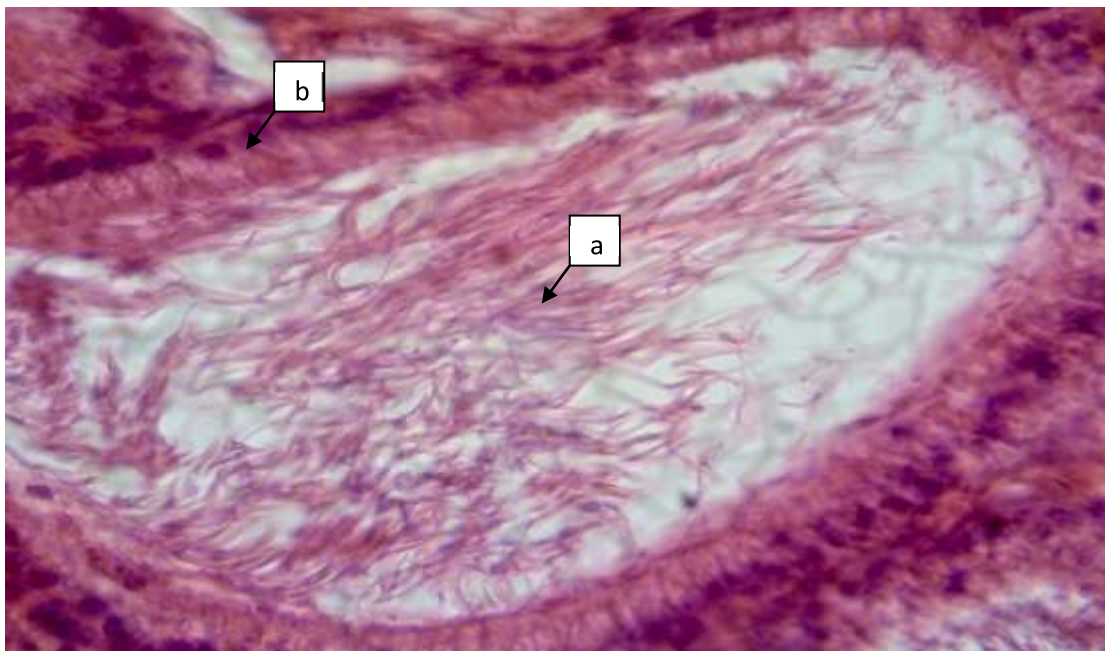


Fig. 5: Section of the saline epididymis (a) clusters of spermatozoa in the lumen (b) normal epithelial lining of the epididymis [H&E x400]

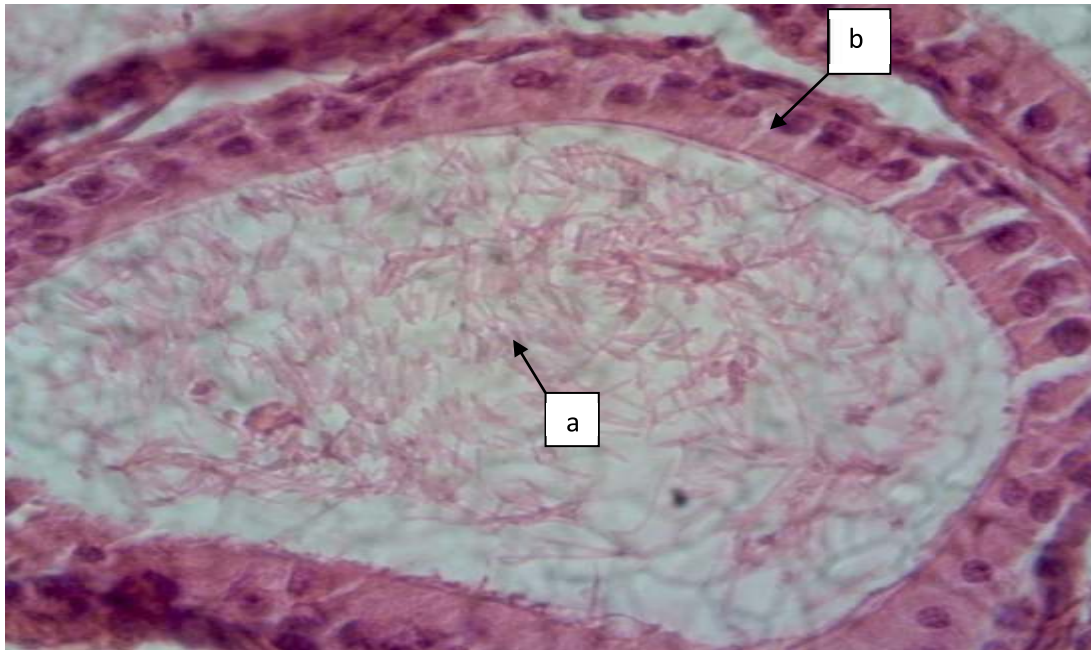


Fig. 4: Section of the control epididymis (a) clusters of spermatozoa in the lumen (b) normal epithelial lining of the epididymis [H&E x400]

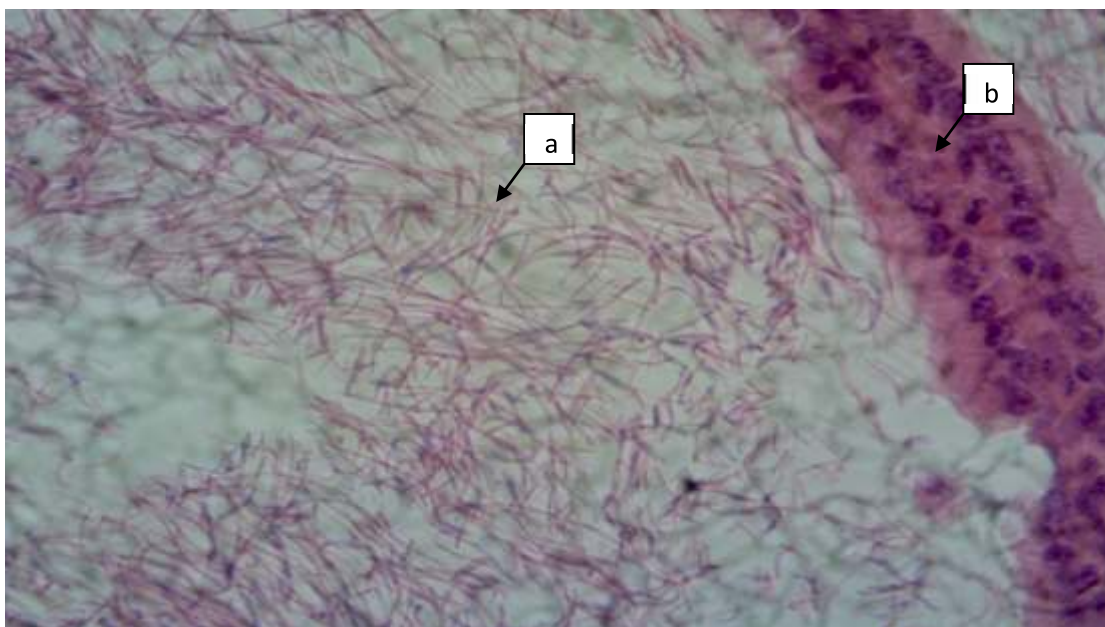


Fig. 6: Section of the quinine epididymis (a) clusters of spermatozoa in the lumen (b) normal epithelial lining of the epididymis [H&E x400]

DISCUSSION

The histology of the testis in the control group showed normal seminiferous tubules with tails of spermatozoa abutting the lumen suggestive of normal spermatogenesis in the seminiferous tubule. There was no remarkable difference in the histology of the testis in the saline group compared with the control. However, compared with the control, the seminiferous tubules of the group treated with quinine showed lumen depleted of spermatozoa due to necrotic changes in the tubule. This finding supports earlier studies that quinine which is efficacious in treating malaria causes inflammation of the testis¹⁷. Although there was no remarkable difference in the histology of the epididymis in the quinine and saline groups compared with the control, the results from this study demonstrated reduced total and motile sperm count in the quinine group, significantly different from control ($p < 0.05$). There was however no observable difference in sperm motility between the groups at the end of treatment as shown in the Table.

The findings of reduced total and motile sperm count by quinine from assessment of epididymal sperm parameters of the Wistar rats is supported by previous study¹⁸. Quinine-induced testicular damage may cause impairment of sperm motility, and can result in the generation of free radicals and/or a disturbance in the anti-oxidant status of the testis¹⁹. The non detectable difference in sperm motility between the quinine treatment and the control might be due to the possibility of reversal effect of quinine-induced testicular damage which had been noted in a related study²⁰. Borovskaya et al.,²⁰ observed morphological changes in the testes and suppressed spermatogenesis with a single injection of quinine to mice in a maximum tolerable dose. This finding is consistent with the report of this study where sections on quinine treatment were observed

to contain seminiferous tubules with most of their lumen depleted of spermatozoa due to arrested spermatogenesis. There was also disruption of the seminiferous epithelium by quinine as previously reported²¹. Gonocytes in all layers of the spermatogenic epithelium including interstitial endocrinocytes and sustentocytes are affected by quinine toxicity²⁰. This effect of quinine on the seminiferous epithelium of the testis disrupts the nutritional support, androgen binding protein and blood-testis barrier of the testis^{18,19}. These being part of the functions of the interstitial cells (of Sertoli) in the testis, might partly explain the observed cyto-toxic effects of quinine in this study, which could compromise fertility in the male rats. Conclusively, this study supports the fact that prolonged or long-term use of quinine has deleterious effects on the normal histology of the testis, affecting the sperm parameters. The recommendation from these observed effects of quinine toxicity in the testis is to use the drug with caution or follow-up its use with monitoring of testicular functions in males whenever prolonged use of the drug is required.

REFERENCES

1. Greenwood, D. The Quinine connection. *J. antimicrobial chemo* 1992; 30: 417 – 427.
2. Wilairatana, P., Krudsood, S., Treeprasertsuk, S., Chalermrut, K and Looareesuwan, S. (2002). The Future Outlook of Antimalarial Drugs and Recent Work on the Treatment of Malaria. *Arch. Med. Res* 2002; 33: 416 – 428.
3. Osinubi, A. A., Ajala, M. O., Noronha, C. C and Okanlawon, A. O. Quinine lowers Serum and Testicular Testosterone in Adult Sprague-Dawley Rats. *Afr. J. Med. Sci* 2006; 35: 425 – 443.
4. Ganong, W. F. *Review of Medical Physiology: The Gonads: Development & Function of the Reproductive System*. 20th ed. USA: McGraw- Hills com. 2001; 398 – 438.

5. Richburg, J. H and Boekelheide, K. Mono-(2-ethylhexyl) Phthalate Rapidly Alters both Sertoli Cell Vimentin Filaments and Germ Cells Apoptosis in Young Rat Testes. *Toxicol Appl Pharmacol* 1996; 137: 42 – 50.
6. Payne, A. H and Hales, D. B. Overview of Steroidogenic Enzymes in the Pathway from Cholesterol to Active Steroid Hormones. *Endocrine overviews* 2004; 25 (6): 947 – 970.
7. Conley, A. and Hinshelwood, M. Mammalian Aromatases. *Reprod* 2001; 121: 685 – 695.
8. Katsuji, A., Motoyuki, I., Seiji, M., Subrina, J., Takeshi, O., Chishimba, N. M., Takashi, M and Noboru, M. Expression of Steroidogenic Enzymes and Synthesis of Sex Steroid Hormones from DHEA in Skeletal Muscle of Rats. *American J. Physio., Endocrinol., Metab* 2007; 292 (2): E577 – E584.
9. Canadian Council of Animal Care. Guide to the Handling and Use of Experimental Animals. Ottawa, USA: NH Publications 1985; vol. 23: 45 – 47.
10. American Physiological Society. Guiding Principles for Research Involving Animals and Human Beings. *Am. J. Physiol. Regul. Integr. Comp. Physiol* 2002; 283: R281 – R283.
11. Saalu, L. C., Osinubi, A. A., Oguntola, J. A., Adeneye, I. O and Benebo, A. S. The Delayed Testicular Morphologic Effects of Doxorubicin and the Rejuvenating Role of Grape Fruit Seed Extract. *Int. J. Pharmacol* 2009; 6: 192 – 199.
12. Blom, E. A One- Minute Live- Dead Sperm Stain by Means of Eosin- Nigrosin. *Fertil. Steril* 1950; 1: 176 – 177.
13. Mortimer, D. *Practical Laboratory Andrology*. New York, USA: Oxford University Press 1994; 66 – 69.
14. Drury, R. A. B., Wallington, E. A. *Light Microscope and Slide Preparation*. Carleton's Histological Technique, 5th ed., Oxford University Press, London 1980; 1– 4.
15. Duncan, D. B. Multiple Range Test for Correlated and Heteroscedastic Means. *Biometrics*, 1957; 13: 164 – 176.
16. Snedecor, G. W., Cochran, W. G. *Statistical Methods*. 7th edn. Iowa: Iowa State University Press 1980; 215.
17. Abolghasemi, E., Moosa-Kazemi, S.H., Davoudi, M., Reisi, A and Satvat, M.T. Comparative Study of Chloroquine and Quinine in Malaria Rodents and their Effects on Mouse Testis. *Asian Pac J Trop Biomed*, 2012; 2(4): 311–314.
18. Osinubi, A. A., Adeyemi, A., Banmeke, A. and Ajayi, G. O. The Relationship between Testosterone Concentration and Sperm Count and Motility in Fertile and Infertile Nigerian Males. *Afr. J. Endocrinol. Metab* 2003; 4 (1): 43–45.
19. Osinubi A. A., Akinlua, J. T., Agbaje, M. A., Noronha, C. C and Okanlawon, A. O. Effect of Short-term Administration of Quinine on Seminiferous Tubules of Sprague-Dawley Rats. *Nig J Health Biomed Sc* 2004; 3 (1): 1 – 7.
20. Borovskaya, T. G., Gol'dberg, E. D., Abramova, E.V., Fomina, T. I and Tcachenko, S. B. Effect of Quinine on the morphology of mouse testis. *Bulletin of experimental biology and medicine* 2000; 130 (4): 994–996.
21. Ataman, J. E., Osinubi, A. A. Acute toxicity and effects of ethanolic leaf extract of *Newbouldia laevis* (P. Beauv.) on quinine-induced testicular damage in Wistar rats. *Nig J Biomed Eng* 2013; 11 (1): 20–26.