

FOREIGN BODY IN THE NASOPHARYNX MIMICKING AN OBSTRUCTIVE ADENOID

AUTHORS NAMES

DR. FASUNLA AYOTUNDE JAMES*
DR. OLOMO SURAJUDEEN**
DR. OSUKOYA AJIBOLA**
DR. AKENROYE MANUWA IDOWU***

AFFILIATIONS AND ADDRESSES OF AUTHORS

**DEPARTMENT OF OTORHINOLARYNGOLOGY, UNIVERSITY COLLEGE HOSPITAL AND UNIVERSITY OF IBADAN, NIGERIA.*

***MOMAAK SPECIALIST HOSPITAL, AKURE, NIGERIA*

***MOMAAK SPECIALIST HOSPITAL, AKURE, NIGERIA*

****MOMAAK SPECIALIST HOSPITAL AND STATE SPECIALIST HOSPITAL, AKURE, NIGERIA*

CORRESPONDING AUTHOR

DR. FASUNLA, AYOTUNDE JAMES

DEPARTMENT OF OTORHINOLARYNGOLOGY, UNIVERSITY COLLEGE HOSPITAL AND UNIVERSITY OF IBADAN,

PMB 5116, IBADAN, OYO STATE, NIGERIA

Email address: ayofasunla@yahoo.com

Telephone number: +2348033740220

ABSTRACT

Foreign body in the nasopharynx is not a day-to-day experience in any Ear, Nose and Throat clinic as opposed to foreign bodies in the ear or nose. We present a case of food lodgment (piece of yam-dascorial) in the nasopharynx of a 2-year old male child. This was ignorantly dislodged into his nasopharynx by finger sweep procedure by the mother when the child choked during feeding.

INTRODUCTION

In children, foreign bodies in head and neck orifices are common in daily clinical practice but that in the nasopharynx is rare [1, 2]. Children do not report foreign body in the orifices to their parents or caregivers because of the fear of being punished. Foreign bodies in the laryngotracheobronchial airway are emergencies and usually present with choking spells and difficulty with breathing hence early presentation to the hospital [3]. Foreign body in the nasopharynx commonly follows insertion through the nasal cavity [4] and an escape of foreign body from the oral cavity/oropharynx into the nasopharynx is less common. These foreign bodies may be animate or inanimate, metallic or non metallic, organic or non-organic in nature. Some of the items commonly reported in the nasopharynx include the following: metal curtain rail hook, safety pin, coin, toys, bead, marble, stone, piece of wood, etc [5-9]. Nasopharyngeal foreign body may be undetected for weeks or years and the diagnosis may be missed when symptoms manifest except in high index of suspicion. This study presents a case of nasopharyngeal foreign body mimicking an obstructive adenoid and highlighted the delay in presentation, diagnostic

difficulty / miss diagnosis and importance of eliciting good history.

Case presentation

A two year old male child was referred to us from a neighbouring town with history of mucopurulent nasal discharge, mouth breathing and difficult breathing at night with associated snoring and apnea. The clinical condition became worse four nights which preceded presentation. There was a past history of choking while eating a meal of yam (a spice of dascoria) in the afternoon of the day when the symptoms started. This choking episode was observed by the mother who rescued him by sweeping a finger into his oropharynx to bring out the yam which provided the desired relieve. Although he used to snoring occasionally, but that night his snoring became louder and apneic episodes increased. He presented in the hospital because of the worsening clinical condition. No other ear, nose and throat symptoms.

Examination revealed an active child, mouth breathing, not dyspneic, acyanotic and not febrile (T=36.5^oC)

The examination of the ear revealed dull, hyperemic tympanic membrane but distraction test were positive bilaterally. There was bilateral foul smelling, mucopurulent nasal discharge and no air current demonstrable in both nasal cavities. No growth or foreign bodies observed on anterior rhinoscopy. The throat examination revealed essentially normal findings.

An assessment of obstructive adenitis to rule out nasal foreign bodies was made.

The plain radiograph of nasopharynx (Figure 1) was done which showed soft tissue shadow in the nasopharynx suggestive of obstructive adenoids. He was then scheduled for examination under anaesthesia of the nasopharynx and adenoidectomy. The operating finding was that of food substance (yam) in the nasopharynx. After removal, the nasopharyngeal mucosa was hyperemic and edematous. However, the adenoid tissue was small in size and not obstructing the posterior choanal hence was not removed. The anesthesia was reversed and was discharged same day on antibiotic and analgesics. He has been followed up till date and patient is clinically stable.

DISCUSSION

Although foreign body in nasopharynx is uncommon, food item (yam) in the nasopharynx has not been previously reported. To the best of our knowledge, this is the first case of yam presenting as a foreign body in the nasopharynx. The procedure of finger sweep of the pharynx to save a child from suffocating ended up impacting the foreign body in nasopharynx by retrograde root. When parents give history of relieving choking episode with finger sweep, the physician must bear in mind the possibility of the substance being dislodged and getting impacted in the nasopharynx.

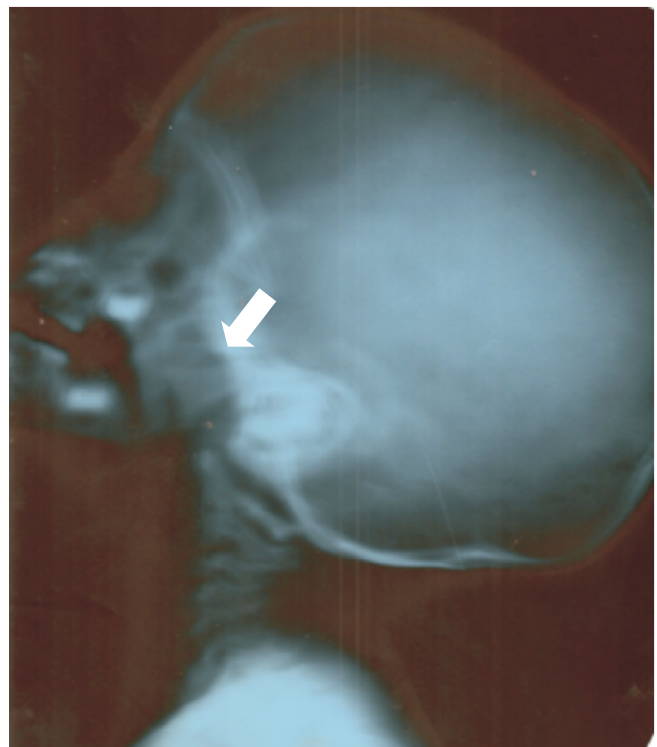
The history of witnessed ingestion of foreign body is usually helpful in the evaluation of children with foreign body ingestion/aspiration. It is equally important that the nasopharynx be examined and radiologically investigated for presence of foreign body even in the absence of symptoms and signs [10, 11]. Failure to identify and remove foreign body in the nasopharynx may result in complications such as otitis media, aspiration of the foreign body into the lower airway and even migration to distant site in the body [11]. This patient already developed dull, hyperemic tympanic membrane bilaterally which were early

signs of middle ear infection. Yam, being a biologic object elicited inflammatory reaction as evident by edematous, hyperemic nasopharyngeal mucosa that was seen in this patient. Early intervention and removal of the foreign body in this patient prevented this complication.

Metallic or opaque foreign bodies are readily identified on the plain radiograph of the nasopharynx whereas, non opaque material like the foreign body (pieces of yam) in this index patients are not readily seen. The sauce added to the yam to improve the taste might have made its shadow visible on the plain postnasal space x-ray. They can mimic soft tissue shadow of an enlarged obstructive adenoid thereby leading to miss diagnosis. Taking good history from patient's caregiver is therefore very important in the evaluation. The history of finger sweeping which brought the yam substance out might have beclouded the thought of the foreign body being in the nasopharynx. Examination under anaesthesia of the nasopharynx will aid the identification and removal of such a foreign body.

CONCLUSION: Foreign body in the nasopharynx can follow attempt to remove suffocating food substance from the oropharynx with finger sweep by anxious mother. People should be told about this danger and possibility of aspiration of the foreign body with resultant death.

Figure 1: Plain radiograph of the patient's nasopharynx showing soft tissue shadow which completely occluded the nasopharyngeal airway (arrowed) mimicking an obstructive adenoid.



CONFLICT OF INTEREST

The authors declare no conflict of interest

REFERENCES

1. Sunkum JKAG (2011) Nasopharyngeal foreign body in a young child. *Indian J Otolaryngol Head Neck Surg* 63:285-286.
2. Heim SW, Maughan KL (2007) Foreign bodies in the ear, nose, and throat. *Am Fam Physician* 76:1185-1189.
3. Ngo A, Ng KC, Sim TP (2005) Otorhinolaryngeal foreign bodies in children presenting to the emergency department. *Singapore Med J* 46:172-178.
4. Kiger JR, Brenkert TE, Losek JD (2008) Nasal foreign body removal in children. *Pediatr Emerg Care* 24:785-792.
5. Martins RH, Mano JB, da Silva EF (2006) Foreign body in nasopharynx: an accidental radiological finding. *Braz J Otorhinolaryngol* 72:431.
6. Dasgupta KS, Lanjewar KY, Joshi SV (2006) Safety pin The UNSAFE foreign body of air passage. *Indian J Otolaryngol Head Neck Surg* 58:387-388.
7. Dutta NN, Choudhury B (2005) An unusual foreign body in the nasopharynx. *Indian J Otolaryngol Head Neck Surg* 57:266-267.
8. Onakoya PA, Adoga AA, Adoga AS, Galadima C, Nwaorgu OG (2005) An unusual rhino-pharyngeal foreign body. *West Afr J Med* 24:89-91.
9. Hameed MK (2005) An unusual foreign body in nasopharynx. *J Coll Physicians Surg Pak* 15:178-179.
10. MacNeil SD, Moxham JP, Kozak FK (2010) Paediatric aerodigestive foreign bodies: remember the nasopharynx. *J Laryngol Otol* 124:1132-1135.
11. Kansara AH, Sheth KM, Ramesh DK (1999) Unusual foreign body in the nasopharynx and ethmoidal sinus. *Indian J Otolaryngol Head Neck Surg* 51(Suppl 1):7173.